

A Case of Intraneural Neurofibroma

Byoung-Dae Kim, M.D., You Chan Kim*, M.D., Seung Hun Lee, M.D.

Department of Dermatology, Yonsei University, College of Medicine, Seoul,

**Department of Dermatology, Ajou University School of Medicine, Suwon, Korea*

Histologically, neurofibroma can be classified into four variants: cutaneous extraneural variant, cutaneous or deep circumscribed intraneural variant, plexiform variant, and deep diffuse extraneural variant. Cutaneous extraneural type is the most common form, but deep circumscribed intraneural type is rarely found in the skin. We report a case of intraneural neurofibroma found on the right buttock of a 48-year-old Korean woman. She visited our department with complaint of a subcutaneous mass on her right buttock, of which she had been aware for two months. Excisional biopsy of the lesion revealed an encapsulated subcutaneous nodule showing histological features of neurofibroma.
(*Ann Dermatol* 16(4) 169~172, 2004)

Key Words: Intraneural neurofibroma

INTRODUCTION

Neurofibroma occurs as a sporadic tumor or hereditary lesions associated with neurofibromatosis^{1,2}. Histologically, it was classified into four variants: cutaneous extraneural variant, cutaneous or deep circumscribed intraneural variant, plexiform variant, and deep diffuse extraneural variant³. Deep circumscribed intraneural variant is so rare that it is not well known. Only four cases have been reported in the literature so far⁴⁻⁶. We report a case of intraneural neurofibroma occurring as a subcutaneous nodule on the buttock.

CASE REPORT

A 48-year-old Korean woman presented to our hospital with a 2-month history of an asymptomatic subcutaneous nodule situated on the right buttock.

She had no other significant medical history or notable family history. A physical examination revealed a slightly raised, flesh-colored, subcutaneous nodule that was freely movable and measured 30 × 15 mm (Fig. 1A). Under the diagnosis of lipoma, an excisional biopsy was carried out. During the biopsy, we observed a well capsulated, yellow to red-colored ellipsoidal mass (Fig. 1B). A histopathologic examination revealed a well-capsulated tumor located in the subcutaneous tissue (Fig. 2). It was composed of three components: cells, collagen, and mucin. The cells were spindle shaped, had indistinct borders, eosinophilic cytoplasm, and oval or twisted basophilic nuclei. They were uniformly scattered in a small to moderate amount of mucin and closely associated with wirelike collagen fibers (Fig. 3A). The hypocellular zone was composed of haphazardly scattered slender spindle cells, embedded in a mucin-rich matrix containing delicate collagen fibers (Fig. 3B). An immunohistochemical examination showed the tumor cells were positive for S-100 protein (Fig. 3C).

DISCUSSION

Neurofibromas may occur as a solitary tumor or as multiple lesions in a segmental or widespread distribution, referred to as neurofibromatosis. The histopathology of the neurofibromas in these

Received June 3, 2004

Accepted for publication July 29, 2004

Reprint request to: Seung Hun Lee, M.D., Department of Dermatology, Yonsei University College of Medicine, Yongdong Severance Hospital, 146-92 Dogok-dong, Kangnam-gu, Seoul 135-720, Korea.

Tel. 82-2-3497-3360, Fax: 82-2-3463-6136

E-mail. ydshderm@yumc.yonsei.ac.kr

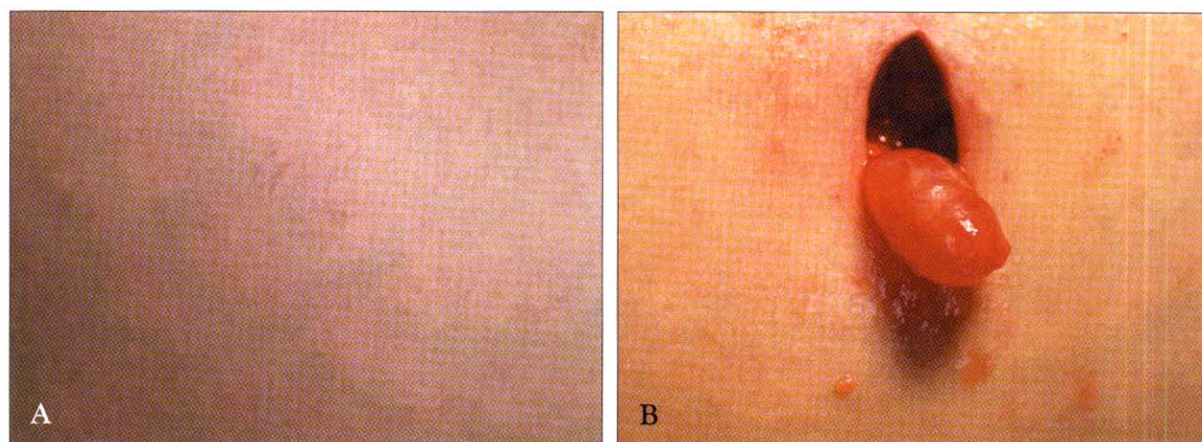


Fig. 1. (A) A slightly raised, flesh-colored, freely movable, 30 × 15 mm, subcutaneous nodular lesion on the right buttock. (B). During the excisional biopsy, a well capsulated, yellow to red-colored mass was observed.

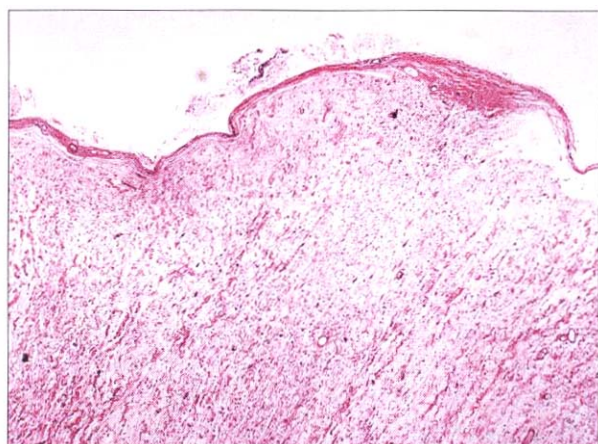


Fig. 2. A well capsulated tumor located in subcutaneous fat (H&E, × 40).

different clinical settings is similar and will be considered together. Neurofibromatosis is a clinically heterogeneous disorder with various manifestations affecting skin, soft tissues, blood vessels, and the peripheral and central nervous systems¹. Solitary neurofibromas are papular, nodular or pedunculated tumors with predilection for the upper trunk. They are soft and tend to invaginate on pressure (the 'buttonhole' sign)². As a contrast to the superficial solitary neurofibroma, intraneural neurofibroma, in our case, is a deep-seated subcutaneous tumor because it grows intraneurally within peripheral nerves, causing fusiform enlargement of the affected nerve.

The histologic spectrum of neurofibromas is broad³. Cutaneous extraneural variants, cutaneous or deep circumscribed intraneural variants, plexiform variants, deep diffuse extraneural variants, and various combinations of the above are manifested in an array of histologic patterns. Extraneural sporadic cutaneous neurofibroma (ESCN)s are the common sporadic neurofibromas. Some sporadic cutaneous neurofibromas, including subcutaneous variants, differ in patterns from ESCN. Confined by the perineurium of the nerve of origin, they are circumscribed and intraneural. Their internal patterns are indistinguishable from the patterns variously manifested in the intraneural components of plexiform neurofibromas. Intraneural neurofibroma in skin, as in our case, is rare. To our knowledge, only four cases have been previously described in the literature^{4,6}. Lallemand *et al*⁵ reported two cases involving the posterior interosseous nerve. But these cases may be perineurioma. Differential diagnoses of neurofibromas include neuroma and schwannoma, and it is easily made by the absence of a fibrous capsule of neurofibroma. However, one should pay attention to the rare type of neurofibroma, intraneural and plexiform type, showing encapsulation of the tumor.

In histogenesis, cutaneous extraneural variants originate from unmyelinated nerve ending or myelinated nerve composed of thin perineurium⁷. Then, they grow and destroy the nerve and perineurium. On the other hand, intraneural variants originate from large myelinated peripheral nerve^{8,9}. They replace the nerve but are confined within the

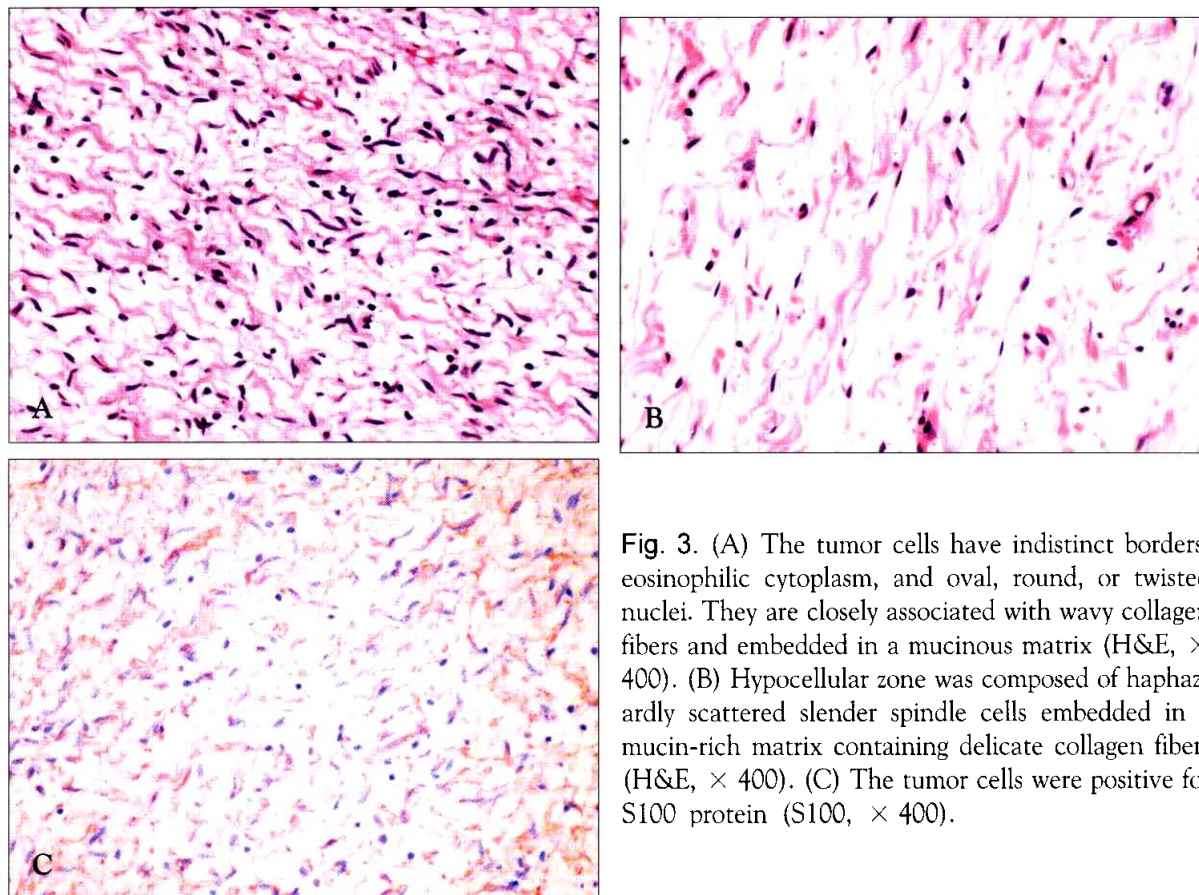


Fig. 3. (A) The tumor cells have indistinct borders, eosinophilic cytoplasm, and oval, round, or twisted nuclei. They are closely associated with wavy collagen fibers and embedded in a mucinous matrix (H&E, $\times 400$). (B) Hypocellular zone was composed of haphazardly scattered slender spindle cells embedded in a mucin-rich matrix containing delicate collagen fibers (H&E, $\times 400$). (C) The tumor cells were positive for S100 protein (S100, $\times 400$).

perineurium of the nerve of origin.

In a recent review of the histopathological variants of neurofibroma, Megahed¹⁰ listed 10 variants: classical, cellular, myxoid, hyalinized, epithelioid, plexiform, diffuse, pigmented, granular cell and paccinian. Cellular, myxoid, and hyalinized variants represent no distinct pathological entities but instead are subtypes of classical neurofibromas. They did not include the deep circumscribed intraneural type in their classification. Except for plexiform neurofibroma, which is pathognomic for NF-1, other histologic variants may occur sporadically or in association with neurofibromatosis. In our case, we observed not only classical but also myxoid histological features according to his classification.

We herein report a case of encapsulated intraneural neurofibroma. Dermatologists should be aware of this rare histologic type of neurofibroma showing encapsulation of the tumor.

REFERENCES

1. Pivnick EK, Riccardi VM: The neurofibromatosis. In Freedberg IM, Eisen AZ, Wolff K, Austen KF, Goldsmith LA, Katz SI (ed): *Dermatology in General Medicine*. McGraw-Hill, New York, 2003, pp 1825-1833.
2. Albrecht S: Neoplasias and hyperplasias of neural and muscular origin. In Freedberg IM, Eisen AZ, Wolff K, Austen KF, Goldsmith LA, Katz SI (ed): *Dermatology in General Medicine*. McGraw-Hill, New York, 2003, pp1032-1041.
3. Reed RJ, Argenyi Z: Tumors of neural tissue. In Elder D, Elenitsas R, Jaworsky C, Johnson B Jr (ed): *Histopathology of the Skin*. Lippincott-Raven, Philadelphia, 1997, pp977-1009.
4. Galinski AW, Brewster DC: Encapsulated neurofibromatosis of the foot: A case report. *J Am Pediatr Assoc* 1980;70:370-371.
5. Lallemand RC, Weller RO: Intraneural neurofibroma involving the posterior interosseous nerve.

- J Neurol Neurosurg Psychiatry 1973;36:991-996.
6. Lee HJ, Koh BK, Kim JW: A Case of Intraneural Neurofibroma in Neurofibromatosis. Kor J Dermatol 2000;38:530-532.
7. Argenyi ZB: Neural tumors. In Arndt KA, Leboit PE, Robinson JK, Wintroub BUI (ed): Cutaneous Medicine and Surgery. W.B. Saunders, Philadelphia, 1996, pp1536-1551.
8. Koo JYM: Neurocutaneous disorders. In Sams WM. Jr, Lynch PJ (ed): Principles and Practice of Dermatology. Churchill Livingstone, New York, 1990, pp867-874.
9. Woodruff JM: Pathology of tumors of the peripheral nerve sheath in type 1 neurofibromatosis. Am J Med Genet 1999;89:23-30.
10. Megahed M: Histopathological variants of neurofibroma: A study of 114 lesions. Am J Dermatopathol 1994;16:486-495.