

Nevus Lipomatosus Superficialis on the Dorsal Foot

Gu Chang Lee, M.D., Yoonoo Noh, M.D., Mi Kyeong Kim, M.D.*, Youn Soo Kim, M.D.,
Tae Young Yoon, M.D.

Department of Dermatology and Internal Medicine, College of Medicine & Medical Research
Institute, Chungbuk National University, Cheongju, Korea*

Nevus lipomatosus superficialis is a fairly uncommon disease characterized by ectopic fat tissue in the dermis. Lesions most commonly occur on the lower trunk, especially on the back, buttocks or abdomen. Rarely, lesions also occur on the knee, axilla, arm, ear and scalp. To our knowledge this is the first case of nevus lipomatosus superficialis developing on the dorsal foot. (*Ann Dermatol* 15(1) 39~41, 2003).

Key Words : Nevus lipomatosus superficialis, Foot

Nevus lipomatosus superficialis is an uncommon form of connective tissue nevus and is manifest principally by the deposition of fatty tissue in the dermis¹⁻³. It may be present at birth or in infancy, appearing as single or multiple skin-colored or yellowish papules and sometimes coalescing into plaques with a cerebriform surface. In this disease, two clinical types are distinguished²⁻⁴: the classical type consisting of grouped papules and nodules, which are distributed linearly over the buttocks or upper thighs, and the solitary type, usually seen in adults, shows predilection for the same sites, but may develop on the knee, axilla, arm, ear and scalp. The solitary type is much rarer than the classical type. We report the first case of nevus lipomatosus superficialis of solitary type developing on the dorsal foot.

CASE REPORT

A 1-year-old infant presented with two asymptomatic

nodules on the medial and lateral surface of the right dorsal foot. These lesions had been present for five months and had gradually increased in size. His general condition had been good. Physical examination revealed two skin colored, smooth, non-tender nodules slightly elevated from the surrounding healthy skin. The sizes of the skin lesions are 1.5 × 1.5cm and 2.0 × 2.0cm each. The lesions showed no pigmentary abnormality and ill-defined margin, and were soft without fluctuation on palpation (Fig. 1).

On histological examination, mature fat cells were found embedded among the collagen bundles in the reticular dermis. These fat cells are also located particularly around small blood vessels. Collagen bundles were arranged irregularly. The individual fat cells were mature and normal size. However, no nevus cell growth, nor any other tumor cells were seen (Fig. 2). The epidermis was normal.

Excision was planned in childhood, because no malignant transformations have been reported and our patient had no symptoms.

DISCUSSION

Nevus lipomatosus superficialis was first reported by Hoffman and Zurhelle in 1921¹. Since then, this condition has been reported only rarely in the literature²⁻⁴. This lesion is recognized as a nevoid anomaly characterized by ectopic adipose tissue in

Received July 3, 2002

Accepted for publication November 28, 2002

Reprint request to : Tae Young Yoon, M.D., Department of Dermatology, College of Medicine & Medical Research Institute, Chungbuk National University, 62 Gaesin-dong, Heungdeok-gu, Cheongju, Chungbuk, 361-711, Korea

Tel. 82-43-269-6369, Fax: 82-43-266-1698

E-mail. tyoon@med.chungbuk.ac.kr

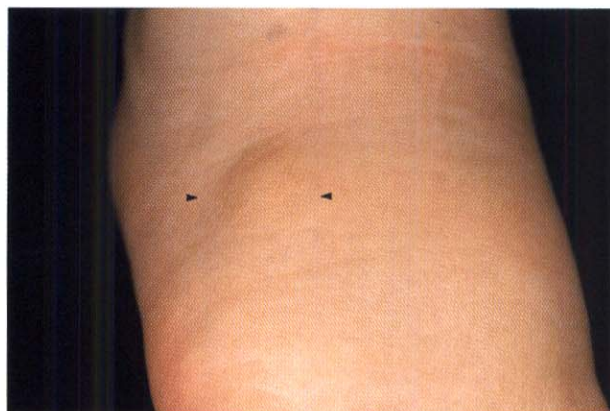


Fig. 1. A skin-colored nodule on the lateral aspect of the right dorsal foot.

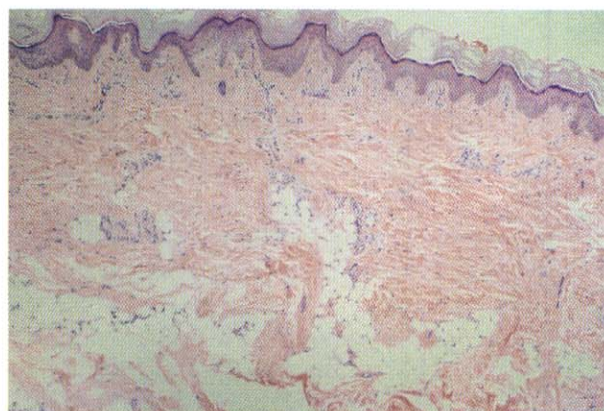


Fig. 2. Lobules of fat cells are scattered among the collagen bundles throughout the dermis (H&E, ×40).

Table 1. Number of cases in the Korean literature depending on the site

Site	Number of cases
Lower back	5
Buttock	8
Coccyx	3
Upper thigh	3
Forehead	1
Shoulder	1

Tow cases involved 2 or 3 sites

the dermis². The proportion of fatty tissue varies greatly from more than 50% to less than 10% of the dermis³. Sometimes, the boundary between the dermis and the hypoderm is ill-defined or lost because of the irregularly distributed fat cells^{3,4}. Usually this condition starts at birth and increases in size in proportion to development. Today, two clinical types are distinguished: the classical type and the solitary type^{2,4}. First, the classical type reported by Hoffman and Zurhelle consists of multiple skin-colored or yellowish sessile lesions. These tend to coalesce into plaques with a cerebriform aspect and zonal distribution⁵. Lesions usually occur on the pelvic girdle, buttocks, and sometimes on the sacral and lumbar regions or abdominal wall⁶. Lesions usually do not cross the midline and follow the natural cleavage lines of the skin. The second type of nevus lipomatosus superficialis consists of a small solitary nodular lesion; this is difficult to distinguish from a skin tag with fatty herniation. Le-

sions occur in different areas from the ones in the classical type: arms, knees, axillae, ears, and scalp³. The lesions appear in adult life with slow growth⁵.

Differential diagnosis of nevus lipomatosus superficialis includes several other entities: neurofibromatosis, focal dermal hypoplasia, connective tissue nevus, lipoma, epidermal nevus, juvenile elastoma, and lipoblastomatosis; however, a diagnosis of nevus lipomatosus superficialis can be established easily by the presence of mature lipocytes and absence of lipoblasts in the dermis^{5,6}.

As for treatment of this disease, excision of the lesion is advisable^{3,4}. Because the classical type shows linear distribution limited to around the buttocks, and the solitary type is at most a few centimeters in diameter in many instances, excision of these tumors may be performed easily⁴. In the solitary tumor with a larger lesion, however, the lesion is sometimes too large to be excised all at once. In such a case, especially with a conspicuous lesion, excision and covering with a flap or serial excision is preferable⁷.

In Korea, 18 cases have been reported⁸⁻¹⁸ (Table 1). However, nevus lipomatosus superficialis developing on the dorsal foot has not been reported in the English and Korean literature. Herein, we report the first case of nevus lipomatosus superficialis developing on the dorsal foot.

REFERENCES

1. Mehregan, A. H., Tarafogli, V. & Ghandchi, A: Nevus lipomatosus cutaneous superficialis (Hoff-

- man-Zurhelle). *J Cutan Pathol* 2:307-313, 1975.
2. Weitzner S: Solitary nevus lipomatosus cutaneous of the scalp. *Arch Dermatol* 97:540-542, 1968.
3. Wilson-Jones EW, Marks R, Pongsehirun D: Nevus superficialis lipomatosus. A clinicopathological report of twenty cases. *Br J Dermatol* 93:121-133, 1975.
4. Hirano K, Masumizu T, Morishima T: Nevus lipomatosus cutaneous superficialis. *Rinsho Hifuka* 24:569, 1970.
5. Regaya SM, Khattech A, Regaya MA, Ammar A: Le naevus lipomateux cutane superficiel D'Hoffman et Zurhelle-A propos d'une observation. *Arch Anat Cytol Path* 39:233-235, 1991.
6. Abel R, Dougherty JW: Nevus lipomatosus cutaneous superficialis (Hoffman-Zurhelle)-Report of two cases. *Arch Dermatol* 85:524, 1962.
7. Sawada Y: Solitary nevus lipomatosus superficialis on the forehead. *Ann Plast Surg* 16(4):356-358, 1986.
8. Chang SN, Yoon KH, Kim DK, Lee HE. Pedunculated lipofibroma: The solitary form of nevus lipomatosus superficialis. *Ann Dermatol* 8:237-239, 1996.
9. Shim DT, Kim YK, Lee JS, Ko MK: Three cases of nevus lipomatosus cutaneous superficialis. *Kor J Dermatol* 32(4):691-697, 1994.
10. Lim CU, Lee YS: Nevus lipomatosus cutaneous superficialis-Report of a case. *Kor J Dermatol* 19:927-931, 1981.
11. Chung TA, Ha AS: Nevus lipomatosus cutaneous superficialis-Report of a case. *Kor J Dermatol* 16:103-107, 1978.
12. Lim HS, Kim YC, Kim SC: Solitary nevus lipomatosus cutaneous superficialis on the forehead presenting as a soft edematous plaque. *Kor J Dermatol* 39:1318-1320, 2001.
13. Kwon KS, Seo KH, Jang HS, Chung TA: A Clinicopathological Study of the Pedunculated Lipofibromas - A comparison with Nevus Lipomatosus Cutaneous Superficialis. *Kor J Dermatol* 35:854-862, 1997.
14. Park SY, Haw CR, Kim SN, Kim BJ, Yoo TY: A case of nevus lipomatosus cutaneous superficialis. *Kor J Dermatol* 15:353-358, 1977.
15. Chae SM, Kim JK, Park JK, Kim MY: A Case of Nevus Lipomatosus Cutaneous Superficialis. *Kor J Dermatol* 16:513-518, 1978.
16. Oh SH, Chun IK, Kim YP: Nevus Lipomatosus Cutaneous Superficialis - Report of a case. *Kor J Dermatol* 22:668-672, 1984.
17. Bae YJ, Hong JN, Haw CR, Youn JI, Lim SD: Nevus Lipomatosus Cutaneous Superficialis - Report of two cases. *Kor J Dermatol* 20:563-567, 1982.
18. Bang DS, Koh CJ, Lee SN, Choi BM, Lee JB: Nevus Lipomatosus Cutaneous Superficialis (Hoffmann - Zurhelle) Report of Two cases. *Kor J Dermatol* 19:359-364, 1981.