

# A Case of Xanthoma Disseminatum Treated with CO<sub>2</sub> Laser Vaporization and High Dose Steroid

Jeong Deuk Lee M.D., Chung Eui You M.D., Sang Hyun Cho, M.D.

*Department of Dermatology, Our Lady of Mercy Hospital, College of Medicine, The Catholic University of Korea, Seoul*

Xanthoma disseminatum (XD) is one of cutaneous nonhistiocytosis X, and characterized by multiple, widely distributed red, brown, yellowish papules and nodules that tend to coalesce. We present a case of XD with characteristic clinical findings and treated with the combination therapy of CO<sub>2</sub> laser vaporization and high dose steroid.  
(*Ann Dermatol* 15(3) 110~112, 2003).

*Key Words* : Xanthoma disseminatum, CO<sub>2</sub> laser, Steroid

Xanthoma disseminatum (XD) or Montgomery's syndrome is a rare disorder that is a distinct subset of cutaneous nonhistiocytosis X<sup>1</sup>. It is characterized by multiple, widely distributed red, brown, yellowish papules and nodules that tend to coalesce. Mucous membrane involvement such as oral cavity, upper airway and the corneal and conjunctival involvement have been reported<sup>2,3</sup>. It is often associated with diabetes insipidus in one third to one half of patients<sup>4,5</sup>. We present a case of XD with characteristic clinical finding and no mucosal involvement.

## CASE REPORT

A 27-year-old man presented with multiple brown smooth-topped papules and nodules on the face, especially perioral and periorbital areas (Fig. 1). The lesions first appeared 1 year ago and gradually increased in size and number. There were some scattered brown papules on his neck, axillae, trunk and upper extremities. The patient was in good health and physical examination disclosed no ab-

normalities. The patient complained of no systemic symptoms except disfiguring appearance. Serum lipids, lipoproteins, and apolipoproteins were all within normal limit. He had no family history of similar cutaneous disorder or a systemic lipid disturbance. Histopathological examination revealed the diffuse proliferations of foamy histiocytes with giant cells and inflammatory cells within the dermis (Fig. 2,3). The patient was treated with CO<sub>2</sub> laser and a daily divided dose of prednisone. Under local anesthesia using EMLA cream, CO<sub>2</sub> laser vaporization of unsightly lesions on the face was performed. The patient was given a daily divided dose of prednisone, 60mg for 6 weeks. The lesions on the face reduced in size and prominence (Fig. 4).

## DISCUSSION

Xanthoma disseminatum (XD) or Montgomery's syndrome is a rare normolipemic mucocutaneous xanthomatosis belonging to the group of nonhistiocytosis X<sup>1</sup>. This disorder was first described in 1938 by Montgomery and Osterberg and thought to be a primary reactive, histiocytic proliferation with secondary lipid accumulation<sup>6</sup>. It is characterized by multiple, widely distributed red, brown, yellowish papules and nodules that tend to coalesce, especially in flexural and intertriginous areas<sup>1,2</sup>. Mucous membrane involvement such as oral cavity, upper airway, stomach and the corneal and con-

Received October 25, 2002

Accepted for publication April 15, 2003

**Reprint request to** : Sang Hyun Cho M.D., Department of Dermatology, Our Lady of Mercy Hospital, College of Medicine, The Catholic University of Korea, 665, Pupyongdong, Pupyonggu, Inchon, 403-720, Korea  
Tel. 82-32-510-5528, Fax: 82-32-510-5827  
E-mail. drchosh@hotmail.com

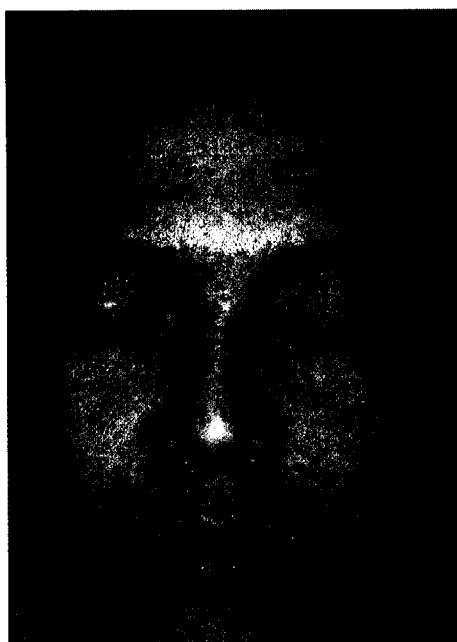


Fig. 1. Multiple brown smooth-topped papules and nodules on the face, especially perioral and periorbital areas in a 27-year-old man.

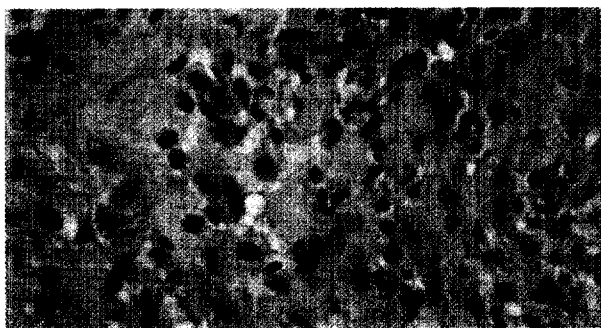


Fig. 3. Foamy histiocytes with giant cells and inflammatory cells within the dermis (hematoxylin-eosin stain  $\times 400$ ).

junctival involvement have been reported<sup>2,3</sup>. XD is generally benign, but associated with diabetes insipidus in about one third to one half of patients<sup>4,5</sup>. Perianal lesion may interfere defecation<sup>2,7</sup>. Ocular lesion may cause obstructive blindness, and bronchial lesion respiratory difficulty<sup>1,3,7</sup>.

Caputo et al., proposed three clinical variants of XD according to their evolution and prognosis<sup>8</sup>: (1) the extremely rare self-healing form wherein lesions undergo spontaneous resolution, (2) the more common persistent form wherein mucocuta-




Fig. 2. Multiple foamy histiocytes and inflammatory cells within the dermis (hematoxylin-eosin stain  $\times 200$ ).

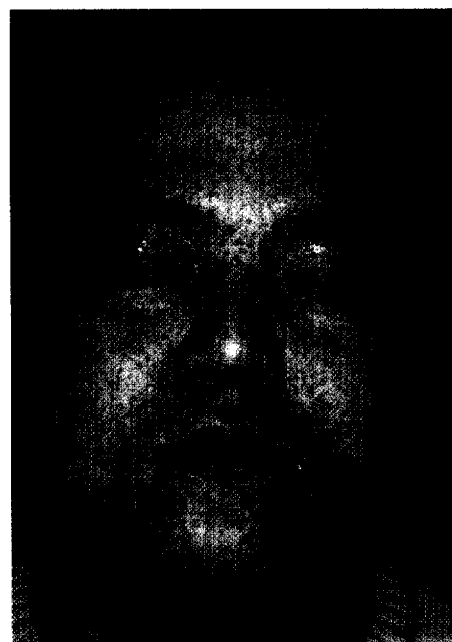


Fig. 4. The same patient after CO<sub>2</sub> laser vaporization of facial lesions.

neous lesions persist indefinitely, and (3) the extremely rare progressive form wherein there is systemic involvement, including organ dysfunction or central nervous system involvement. Our patient presented characteristic clinical finding of multiple brown smooth-topped papules and nodules on the face and flexural area but no mucosal visceral involvement. The patient complained of no systemic symptoms except disfiguring appearance.

Therapy for XD has largely been empirical and unsuccessful. Clofibrate, prednisone, radiotherapy,

chemotherapy, dermabrasion, intralesional steroid injection, liquid nitrogen therapy, and CO<sub>2</sub> laser vaporization have been used<sup>1,8-11</sup>. Responses to these different therapeutic modalities have been variable.

We treated our patient with CO<sub>2</sub> laser. But, the lesions recurred after about 2 months. So we retreated the patient with CO<sub>2</sub> laser and high dose prednisone. Treatment in this patient has resulted in great cosmetic improvement. The lesions on the face reduced in size and prominence and the patient was pleased with the result. We thought it worthwhile to present this case because the combination therapy of CO<sub>2</sub> laser vaporization and high dose steroid gives good result in persistent form of XD. Because corticosteroid have been shown to inhibit granuloma formation, prednisone may have a role in controlling disfiguring forms of XD<sup>10</sup>. The treatment of XD covered hereinabove is not only the first attempt at treating XD, in Korea, but gives good results as well.

## REFERENCES

1. Caputo R. Cutaneous nonhistiocytosis X. in Freedberg IM, Eisen AZ, Wolff K, Freedberg IM, Goldsmith LA, *et al.* Dermatology in general medicine. 5<sup>th</sup> ed. New York: McGraw-Hill; 1999 p.1892-902
2. Kalz F, Hoffman MM, Lafance A. Xanthoma disseminatum; clinical and laboratory observations over a ten year period. *Dermatologica* 1970;140:129-41
3. Liebman SD, Crocker AC, Geiser CF. Corneal xanthomas in childhood. *Arch Ophthalmol* 1966;13:1-30
4. Gianotti F, Caputo R. Histiocytic syndrome: a review. *J Am Acad Dermatol* 1985;13:383-404
5. Ringel E, Moschella S. Primary histiocytic dermatoses. *Arch Dermatol* 1985;121:1531-41
6. Montgomery H, Osterberg AE. Xanthomatosis: correlation of clinical histopathologic, and chemical studies of cutaneous xanthoma. *Arch Dermatol Syphilol* 1938;37:373-402
7. Altman J, Winkelmann RK. Xanthoma disseminatum. *Arch Dermatol* 1962;86:582-96
8. Caputo R, Veraldi S, Grimalt R, *et al.* The various clinical patterns of xanthoma disseminatum. *Dermatology* 1965;190:19-24
9. Carpo BG, Grevelink SV, Brady S, Gellis S, Grevelink JM. Treatment of cutaneous lesions of xanthoma disseminatum with a CO<sub>2</sub> laser. *Dermatologic surgery* 1999;23:751-4
10. Bataglini J, Olsen TG. Disseminated xanthosiderohistiocytosis, a variant of xanthoma disseminatum, in a patient with a plasma cell dyscrasia. *J Am Acad Dermatol* 1984;11:750-5
11. Parker F. Xanthoma and hyperlipidemia. *J Am Acad Dermatol* 1985;13:1-30