

Hypopigmentary Disorders Excluding Vitiligo: Clinical Features in 301 Patients

UC Yeo, M.D.¹, KC Park, M.D.², MG Song, M.D.¹, JH Yoo, M.D.¹, BS Kim, M.D.³, WS Koh, M.D.³, BS Kim, M.D.⁴, JH Choi, M.D.⁵, DK Chun, M.D.⁶ and H-J Yu, M.D.⁷

Department of Dermatology, Sungkyunkwan University School of Medicine, Seoul, Korea¹

Department of Dermatology, Seoul National University College of Medicine, Seoul, Korea²

Department of Dermatology, SangKye Paik Hospital, Inje University, Seoul, Korea³

Department of Dermatology, Inha General Hospital,

College of Medicine, Inha University, Sunghnam, Kyunggido, Korea⁴

Department of Dermatology, Asan Medical Center, College of Medicine, University of Ulsan, Seoul, Korea⁵

Department of Dermatology, Seoul Paik Hospital, Inje University, Seoul, Korea⁶

Department of Dermatology, Kuri Hospital, Hanyang University, Kuri, Kyunggido, Korea⁷

Background : Hypopigmentary diseases other than vitiligo are common. But, their relative prevalence was not studied so far.

Objective : Our purpose was to show clinical features of hypopigmentary diseases except vitiligo to help clinicians differentiate hypopigmentary diseases.

Methods : Each disease was diagnosed by the dermatologists on the basis of clinical features, Wood's lamp examination or histopathologic examination. Vitiligo was excluded by the same methods.

Results : In 301 patients, nevus depigmentosus was the most common, followed by pityriasis alba, pityriasis versicolor, postinflammatory hypopigmentation, idiopathic guttate hypomelanosis in descending order of frequency. Male preponderance was observed in other diseases except nevus depigmentosus. Nevus depigmentosus, postinflammatory hypopigmentation, pityriasis alba, and pityriasis versicolor were common in the 1st and 2nd decades. Idiopathic guttate hypomelanosis was observed mostly in the elderly. Most nevus depigmentosus had one lesion. Pityriasis alba and postinflammatory hypopigmentation most commonly had 2 to 5 lesions. In pityriasis versicolor and idiopathic guttate hypomelanosis, more than 20 lesions were most common. Trunk was the most common site in nevus depigmentosus and pityriasis versicolor, the face in pityriasis alba and extremities in idiopathic guttate hypomelanosis. Postinflammatory hypopigmentation had no predilection sites.

Conclusion : In this study, we showed differences in clinical features of several hypopigmentary disorders. (Ann Dermatol 14(1) 6-10, 2002).

Key Words : Nevus depigmentosus, Pityriasis alba, Pityriasis versicolor, Postinflammatory hypopigmentation, Idiopathic guttate hypomelanosis.

Received February 20, 2001.

Accepted for publication May 31, 2001.

Reprint request to : Hee-Joon Yu, M.D., Department of Dermatology, Kuri Hospital, Hanyang University, 249-1, Kyomoon-dong, Kuri, Kyunggido 471-701, Korea
Tel. 82-31-560-2280, Fax. 82-31-557-4872

There are many hypopigmentary diseases which have different pathogenesis. To put it briefly, there are two mechanisms of hypopigmentation. One is the absence or loss of melanocytes and the other is the defects in melanin formation. Vitiligo, piebaldism, hypopigmentary scleroderma, idiopathic guttate

hypomelanosis, etc. are the examples of the former. Many other diseases such as pityriasis versicolor are caused by the latter mechanism. Differentiation of vitiligo from other hypopigmentary diseases is very important because clinical course, treatment and prognosis are quite different according to the diagnosis. In this respect comparative clinical information on hypopigmentary diseases are necessary. There are many studies on vitiligo and other hypopigmentary diseases. But comparative studies on the many hypopigmentary diseases are rare. Therefore, we investigated clinical features of hypopigmentary diseases except vitiligo to help clinicians differentiate hypopigmentary diseases.

MATERIALS AND METHODS

Clinical survey was carried out on 301 patients with hypopigmentary diseases except vitiligo who visited the department of dermatology in the following center for about 1 year (1997.12.1-1998. 11.30) : Samsung Medical Center, Seoul National University Hospital, Asan Medical Center, Inha General Hospital, Hanyang University Kuri Hospital, Seoul Paik Foundation Hospital, Sangkye Paik Foundation Hospital, and Kangbuk Samsung Hospital. We included those patients whose chief complaints were hypopigmentation. We didn't include incidental findings of hypopigmentary lesions during physical examination. Each disease was diagnosed by the dermatologists on the basis of clinical features, Wood's lamp examination or histopathologic examination. Vitiligo was excluded by same methods. Data compiled were diagnosis, sex, age of onset, duration, number, shape and distribution of lesion. When the lesions had more than two shapes and distributions, they were counted separately. Data was classified according to the predetermined category.

RESULTS

Relative incidence

In 301 patients, nevus depigmentosus (N.depigmentosus) was the most com-

mon (104 cases), followed by pityriasis alba (P.alba, 68 cases), pityriasis versicolor (P.versicolor, 42 cases), postinflammatory hypopigmentation (PIH, 40 cases), idiopathic guttate

hypomelanosis (IGH, 24 cases) and others (23 cases) in descending order of frequency (Fig. 1). Hypomelanosis of Ito (6 cases), nevus anemicus (5 cases), chemical leukoderma (3 cases), piebaldism (1 case), dyschromatosis universalis (1 case), lichen sclerosus et atrophicus (1 case) and hypopigmentary scleroderma (1 case) were all included in the category of others. Diseases included in others were not commented in separate results because of paucity of cases.

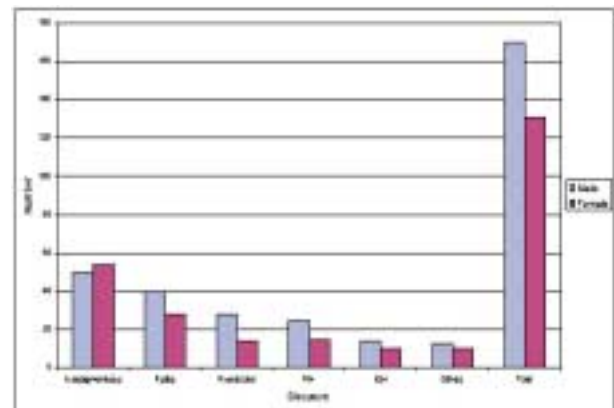


Fig. 1. Relative incidence and male to female ratio in hypopigmentary diseases.

Sex

Males and females were almost equally affected by nevus depigmentosus. However male preponderance was observed in other diseases (Fig. 1).

Age of onset

Hypopigmentary diseases were developed or detected most commonly below the age of 10 (192 cases, 64%). Between the ages of 10 to 20, hypopigmentary lesions were developed or detected in 42 cases (14%). In the other age groups, there were a few cases and there were no significant differences.

Below the age of 10, nevus depigmentosus was the most common disease, followed by pityriasis alba and postinflammatory hypopigmentation. Between the ages of 11 and

20, pityriasis versicolor, pityriasis alba, and postinflammatory hypopigmentation were common in descending order of frequency.

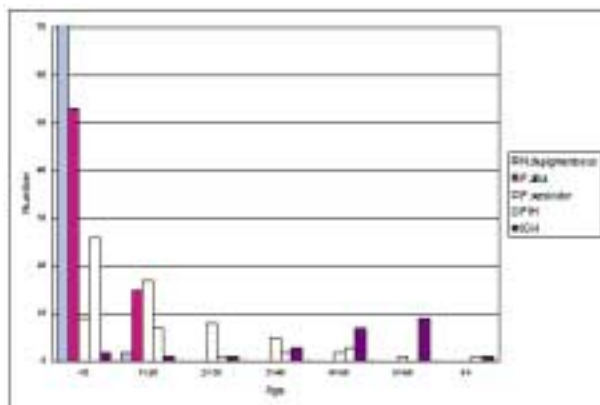


Fig. 2. Age of onset in hypopigmentary diseases.

Between the ages of 21 and 40, pityriasis versicolor was most common. After the age of 40, idiopathic guttate hypomelanosis was the predominant disease (Fig. 2).

Duration

Duration of hypopigmentary diseases before development or detection was variable in all diseases.

Number of lesion

When there was only one lesion, nevus depigmentosus was the most common disease and pityriasis alba and postinflammatory hypopigmentation were the 2nd and 3rd. When the patient had 2 to 5 lesions, pityriasis alba,

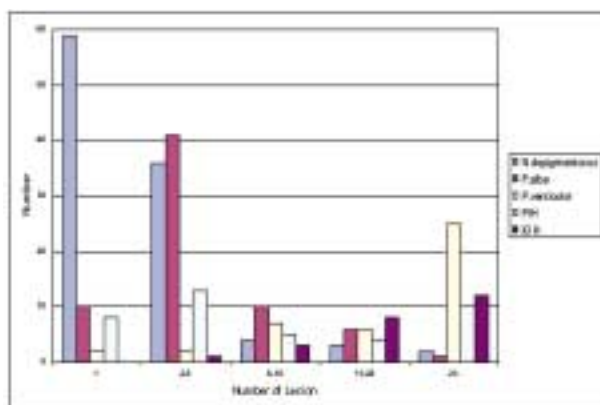


Fig. 3. Number of lesion in hypopigmentary diseases.

nevus depigmentosus, and postinflammatory hypopigmentation were common in descending order of frequency. There were no predominant diseases between the number of 6 to 20 lesions. More than 20 lesions were common presentations of pityriasis versicolor (Fig. 3).

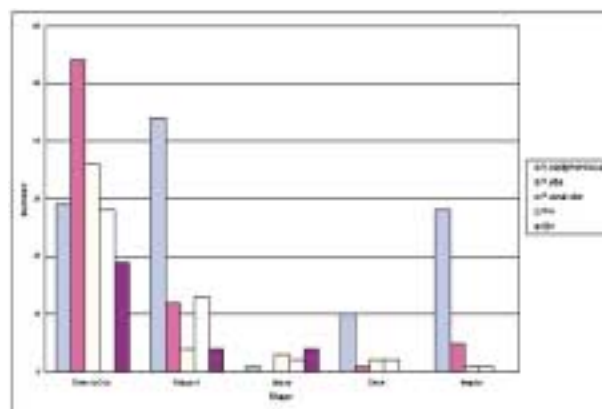


Fig. 4. Shape of lesion in hypopigmentary diseases.

Shape of lesion

Round to oval was most common form in all diseases except nevus depigmentosus. In nevus depigmentosus, polygonal (39%), round to oval (26%), and irregular shape (25%) was the common feature (Fig. 4).

Location of lesion

When the face was the site of involvement, pityriasis alba was the most common disease followed by nevus depigmentosus and pityriasis versicolor. Involvement of the trunk was the

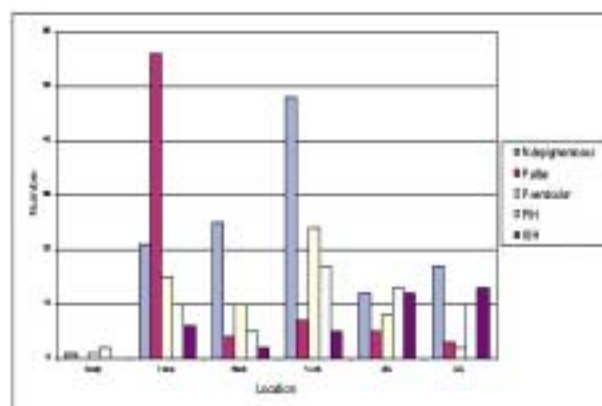


Fig. 5. Distribution of lesion in hypopigmentary diseases.

most common in nevus depigmentosus. Pityriasis versicolor and postinflammatory hypopigmentation were the 2nd and 3rd. Involvement of the extremities was common in nevus depigmentosus, idiopathic guttate hypomelanosis, and postinflammatory hypopigmentation (Fig. 5).

DISCUSSION

Our results showed that nevus depigmentosus, pityriasis alba, pityriasis versicolor, postinflammatory hypopigmentation, and idiopathic guttate hypomelanosis were common hypopigmentary diseases in differential diagnosis of vitiligo. Table 1 summarizes review of hypopigmentary diseases described in textbooks^{2,3}. Differences of this review and other previous reports from ours were described in the following. There were also a few patients having hypomelanosis of Ito, nevus anemicus, chemical leukoderma, piebaldism, dyschromatosis universalis, lichen sclerosus et atrophicus and

hypopigmentary scleroderma.

Male preponderance was observed in all common hypopigmentary diseases except nevus depigmentosus. Nevus depigmentosus seems to be equally affected in males and females^{1,2}. Pityriasis alba shows male preponderance in some studies, but in other studies males and females are equally affected^{1,2,4,5}. Pityriasis versicolor shows almost equal sex distribution⁶. However, Kim et al⁷ reported male preponderance in pityriasis versicolor and explained that the male preponderance originated from the difference of social activity and personal hygiene between sexes. No sexual difference is observed in idiopathic guttate hypomelanosis^{2,8}. There have been a few studies on the incidence in common hypopigmentary diseases. Therefore further studies are needed to clarify the sex distribution of common hypopigmentary diseases.

When the patient was in the 1st decade, nevus depigmentosus was the most probable diagnosis. It is present at birth, but may sometimes be discovered within the first few weeks

Table 1. Review of hypopigmentary diseases described in textbooks

Disease	Sex	Age	Number	Shape	Location	Note
N. depigmentosus	M = F	Congenital	1(usually) Quasiderm- -atomal	Round Lower abdomen Prox. L/E	Trunk	Unilateral distribution
P. alba	M = F	2 nd decade (most common)	2-3, usually 1-20, possible	Round to oval	Face (most common) Neck Shoulder U/E	
P.versicolor	Variable	All ages 3 rd and 4 th decade (most common)	Few to many	Round	Trunk(typical) Axilla Neck Scalp Face	
PIH	Variable	All ages	Variable	Round	Variable	Presence of primary lesions
IGH	M = F	>40, usually <20, occasionally	Few to many	Round	Extensor surfaces of the U/E & L/E No involvement of trunk & face	

or, particularly in fair-skinned individuals, a few months later¹. Pityriasis alba and postinflammatory hypopigmentation were the 2nd and 3rd most probable diagnosis. In the 2nd decade pityriasis versicolor, pityriasis alba, and postinflammatory hypopigmentation were common in descending order of frequency. Pityriasis versicolor was the most common disease in the 3rd and 4th decades. Over the 5th decade, idiopathic guttate hypomelanosis was most common. Idiopathic guttate hypomelanosis had been known to be a disease of adulthood and senescence^{1,2,7}, but two patients were under the age of 10 and the other two patients were in the 10's and 20's in our study. In the report by Whitehead et al⁹, 11% of 339 patients were in their teens and two patients were under the age of 10 in USA. This result is not significantly different from ours. Thus, even in young patients the possibility of idiopathic guttate hypomelanosis must be considered.

Duration of hypopigmentary diseases before visit was variable in all diseases. This result suggests that these diseases do not necessarily prompt the patients to visit the dermatologists. This may be due to cosmetic indifference in the patients included in our study.

When the patient had only one lesion, nevus depigmentosus was the most probable disease. Pityriasis alba was the next. When the patient had 2 to 5 lesions, pityriasis alba, nevus depigmentosus, and postinflammatory hypopigmentation were common. More than 20 lesions were common presentations of pityriasis versicolor, idiopathic guttate hypomelanosis, and postinflammatory hypopigmentation.

Round to oval shape was the most common presentation of hypopigmentary diseases except nevus depigmentosus. Polygonal, round to oval, or irregular shape was common in the case of nevus depigmentosus. In the study of Lee et al¹⁰, 79.6% of 49 patients had nevus depigmentosus of irregular shape. Lee et al insisted that irregular shape was a feature of nevus depigmentosus.

When the face was the only site of involvement, pityriasis alba was most common disease. When the face, neck, and trunk were involved simultaneously, nevus depigmentosus

and pityriasis versicolor were common. Involvement of extremities was common in nevus depigmentosus, idiopathic guttate hypomelanosis, and postinflammatory hypopigmentation.

We investigated the clinical features of hypopigmentary diseases except vitiligo. We attempted to compare the clinical features of common hypopigmentary diseases except vitiligo. Due to the paucity of previous reports, comparison of our results with others was difficult. However we expect further comparative studies on hypopigmentary diseases.

REFERENCES

1. Ortonne JP, Mosher DB, Fitzpatrick TB. Hypomelanotic disorders. In Vitiligo and other hypomelanosis of hair and skin, 1st ed. Plenum Publishing Co., New York, 1983, pp57-672.
2. Mosher DB, Fitzpatrick TB, Ortonne JP, Hori Y. Hypomelanoses and hypermelanoses. In Freedberg IM, Eisen AZ, Wolff K, et al (eds): Dermatology in general medicine. 5th ed. McGraw-Hill, New York, 1999, pp945-1017.
3. Odom RB, James WD, Berger TG. Disturbances of pigmentation. In Andrew's diseases of the skin. 9th ed. W.B. Saunders, 2000, pp1057-1072
4. Galan EB, Janniger CK. Pityriasis alba. *Cutis* 61:11-13, 1998.
5. Kim NY, Pandya AG. Pigmentary diseases. *Med Clin North Am* 82:1185-1207, 1998.
6. Sunenshine PJ, Schwartz RA, Janniger CK. Pityriasis versicolor: an update. *Pediatr Dermatol* 61:65-72, 1998.
7. Kim JH, Lee JT, Jeong EC. Clinical study and therapeutic experience in pityriasis versicolor. *Kor J Dermatol* 24:55-60, 1986.
8. Falabella R, Escobar C, Giraldo N, Rovetto P, Gil J, Barona MI, et al. On the pathogenesis of idiopathic guttate hypomelanosis. *J Am Acad Dermatol* 16:35-44, 1987.
9. Whitehead WJ, Moyer DG, Vander Ploeg DE. Idiopathic guttate hypomelanosis. *Arch Dermatol* 94:279-281, 1966.
10. Lee HS, Kim SM, Hann SK. Clinical features and histopathological characteristics of nevus depigmentosus. *Kor J Dermatol* 36:86-94, 1998.