

# Cutaneous B-Cell Pseudolymphoma: Report of Two Cases

Kyoung Jin Kim, M.D., Sung Eun Chang, M.D., Yong Hee Shim\*, M.D.,  
Jee Ho Choi, M.D., Kyung Jeh Sung, M.D., Kee Chan Moon, M.D.,  
Jai Kyoung Koh, M.D.

*Department of Dermatology and Pathology\*, Asan Medical Center, College of Medicine,  
University of Ulsan, Seoul, Korea*

Cutaneous pseudolymphoma (CPL) has a microscopic appearance that resembles that of cutaneous lymphoma, but shows a clinically benign course. The differential diagnosis of CPL with cutaneous lymphoma is very important because clinical outcomes of them are quite different. We herein describe two cases of B-cell pseudolymphoma, which were difficult to differentiate from cutaneous B-cell lymphoma. All of two cases, polymerase chain reaction of immunoglobulin heavy chain gene rearrangement showed polyclonal pattern.

(Ann Dermatol 14(2) 110-113, 2002).

---

**Key Words :** B-cell pseudolymphoma, Immunoglobulin gene rearrangement

Cutaneous pseudolymphoma (CPL) refers to heterogeneous group of benign reactive T or B cell lymphoproliferative disease of the skin. Cutaneous B cell pseudolymphoma (CBPL) shares many histopathologic and clinical features with cutaneous B cell lymphoma. Therefore, it is often impossible for the dermatologists to make a conclusive diagnosis of CBPL. Recently, Immunoglobulin gene rearrangement using polymerase chain reaction (PCR) or southern blot analysis is considered as a predictive indicator of malignant outcome.

We present two cases of CBPL which was initially diagnosed as cutaneous B cell lymphoma, but demonstrated polyclonality in the immunoglobulin heavy chain (IgH) gene rearrangement by PCR method.

## CASE REPORT

### Case 1.

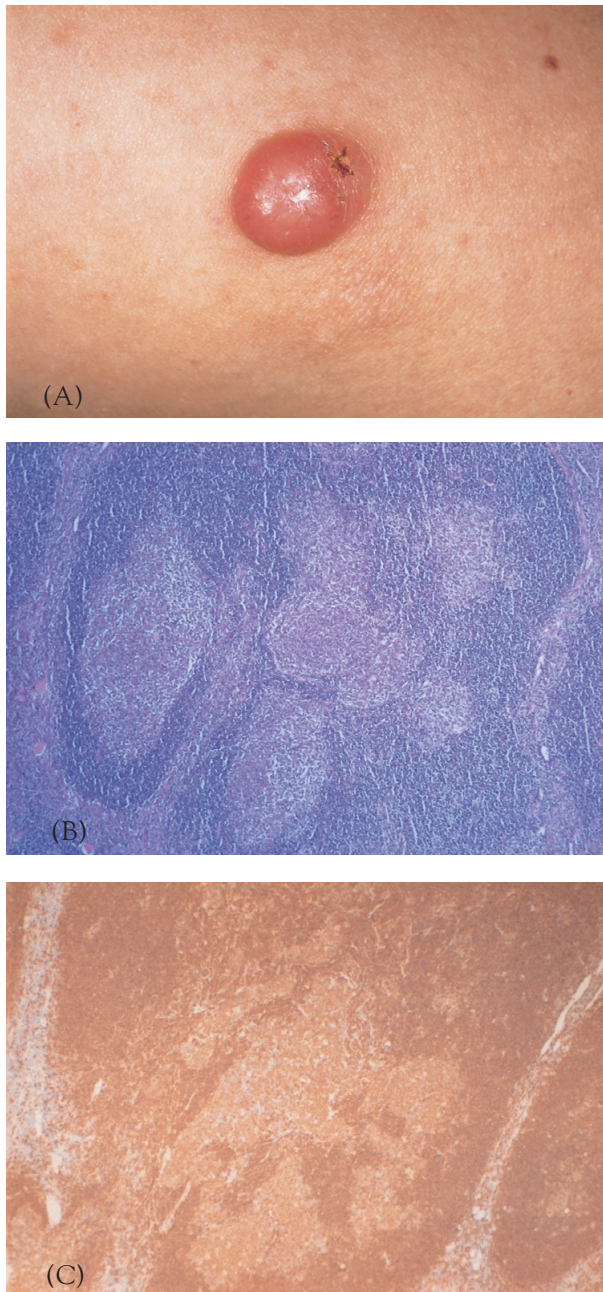
A 30-year-old healthy man presented with a solitary, erythematous nodule on his left upper arm without pruritus or tenderness. He had been stung by an insect approximately one year before, and the lesion gradually enlarged. There was no lymph node enlargement and he did not complain of fever or night sweat. The lesion had been diagnosed as cutaneous B cell lymphoma at another clinic. A physical examination revealed a solitary, well-demarcated,  $1.0 \times 1.0$  cm sized, round, dome-shaped, firm, erythematous nodule with partially ulcerated surface (Fig. 1A). An excisional biopsy specimen showed a dense nodular infiltrate of lymphocytes that formed a follicular germinal center resembling lymph nodes (Fig. 1B). The follicles were composed of peripheral small lymphocytes surrounding large pale-stained mononuclear cells. There were also histiocytes and a few plasma cells. These small and large lymphoid cells were positive for CD79a and CD20, but negative for CD3 (Fig. 1C). The kappa and lambda light chain stainings were polyclonal pattern and Bcl-2 was negative.

---

Received June 18, 2001.

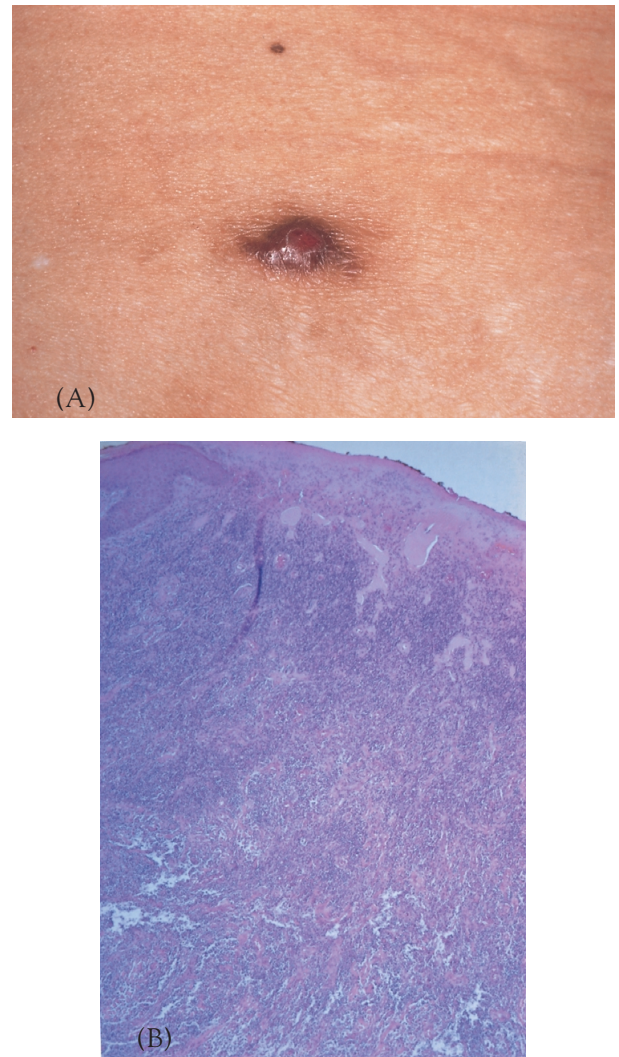
Accepted for publication October 23, 2001.

**Reprint request to :** Sung Eun Chang, M.D., Department of Dermatology, Asan Medical Center, College of Medicine, University of Ulsan Seoul, Korea  
Poongnap-dong, Songpa-gu Seoul, 138-736 Korea  
Tel. (02)3010-3460, Fax. (02)486-7831  
E-mail: [derm@amc.seoul.kr](mailto:derm@amc.seoul.kr)



**Fig. 1.** A) Solitary, dome shaped, erythematous nodule on the left upper arm (case 1). B) Dense nodular infiltrates of lymphocytes that formed a follicular germinal center (H&E,  $\times 40$ ). C) Positive staining with CD 79a ( $\times 40$ ).

The PCR of immunoglobulin heavy chain (IgH) gene rearrangement showed polyclonality. The diagnosis of B-cell pseudolymphoma was made. After complete excision of the whole lesion, there has been no recurrence during the follow-up period of 12



**Fig. 2.** A) Ovoid and dome shaped, brownish to erythematous nodule on the abdomen (case 2). B) Diffuse heavy and polymorphous cell infiltration with some lymphoid follicles (H&E,  $\times 40$ ).

months.

### Case 2.

A 63-year-old woman presented with an erythematous nodule on the abdomen. Seven months ago, multiple pruritic erythematous papules developed on the abdomen after contact with poison ivy, and the lesions almost disappeared after treatment with oral antihistamine and topical steroid. However, one papule had remained persistently and had increased in size gradually for the following one month without tenderness or other symptoms. She was diagnosed as having a cutaneous B cell



lymphoma by other dermatologists before a visit to us. Skin examination showed a solitary, well-defined,  $1.0 \times 1.2$  cm sized, ovoid, brownish to erythematous, dome-shaped nodule (Fig. 2A). A biopsy specimen demonstrated diffuse, heavy, and polymorphous infiltration composed of lymphoid cells with lymphoid follicles, histiocytes, eosinophils, and plasma cells (Fig. 2B). Most lymphoid cells were positive for CD79a but negative for CD3 and Bcl-2. The kappa and lambda light chain stainings showed polyclonality. The PCR of IgH gene rearrangement demonstrated no clonality. The nodule completely disappeared after total excision without recurrence during the follow-up period of 18 months.

## DISCUSSION

Cutaneous B cell pseudolymphoma (CBPL) is also known by the name of lymphocytoma cutis or cutaneous lymphoid hyperplasia. CBPL is characterized by a dense lymphoid infiltrate, that is usually B cell rich and may resemble B-cell lymphoma clinically and histopathologically<sup>1</sup>. CBPL presents most commonly as a solitary nodule but can also appear as multiple papules or nodules, plaques, and even rarer generalized forms can develop<sup>2,3</sup>. Females are more commonly affected than males. The head, neck, extremities, breasts, and genitalia are common sites in descending order. Lesions have a firm consistency and range from red-brown to violaceous in color and can be pruritic, ulcerated, or crusted<sup>1,4</sup>. The clinical differential diagnosis includes granuloma faciale, angiolymphoid hyperplasia with eosinophilia, nodular secondary syphilis, lymphoma, leukemia cutis, Merkel cell tumor, and metastatic carcinoma.

In most cases, CBPL is idiopathic. However, some lesions are associated with exposure to foreign antigens from arthropods, infections, tattoos, acupuncture, trauma, vaccination, gold jewelry, or medications<sup>1,2,5-7</sup>. In our cases, the first case might be induced by persistent arthropod bite reaction. Since the second patient had a history of poison ivy contact dermatitis on the site of CBPL, the CBPL might be associated with repeated trauma following scratching of pruritic skin lesions.

Histopathologic examination of CBPL lesion reveals a dense nodular or diffuse lymphoid infiltration which tends to be top-heavy and taper out in the

lower dermis<sup>1,2</sup>. The dermal infiltrate is composed primarily of small mature lymphocytes with minor components of large lymphoid cells, histiocytes, plasma cells, and/or eosinophils<sup>1,3</sup>. Many of the reported cases exhibit well-defined reactive lymphoid follicles with or without germinal center.

A principle challenge in the differential diagnosis of CBPL is its distinction from cutaneous B cell lymphoma (CBCL). Especially, differentiating CBPL from follicular CBCL or marginal zone lymphoma can be difficult<sup>1,2,4,7-10</sup>. Clinically CBPL often are seen as a solitary papule or nodule on the head and neck area, whereas CBCL may be larger and deeper with ulceration in the absence of trauma. In CBPL, there may be a history of a causative event with a tendency to regress without any treatment, whereas CBCL may have no defined cause and persist or worsen<sup>1</sup>. The histopathologic features that favor CBPL include epidermal change of acanthosis, top-heavy and heterogeneous cellular infiltrates, presence of germinal center with or without tingible bodies, vascular proliferation and the preservation of the adnexal structures<sup>1,2,7</sup>. In the immunohistochemical staining, the reactivity for Bcl-2 is important to diagnose CBCL. In our cases, several clinical and histopathologic aspects lead to suspect the benignity of the lesions. First, the lesions were relatively small and well-demarcated, symmetric, solitary nodules with preceding possible causative events. Secondly, there were no recurrence on the sites of excision or other body regions each for 13 and 18 months without any systemic symptoms. Finally, kappa and lambda light chain stainings showed polyclonal pattern and Bcl-2 stainings were also negative. However, it is not always possible to differentiate CBCL from CBPL on the basis of clinical or histopathologic findings alone. Recently, the only reliable tool is known to the demonstration of B cell monoclonality by southern blotting or polymerase chain reaction<sup>8,9</sup>. Southern blotting, however, is difficult to perform as part of a diagnostic workup because it requires a large amount of frozen specimen<sup>9</sup>. Therefore, IgH gene rearrangement by PCR in paraffin embedded materials has been widely accepted as the most reliable and easy technique for differentiation of CBCL with CBPL more recently.<sup>8,9</sup> Although our two cases were diagnosed as malignant B cell lymphoma based on the hematoxylin-eosin stained finding initially, the results of PCR of IgH gene re-

arrangement were compatible with CBPL. In Korea, there was only one case report of CBPL that was confirmed by IgH gene rearrangement<sup>2</sup>. Cho et al.<sup>10</sup> suggested that immunostaining, particularly such as CD30, CD56, and Ki-67, may provide useful information in distinguishing benign from malignant lymphoproliferative disease, but there was no comment about PCR method of gene rearrangement. Herein, we present two cases of B cell pseudolymphomas which showed no clonality of IgH gene rearrangement. We expect that the PCR of IgH gene rearrangement will contribute to the differential diagnosis between B cell pseudolymphoma and malignant B cell lymphoma with clinicopathologic correlation.

## REFERENCES

1. Ploysangam T, Breneman DL, Mutasim DF: Cutaneous pseudolymphomas. *J Am Acad Dermatol* 38:877-905, 1998
2. Chang SE, Kim SH, Choi JH, Sung KJ, Moon KC, Koh JK: A case of cutaneous B-cell pseudolymphoma. *Korean J Dermatol* 38:286-288, 2000
3. Torne R, Roura M, Umbert P: Generalized cutaneous B-cell pseudolymphoma. Report of a case studied by immunohistochemistry. *Am J Dermatopathol* 11:544-548, 1989
4. Pimpinelli N, Santucci M, Mori M, Vallecchi C, Giannotti B: Primary cutaneous B-cell lymphoma: A clinically homogeneous entity? *J Am Acad Dermatol* 37:1012-1016, 1997
5. Kabayashi Y, Nanko H, Nakamura J, Mizoguchi M: Lymphocytoma cutis induced by gold pierced earrings. *J Am Acad Dermatol* 27:457-458, 1992
6. Kalima K, Rasanen L, Aho H, Maki J, Mustikkamäki UP, Rantala I: Persistent cutaneous pseudolymphoma after intradermal gold injection. *J Cutan Pathol* 23:328-334, 1996
7. Baldassano MF, Bailey EM, Ferry JA, Harris NL, Duncan LM: Cutaneous lymphoid hyperplasia and cutaneous marginal zone lymphoma. *Am J Surg Pathol* 23:88-96, 1999
8. Bouloc A, Delfau-Larue MH, Lenormand B, et al: Polymerase chain reaction analysis of immunoglobulin gene rearrangement in cutaneous lymphoid hyperplasias. *Arch Dermatol* 135:168-172, 1999
9. Nakayama F, Kurosu K, Yumoto N, et al: Immunoglobulin gene analysis of cutaneous pseudolymphoma by polymerase chain reaction. *J Dermatol* 22:403-410, 1995
10. Cho KH, Han KH, Chung JH, Eun HC, Youn JI, Kim CW: Immunohistochemical analysis of cutaneous pseudolymphoma. *Kor J Dermatol* 37:198-205, 1999