



Abnormal somatosensory evoked potential findings in syringomyelia

Yeon-Jung Mun¹, Dae-Seong Kim^{1,2}

¹Department of Neurology, Pusan National University Yangsan Hospital, Yangsan, Korea

²Department of Neurology, Pusan National University School of Medicine, Yangsan, Korea

Key words: Evoked potential; Somatosensory; Syringomyelia; Spinal cord

Received: December 20, 2023

Revised: February 20, 2024

Accepted: March 21, 2024

Correspondence to

Dae-Seong Kim

Department of Neurology, Pusan National University School of Medicine, 49 Busandaehak-ro, Mulgeum-eup, Yangsan 50612, Korea
Tel: +82-55-360-2450
Fax: +82-55-360-2152
E-mail: dskim@pusan.ac.kr

ORCID

Yeon-Jung Mun

<https://orcid.org/0009-0003-2222-4953>

Dae-Seong Kim

<https://orcid.org/0000-0003-0586-4775>

Syringomyelia is characterized by the presence of a type of syrinx within the spinal cord that is filled with cerebrospinal fluid, and manifests with variable symptoms and signs depending on the lesion location and extent. Common presentations include dissociated sensory loss and dysfunction of lower motor neurons.¹

A 60-year-old female presented with progressive hand muscle atrophy and weakness since the age of 30 years. A neurological examination revealed symmetrical muscle atrophy and weakness in her intrinsic hand muscles. Her muscle power on the Medical Research Council scale was graded as 3 for finger flexion and extension, and 1 for finger fanning bilaterally. Bilateral hypesthesia to pinprick and temperature stimuli was observed from C3 to T12 dermatomes, while vibration sensation and proprioception were preserved. Deep tendon reflexes were lost in both upper extremities, but were normal in the lower extremities. Babinski signs were evoked bilaterally, but Hoffman signs were absent.

Magnetic resonance imaging showed an extensive syrinx from C2 to T10 without a Chiari I malformation (Fig. 1A, B). The median somatosensory evoked potentials (SEPs) were normal for N9 (Erb's point), but small for N13 (cervical potential) and N19 (cortical potential) bilaterally, with normal absolute and interpeak latencies (Fig. 1C). The tibial SEP was unremarkable (Fig. 1D).

While it is generally believed that SEP is unaffected in patients with syringomyelia, which typically manifests as dissociated sensory loss, abnormalities such as loss of N13 and N19, loss of N13 with small N20, or small N13 and N20 have been reported in some patients. Although SEP abnormalities have been found frequently in patients exhibiting posterior column dysfunction, they were also observed in some patients with preserved proprioception and vibration sensation, as in the present case.² This may reflect the presence of subclinical proprioceptive dysfunction or the contribution of spinal gray matter to SEP generation in patients with syringomyelia, and the degree of amplitude reduction may be correlated with the severity of clinical involvement.^{2,3}

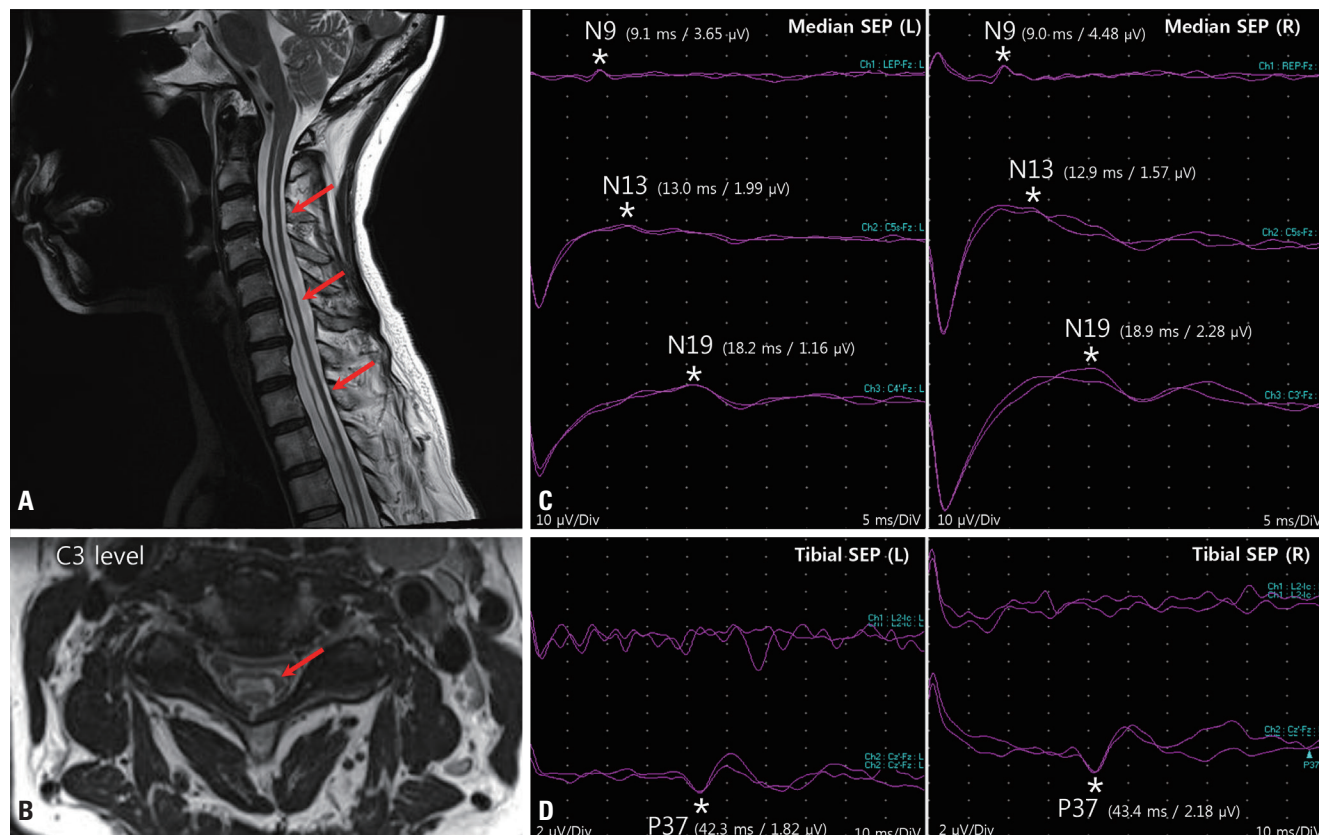


Fig. 1. Sagittal (A) and axial (B, C3 level) images from cervical spine T2-weighted magnetic resonance imaging. An extensive syrinx had developed within the spinal cord (from C2 to T10) (arrows). Median somatosensory evoked potentials (SEPs) (C) were normal for N9 but small for N13 and N19. The tibial SEP (D) was normal for P37 bilaterally in the lower limbs. *Represent the locations of each potential.

Conflicts of Interest

The authors declare no conflicts of interest relevant to this article.

Funding

This work was supported by a 2-year Research Grant of Pusan National University.

REFERENCES

1. Giner J, Pérez López C, Hernández B, Gómez de la Riva Á, Isla A, Roda JM. Update on the pathophysiology and management of syringomyelia unrelated to Chiari malformation. *Neurologia (Engl Ed)* 2019;34:318-325.
2. Morioka T, Kurita-Tashima S, Fujii K, Nakagaki H, Kato M, Fukui M. Somatosensory and spinal evoked potentials in patients with cervical syringomyelia. *Neurosurgery* 1992;30:218-222.
3. Anderson NE, Frith RW, Synek VM. Somatosensory evoked potentials in syringomyelia. *J Neurol Neurosurg Psychiatry* 1986;49:1407-1410.