



Refractory Bell's palsy responding to late treatment with high-dose intravenous steroids

Baul Kim¹, Soo-Im Jang¹, Soo-Hyun Park², Nam-Hee Kim¹

¹Department of Neurology, Dongguk University Ilsan Hospital, Goyang, Korea

²Department of Neurology, Inha University Hospital, Incheon, Korea

Received: June 15, 2021

Revised: August 13, 2021

Accepted: August 16, 2021

Correspondence to

Nam-Hee Kim

Department of Neurology, Dongguk University Ilsan Hospital, 27 Dongguk-ro, Ilsandong-gu, Goyang 10326, Korea
Tel: +82-31-961-7214
Fax: +82-31-961-7212
E-mail: nheekim8@hanmail.net

ORCID

Baul Kim

<https://orcid.org/0000-0002-9399-1952>

Soo-Im Jang

<https://orcid.org/0000-0002-9452-4897>

Soo-Hyun Park

<https://orcid.org/0000-0003-1626-3940>

Nam-Hee Kim

<https://orcid.org/0000-0003-0507-5653>

Bell's palsy is an acute peripheral facial paralysis with no detectable cause. Although the prognosis of Bell's palsy is generally good, some patients experience poor recoveries and there is no established treatment for those that do not recover even after receiving the conventional treatment. Here we present two cases of refractory Bell's palsy with facial nerve enhancement in magnetic resonance imaging who showed symptomatic improvement after the late administration of high-dose intravenous methylprednisolone.

Key words: Bell's palsy; Facial palsy; Intravenous; Steroid

Bell's palsy is the most common form of acute facial weakness, with an annual incidence of 20 to 30 cases per 100,000 persons.¹ The reactivation of latent herpes simplex virus or varicella zoster virus within geniculate ganglia causes neuropathy with cytotoxic edema induced by neuronal inflammation in Bell's palsy.² Thus, facial nerve enhancement usually appears initially and then disappears at a follow-up performed after more than 1 month with the recovery of facial weakness.³ This pathogenesis has led to corticosteroids and antiviral agents being used to treat Bell's palsy. Although most patients with Bell's palsy either partially or completely recover within 3 weeks to 3 months, up to 30% of the patients have long-term sequelae such as permanent facial weakness even after receiving appropriate treatment.⁴ Nonrecovering facial weakness may be disfiguring, socially isolating, psychologically morbid, and occasionally debilitating due to severe corneal damage. The prognosis of patients with Bell's palsy is most reliably predicted by the severity of degeneration of the facial nerve.⁵ In addition, it is argued that facial nerve enhancement in magnetic resonance imaging (MRI) is one of poor prognostic factors for Bell's palsy.³

There is no established treatment for patients who do not recover even after receiving appropriate treatment. Although larger studies are needed for confirmation, there have been a case of symptomatic improvement in nonrecovering facial palsy with facial nerve

enhancement after high-dose intravenous (IV) methylprednisolone.⁶

Here we report two cases of nonrecovering Bell's palsy with nerve enhancement even at 2 months after onset, demonstrating that recovery was accelerated by high-dose IV methylprednisolone. This finding might represent evidence of a useful treatment option for nonrecovering facial palsy.

CASE

Case 1

A 53-year-old male experienced sudden-onset left peripheral facial palsy of grade 4 according to the House-Brackmann (HB) facial grading system. He had no underlying disease other than hypertension. He was treated with oral prednisone (70 mg/day for 6 days, followed by tapering over the following 4 days) based on the body weight starting from 10 days after the clinical onset, but there was no improvement (i.e., remaining at HB grade 4) until 69 days after the onset. MRI was first performed at that time, which showed prominent diffuse enhancement in labyrinthine segments, geniculate ganglion, and tympanic and mastoid segments of the left facial nerve (Fig. 1). Laboratory studies including serology for vasculitis and the cerebrospinal fluid revealed no significant abnormality. The blink reflex and a facial nerve conduction study (NCS) showed no response in the pathway of the left facial nerve (Table 1). IV methylprednisolone

(1 g/day for 5 days) was started on day 72 after the onset, and on day 80 he reported a partial recovery of the left facial weakness to HB grade 3 (Fig. 2). On day 310, more-prominent functional recovery was observed in the left orbicularis oculi and oris muscle strength to HB grade 2, and an electrophysiological evaluation showed partial recovery of the left orbicularis oculi response in the blink reflex but no response in the facial NCS (Table 1).

Case 2

A 73-year-old male patient experienced an acute severe left facial palsy of HB grade 5. He had no specific underlying disease. He received oral prednisone (70 mg/day for 6 days, followed by tapering) based on the body weight with an antiviral agent (Famvir at 750 mg qd for 5 days) for severe facial weakness starting from 3 days after the onset. However, there was no improvement (i.e., remaining at HB grade 5) until 60 days after the symptom onset. MRI was first performed at that time, which showed abnormal enhancement along the labyrinthine segments, geniculate ganglion, and tympanic segment of the left facial nerve (Fig. 1). Laboratory studies including serology for vasculitis and the cerebrospinal fluid revealed no significant abnormality. The blink reflex and a facial NCS revealed no response in the pathway of the left facial nerve (Table 1). IV methylprednisolone (1 g/day for 5 days) was started on day 60 after the onset, and on day 65 he reported partial recovery of the left facial weakness to HB grade 4 (Fig. 2). More-prominent functional recovery was observed in the left orbicularis oculi and oris muscle strength

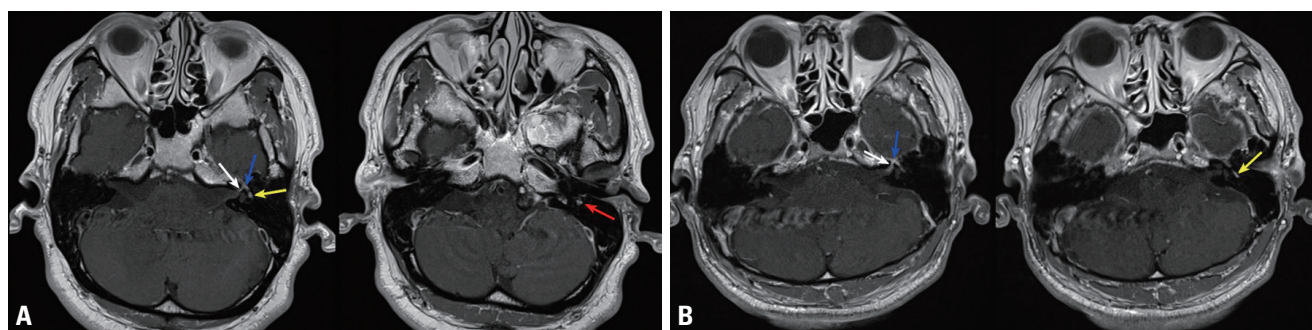


Fig. 1. (A) Internal auditory canal magnetic resonance imaging (MRI) in case 1 (53 days after the onset): gadolinium-enhanced T1-weighted axial MRI exhibited prominent diffuse enhancement in the labyrinthine (white arrow), geniculate ganglion (blue arrow), and tympanic (yellow arrow) and mastoid segments (red arrow) of the left facial nerve. (B) Internal auditory canal MRI in case 2 (60 days after the onset): gadolinium-enhanced T1-weighted axial MRI exhibited abnormal enhancement along the labyrinthine segments (white arrow), geniculate ganglion (blue arrow), and tympanic segment (yellow arrow) of the left facial nerve.

Table 1. Findings of electrophysiological tests over time in the two cases

Time point after onset	2-3 months			5-7 months			10-18 months		
Case 1									
Days after onset	53			153			310		
Blink reflex									
Unaffected side (right)	R1 D	R2 D	R2 C	R1 D	R2 D	R2 C	R1 D	R2 D	R2 C
	10.9 ms	37.4 ms	38.2 ms	11.2 ms	36.0 ms	37.3 ms	10.6 ms	35.8 ms	35.2 ms
Affected side (left)	R1 D	R2 D	R2 C	R1 D	R2 D	R2 C	R1 D	R2 D	R2 C
	NR	NR	NR	NR	NR	NR	15.2 ms	42.8 ms	43.6 ms
Facial NCS									
Unaffected side (right)	Latency	Amplitude		Latency	Amplitude		Latency	Amplitude	
	3.2 ms	7.0 mV		3.1 ms	7.1 mV		3.0 ms	9.2 mV	
Affected side (left)	Latency	Amplitude		Latency	Amplitude		Latency	Amplitude	
	NR	NR		NR	NR		NR	NR	
Case 2									
Days after onset	60			198			535		
Blink reflex									
Unaffected side (right)	R1 D	R2 D	R2 C	R1 D	R2 D	R2 C	R1 D	R2 D	R2 C
	11.2 ms	31.6 ms	31.6 ms	10.8 ms	32.5 ms	33.0 ms	9.6 ms	33.3 ms	34.6 ms
Affected side (left)	R1 D	R2 D	R2 C	R1 D	R2 D	R2 C	R1 D	R2 D	R2 C
	NR	NR	NR	NR	NR	NR	11.6 ms	35.8 ms	35.9 ms
Facial NCS									
Unaffected side (right)	Latency	Amplitude		Latency	Amplitude		Latency	Amplitude	
	2.9 ms	2.9 mV		2.7 ms	5.3 mV		2.6 ms	4.6 mV	
Affected side (left)	Latency	Amplitude		Latency	Amplitude		Latency	Amplitude	
	NR	NR		NR	NR		3.6 ms	2.5 mV	

Blink reflex test was performed by stimulating the supraorbital nerve and recording the response in the orbicularis oculi muscle. Facial NCS was performed by stimulating the zygomatic branch of the facial nerve and recording the response in the orbicularis oculi muscle.

R1, R1 response; R2, R2 response; D, direct response; C, consensual response; NR, no response; NCS, nerve conduction study.

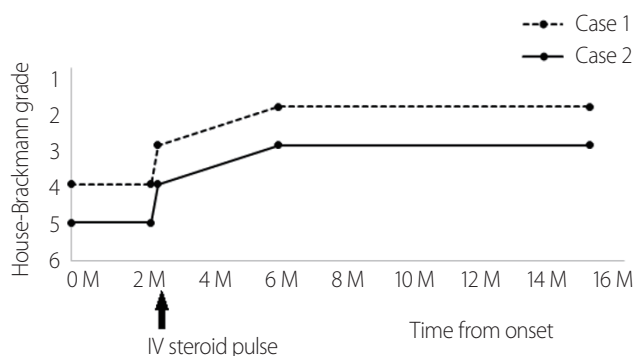


Fig. 2. Recovery of facial nerve function over time. Intravenous (IV) steroid pulse therapy appeared to accelerate the recovery of facial weakness in refractory cases. M, months.

up to HB grade 3 on day 198, and an electrophysiological evaluation on day 535 showed partial recovery of the left orbicularis oculi muscle response in the blink reflex (Table 1). In addition, compared to the first NCS result (no response), the amplitude of compound muscle action potentials had improved on day 535 (to 54% relative to the normal side).

DISCUSSION

Treatment of Bell's palsy is based on the empirical administration of oral steroids, with the addition of an antiviral drug

such as acyclovir, famciclovir, or valacyclovir if symptoms are severe.¹ In our patients, the conventional antiviral and oral corticosteroid treatment did not result in any clinical improvement, whereas the administration of high-dose IV methylprednisolone on day 72 after the onset in one patient and on day 60 in the other patient accelerated their recovery of facial weakness. This suggests that high-dose IV steroid therapy favorably influences the outcome in nonrecovering facial palsy.

The prognosis of Bell's palsy can be predicted most accurately from the degree of facial nerve degeneration.⁵ It is now well known that Bell's palsy is more likely to have a poor prognosis if more than 90% of facial nerve degeneration is present in electroneurography.⁵ Conventional treatment is often insufficient in patients exceeding this critical limit, which results in the probability of a full recovery from facial paralysis being only 0-25% in these patients.⁷ Therefore, research is needed into treatment options to promote recovery in these patients. The reported poor prognostic factors in Bell's palsy include being older than 40 years, having poor electrophysiological results after 2 weeks of treatment, and the presence of diabetes or hypertension.⁴

The mechanisms underlying abnormal contrast enhancement in cranial nerves are not yet fully understood. This enhancement is thought to be related either to hypervascularity of perineural structures or to actual disruption of the blood-nerve barrier resulting from inflammation.⁸ A characteristic finding is that the internal acoustic meatal segment of the facial nerve is enhanced only on the side affected by Bell's palsy, and this MRI enhancement is known to have no definite correlations with the severity of the facial palsy or the results of electrophysiological examinations. The disappearance of facial nerve enhancement, which usually occurs at follow-ups performed after more than 1 month, was found to be related to improved facial nerve function during the recovery from Bell's palsy.⁸

Our two cases had facial nerve enhancement findings on MRI even at 2 months after the onset of facial palsy, which suggests ongoing inflammation of the facial nerve.⁹ Glucocorticoids can be used to accelerate the recovery from this inflammation due to their anti-inflammatory effects, which are mainly attributable to the action of glucocorticoid receptors that alter the transcription of numerous genes in cells.¹⁰ We administered IV methylprednisolone in cases of nonre-

covering facial palsy after ruling out other possible causes of cranial nerve inflammation, with the results suggesting that the late application of high-dose IV steroid can improve facial weakness that has not yet recovered.

Therefore, it can be assumed that high-dose IV steroid treatment might be a useful therapy for Bell's palsy that has not recovered with the standard regimen of an antiviral plus oral steroid. Furthermore, the improvement noted in our patients suggests that this treatment is successful even as a late treatment option. However, larger studies are needed to confirm this hypothesis.

Conflicts of Interest

The authors have no conflicts to disclose.

REFERENCES

1. Holland NJ, Weiner GM. Recent developments in Bell's palsy. *BMJ* 2004;329:553-557.
2. Peitersen E. Bell's palsy: the spontaneous course of 2,500 peripheral facial nerve palsies of different etiologies. *Acta Otolaryngol Suppl* 2002;(549):4-30.
3. Kress B, Griesbeck F, Stippich C, Bähren W, Sartor K. Bell palsy: quantitative analysis of MR imaging data as a method of predicting outcome. *Radiology* 2004;230:504-509.
4. Yoo MC, Soh Y, Chon J, Lee JH, Jung J, Kim SS, et al. Evaluation of factors associated with favorable outcomes in adults with Bell palsy. *JAMA Otolaryngol Head Neck Surg* 2020;146:256-263.
5. Fisch U. Prognostic value of electrical tests in acute facial paralysis. *Am J Otol* 1984;5:494-498.
6. Donati D, De Santi L, Ginanneschi F, Cerase A, Annunziata P. Successful response of non-recovering Ramsay Hunt syndrome to intravenous high dose methylprednisolone. *J Neurol Sci* 2012;318:160-162.
7. May M, Blumenthal F, Klein SR. Acute Bell's palsy: prognostic value of evoked electromyography, maximal stimulation, and other electrical tests. *Am J Otol* 1983;5:1-7.
8. Tien RD, Dillon WP. Herpes trigeminal neuritis and rhombencephalitis on Gd-DTPA-enhanced MR imaging. *AJNR Am J Neuroradiol* 1990;11:413-414.
9. Kim IS, Shin SH, Kim J, Lee WS, Lee HK. Correlation between MRI and operative findings in Bell's palsy and Ramsay Hunt syndrome. *Yonsei Med J* 2007;48:963-968.

10. Coutinho AE, Chapman KE. The anti-inflammatory and immunosuppressive effects of glucocorticoids, recent developments and mechanistic insights. *Mol Cell Endocrinol* 2011;335:2-13.