

## Misidentification of *Brevibacterium casei* as *Propionibacterium acnes* Isolated from the Blood of a Patient with Malignant Lymphoma

Yu Jung Jung, Hee Jae Huh, Chang-Seok Ki, Nam Yong Lee

Department of Laboratory Medicine and Genetics, Samsung Medical Center,  
Sungkyunkwan University School of Medicine, Seoul, Korea

*Brevibacterium* spp. are Gram-positive, irregularly rod-shaped, strictly aerobic bacteria that resemble corynebacteria. Since they are a part of normal skin flora, they have been regarded as apathogenic, and human infections related to them are very rare. A 46-year-old man previously diagnosed with diffuse large B-cell lymphoma presented with fever without a definitive infectious source. Blood cultures from both peripheral blood and a central venous catheter showed that only aerobic bottles grew contaminants, while anaerobic bottles did not. Although the automated microbial identification system indicated *Prop-*

*ionibacterium acnes*, the isolated species was identified as *B. casei* by 16S rRNA sequence analysis. Our case emphasizes the utilization of 16S rRNA sequence analysis when the result from an automated system does not correspond with other laboratory findings. This is the first case of catheter-related blood stream infection due to *B. casei* identified by 16S rRNA sequence analysis. (**Ann Clin Microbiol 2014;17:95-98**)

**Key Words:** *Brevibacterium casei* bacteremia, 16S rRNA sequence analysis

### INTRODUCTION

*Brevibacterium* spp. are Gram-positive, irregularly rod-shaped, strictly aerobic bacteria that resemble corynebacteria. In the past, they were regarded as apathogenic organisms, since these coryneform bacteria are actually a part of normal skin flora. For this reason, when it comes to blood stream infections, *Brevibacterium* bacteremia is not usually assigned great importance, mostly due to its extremely low frequency and sometimes, misidentification [1,2]. Notwithstanding its rarity in septicemia, the *Brevibacterium* spp. is not insignificant. Up until now, several cases involving *Brevibacterium* spp. bacteremia in both immunocompromised [3-7] and immunocompetent [8] patients were reported, and this microorganism was definitively identified as the causative pathogen. In this case, we report a male patient with *Brevibacterium casei* bacteremia identified by 16S rRNA sequencing.

### CASE REPORT

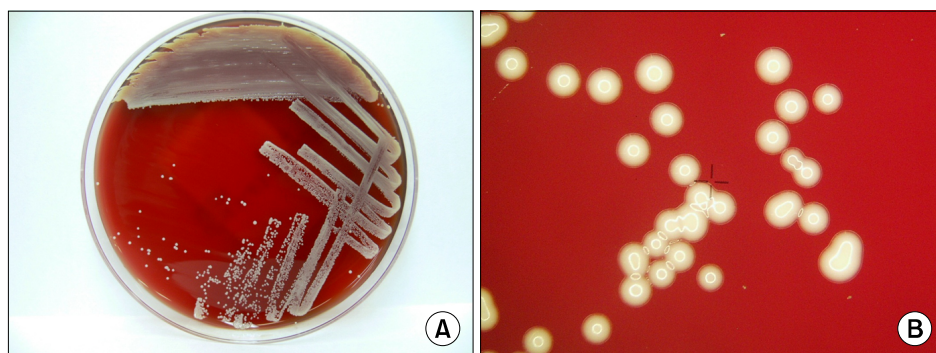
A 46-year-old male presented with fever, chills, and several non-specific symptoms such as arthralgias, nausea, and dizziness was admitted to our hospital via the emergency room. Two months ago, he was diagnosed with diffuse large B cell lymphoma at the distal ileum, and underwent right hemicolectomy followed by chemotherapy with R-CHOP (rituximab, cyclophosphamide, doxorubicin, vincristine and prednisolone). Originally, the second round of chemotherapy was scheduled a week prior to admission, but since his general condition was rather poor, it was delayed and further studies for high fever were carried out. He had a Hickman catheter inserted about a month prior to presentation at another hospital. Leukocyte count was 5,230/ $\mu$ L, C-reactive protein (CRP) was 0.13 mg/dl, and procalcitonin was 0.19 ng/ml — all within reference ranges. His blood pressure was 135/85 mmHg and body temperature was 39.8°C. At first, blood

Received 5 March, 2014, Revised 24 June, 2014, Accepted 25 June, 2014

Correspondence: Nam Yong Lee, Department of Laboratory Medicine and Genetics, Samsung Medical Center, Sungkyunkwan University School of Medicine, 81 Irwon-ro, Gangnam-gu, Seoul 135-710, Korea. (Tel) 82-2-3410-2706, (Fax) 82-2-3410-2719, (E-mail) micro.lee@samsung.com

© The Korean Society of Clinical Microbiology.

© This is an Open Access article distributed under the terms of the Creative Commons Attribution Non-Commercial License (<http://creativecommons.org/licenses/by-nc/3.0>) which permits unrestricted non-commercial use, distribution, and reproduction in any medium, provided the original work is properly cited.

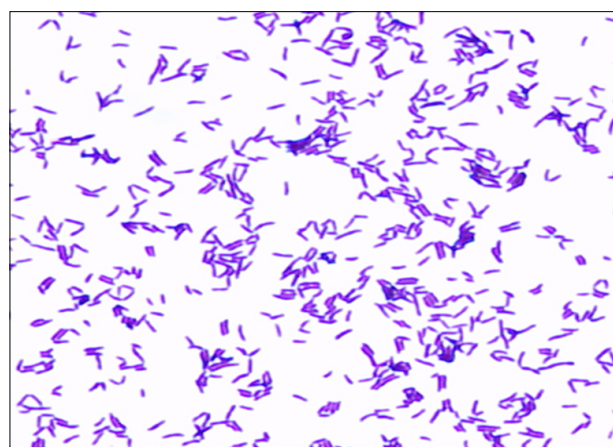


**Fig. 1.** (A) Whitish-gray colored small colonies of *B. casei* on sheep blood agar plate. (B) Colonies magnified through Dissecting Microscope (magnification,  $\times 6$ ).

was drawn from two different peripheral venipuncture sites for culture, and the following day, blood cultures were also drawn directly from the Hickman catheter. Four days later for each of the bottles, a certain microorganism had been growing only in aerobic culture bottles in the BacT/Alert 3D system (bioMérieux Inc; Durham, NC, USA), both for peripheral and central venous blood. Empirical antibiotic therapy was started with intravenous vancomycin 1,000 mg/day. The blood sample was inoculated into BAP, MacConkey agar plate, and Chocolate agar plate, according to our protocol for positive organisms in only aerobic culture bottles. After 2 days of inoculation, whitish pinpoint-shaped colonies were observed on BAP and the Chocolate agar plates (Fig. 1A). They were whitish-gray colored small colonies with a unique cheesy odor (Fig. 1B). On gram staining, coryneform gram-positive rods were observed (Fig. 2).

Biochemical identification was performed via Vitek II (Vitek II XL; bioMérieux, Hazelwood, MO, USA) ANC card. We obtained a good result (indicating 91% probability) for *Propionibacterium acnes*, which is a gram-positive rod that is relatively slow-growing and most importantly, typically aerotolerant.

For a definitive identification of the bacteria, we performed 16S rRNA gene sequencing. The 16S rRNA gene fragments were amplified by standard methods according to CLSI guidelines [9]. Two sub-regions of the 16S rRNA gene were amplified using the following primer pairs: forward, 4F: 5'-TTG GAG AGT TTG ATC CTG GCT C-3' and reverse, 534R: 5'-TAC CGC GGC TGC TGG CAC-3' and forward, 27F: 5'-AGA GTT TGA TCM TGG CTC AG-3' and reverse, 801R: 5'-GGC GTG GAC TTC CAG GGT ATC T-3'. The amplified sequences were compared with the GenBank (NCBI) database using the basic local alignment search tool (BLAST) algorithm. The 16S rRNA sequence of the isolate revealed 99.4% similarity (659 of 663 bases) to a type strain of *B. casei* (GenBank accession number, X76564.1). The most closely related known species within the



**Fig. 2.** Peripheral blood Gram stain of *Brevibacterium casei* under a light microscope ( $\times 1,000$ ). Gram positive, rod-shaped coryneform bacteria.

GenBank was *B. sanguinis* with a sequence identity of 97.6%. As a result, we could identify these coryneform rods as *B. casei*.

After five days of intravenous vancomycin therapy, antibiotics were switched to ampicillin/sulbactam for two days. During his use of vancomycin, two sets of blood culture bottles from peripheral blood were negative, and culture from Hickman catheter tip was also clear. Because of these negative results from both peripheral and catheter blood, his condition was considered to have returned to normal and he resumed chemotherapy.

## DISCUSSION

*Brevibacterium* spp. belongs to the coryneform bacteria, which is a collective term for bacteria that are gram-positive, irregularly V-shaped rods, aerobic, asporogenous, and non-partially-acid-fast. They were deemed as normal flora of human skin and for this reason, people used to think they were apathogenic.

Later, a handful of cases related to *Brevibacterium* spp. human infections of clinical significance were confirmed in the early-1990s [1,10], and gradually its clinical importance started to become recognized. In 1994, Gruner et al. [11] discovered that of 41 strains in the collection of the Bacteriology Reference Laboratory of the Centers for Disease Control and Prevention, formerly assigned to CDC groups B-1 and B-3, 22 were *B. casei* in fact, and 11 of them were isolated from blood cultures. There were other reports followed after that, and in 2006, Ulrich et al. [8] reported another 6 *B. casei* bacteremia cases [3,4,6,7,12] including their own case with review of literature. Up until recently, most reported cases were related to bacteremia in immunocompromised patients, as it was in our patient.

*B. casei* strains are known to be susceptible to the aminoglycosides, rifampin, tetracycline, teicoplanin, and the glycopeptides vancomycin [13]. On a similar note, a previous report by Poesen et al. [14] indicated that *B. casei* was susceptible to quinolones or glycopeptides when using CLSI criteria for coryneform bacteria. Considering the clinical evidence for vancomycin treatment, vancomycin was administered intravenously to the patient in our case. After 3 days of antibiotics therapy, both his blood and catheter cultures turned negative.

Herein, we found out that the results from automated microbial identification system could be far different from what the organism really was. This is the very first case of *B. casei* bacteremia identified by 16S rRNA-based gene sequencing, which highlighted that an automated system for microbial identification results should be interpreted critically. The 16S rRNA-based gene sequencing could be significantly important for definitive microbial identification under certain circumstances.

Poesen et al. [14] reported a case of *B. casei* peritonitis identified by 16S rRNA that also revealed different results between the automated microbial identification system (55.2% *Brevibacterium* species, 41.9% *Arthrobacter* species by API Coryne system) and 16S rRNA sequencing (*B. casei*). In our case, we misidentified *B. casei* as *P. acnes* via Vitek II.

In this regard, clinical microbiologists should be aware that certain species like *Brevibacterium* sp. might be challenging to identify by automated microbial identification system and biochemical tests. Given that *Brevibacterium* spp. are not regarded as apathogenic, it is also of great importance to suspect *Brevibacterium* spp. when Gram-positive rods with distinctive cheese-like odor grow only in aerobic blood culture bottles [13],

especially in febrile immunocompromised patients. By doing so, earlier treatment with appropriate antibiotics could be administered to a patient.

## REFERENCES

1. Gruner E, Pfyffer GE, von Graevenitz A. Characterization of *Brevibacterium* spp. from clinical specimens. *J Clin Microbiol* 1993;31: 1408-12.
2. Wauters G, Haase G, Avesani V, Charlier J, Janssens M, Van Broeck J, et al. Identification of a novel *Brevibacterium* species isolated from humans and description of *Brevibacterium sanguinis* sp. nov. *J Clin Microbiol* 2004;42:2829-32.
3. Castagnola E, Conte M, Venzano P, Garaventa A, Viscoli C, Barretta MA, et al. Broviac catheter-related bacteraemias due to unusual pathogens in children with cancer: case reports with literature review. *J Infect* 1997;34:215-8.
4. Janda WM, Tipirneni P, Novak RM. *Brevibacterium casei* bacteremia and line sepsis in a patient with AIDS. *J Infect* 2003; 46:61-4.
5. Lina B, Carlotti A, Lesaint V, Devaux Y, Freney J, Fleurette J. Persistent bacteremia due to *Brevibacterium* species in an immunocompromised patient. *Clin Infect Dis* 1994;18:487-8.
6. Brazzola P, Zbinden R, Rudin C, Schaad UB, Heininger U. *Brevibacterium casei* sepsis in an 18-year-old female with AIDS. *J Clin Microbiol* 2000;38:3513-4.
7. Reinert RR, Schnitzler N, Haase G, Lütticken R, Fabry U, Schaal KP, et al. Recurrent bacteremia due to *Brevibacterium casei* in an immunocompromised patient. *Eur J Clin Microbiol Infect Dis* 1995;14:1082-5.
8. Ulrich S, Zbinden R, Pagano M, Fischler M, Speich R. Central venous catheter infection with *Brevibacterium* sp. in an immunocompetent woman: case report and review of the literature. *Infection* 2006;34:103-6.
9. Clinical and Laboratory Standard Institute. Interpretive criteria for identification of bacteria and fungi by DNA target sequencing; approved guideline. Document MM18-A. Wayne, PA; Clinical and Laboratory Standard Institute, 2008.
10. McCaughey C and Damani NN. Central venous line infection caused by *Brevibacterium epidermidis*. *J Infect* 1991;23:211-2.
11. Gruner E, Steigerwalt AG, Hollis DG, Weyant RS, Weaver RE, Moss CW, et al. Human infections caused by *Brevibacterium casei*, formerly CDC groups B-1 and B-3. *J Clin Microbiol* 1994;32: 1511-8.
12. Kaukoranta-Tolvanen SS, Sivonen A, Kostiala AA, Hormila P, Vaara M. Bacteremia caused by *Brevibacterium* species in an immunocompromised patient. *Eur J Clin Microbiol Infect Dis* 1995;14:801-4.
13. Funke G, von Graevenitz A, Clarridge JE 3rd, Bernard KA. Clinical microbiology of coryneform bacteria. *Clin Microbiol Rev* 1997;10:125-59.
14. Poesen K, Meeus G, Boudewijns M, Colaert J, Doubel P. Relapsing *Brevibacterium casei* peritonitis: value of 16S rRNA gene sequencing in accurate species identification. *Perit Dial Int* 2012;32:341-4.

=국문초록=

## 림프선 암환자의 혈액에서 분리된 *Brevibacterium casei*가 *Propionibacterium acnes*로 잘못 동정된 1예

성균관대학교 의과대학 삼성서울병원 진단검사의학교실

정유정, 허희재, 기창석, 이남용

*Brevibacterium* 군종은 V 모양 혹은 불규칙한 모양을 보이는 그람 양성 간균으로, *corynebacteria*와 비슷한 특징을 가지는 절대 호기성 균종이다. 대개 사람의 점막이나 피부에 상재균으로 존재하여 비병원성으로 여겨져 왔으며 사람에서의 감염이 보고된 예는 매우 드물다. 본 증례에서는 미만성 대세포형 B 세포 림프종을 진단받은 46세 남자환자에서 발열 증상이 있어 말초 혈액과 Hickman 카테터를 통해 혈액배양을 실시한 결과 혐기성 혈액 배양병에서는 자라지 않고 호기성 혈액 배양병에서만 자라는 균의 증식이 확인되었다. 이는 VITEK II ANC card에서 *Propionibacterium acnes*로 동정되었으나 16S rRNA 유전자 염기서열 분석을 통하여 *B. casei*로 확인되었다. 본 증례는 16S rRNA 유전자 염기서열 분석을 통해 *B. casei*로 인한 카테터 관련 혈류 감염을 진단한 첫 보고이며, 증례에서와 같이 자동화 장비에서 보고되는 균이 기타 미생물 검사실의 검사조건 및 생화학적 성상과 불일치 소견을 보이는 경우 16S rRNA 유전자 염기서열 분석이 매우 유용함을 알 수 있다. [Ann Clin Microbiol 2014;17:95-98]

교신저자 : 이남용, 135-710, 서울시 강남구 일원로 81  
성균관대학교 의과대학 삼성서울병원 진단검사의학교실  
Tel: 02-3410-2706, Fax: 02-3410-2719  
E-mail: micro.lee@samsung.com