

A Case of Spine Origin Chondroblastoma Metastasis to Lung

Se Hoon Sohn, M.D.
Sung Aee Koh, M.D.
Dong Geun Kim, M.D.
Sung Woo Park, M.D.
Kyung Hee Lee, M.D., Ph.D.
Min Kyoung Kim, M.D., Ph.D.
Jun Hyuk Choi, M.D., Ph.D.
Myung Soo Hyun, M.D., Ph.D.

Division of Hematoocology, Department of Internal Medicine, College of Medicine, Yeungnam University, Daegu, Korea

Correspondence: Myung Soo Hyun, M.D., Ph.D.
Department of Internal Medicine, College of Medicine, Yeungnam University, Daemyeong 5-dong, Nam-gu, Daegu 705-717, Korea
Tel: 82-53-620-3837
Fax: 82-53-654-8386
E-mail: hms@med.yu.ac.kr
Received March 30, 2009
Accepted May 11, 2009

Chondroblastoma is a rare benign cartilaginous neoplasm that accounts for approximately 1% of all bone tumors and characteristically arises in the epiphysis of a long bone, particularly the humerus, tibia, and femur. Chondroblastoma can affect people of all ages. It is, however, most common in children and young adults between the ages of 10 and 20 years. Although most chondroblastomas are cured by limited surgical procedures, occasional lesions behave more aggressively and may even metastasize. In this case a young man with pulmonary metastatic chondroblastoma on spine is presented. Unlike previously published examples of metastatic chondroblastoma, these metastasis developed before any operative manipulation of the primary tumor. And primary tumor site was also unusual. The histologic characteristics of the primary, metastatic tumors were those of a conventional chondroblastoma.

Key words

Chondroblastoma, Spine origin, Lung metastasis

Introduction

Chondroblastoma was reported by Kolodny (1927) for the first time, and in 1942, by Jaffe and Lichtenstein, it was introduced as an independent disease referred to as chondroblastoma. Chondroblastoma is a rare benign bone tumor consisting of approximately 1% of the entire bone tumors developing in the epiphysis of long bones. The most prevalent invasion area are lower extremities, and in the order of the femur, humerus and tibia. Chondroblastoma could be developed in any ages, nonetheless, it is prevalent in children and young adolescent between the age of 10 and 20 years, and it occurs more frequently in the male than the female (1). The patients generally present pains and edema, and if pathologic fractures are developed, severe symptoms may be present (1).

Occasionally, chondroblastoma invades the articular cavity, and

although very rare, it may take invasive courses such as metastasis (2). Most metastatic lesions are similar to general chondroblastoma commonly detected histologically (3). Such metastatic lesions are developed after surgical resection in many cases, it metastasized in the lung primarily, and the metastasized lesions do not grow, or after the resection of pulmonary lesion, the patient survives sufficiently long in many cases (4-7).

The vertebra is a very rare primary site of chondroblastoma, and only less than 10 cases have been reported in literatures (8-10). Chondroblastoma of which primary site is the vertebra and metastasized has not been reported yet.

We experienced one case of vertebral chondroblastoma accompanying lung metastasis in an adult male, and thus we report the case. In histological examination, both primary site and the metastasized site showed the typical chondroblastoma pattern.

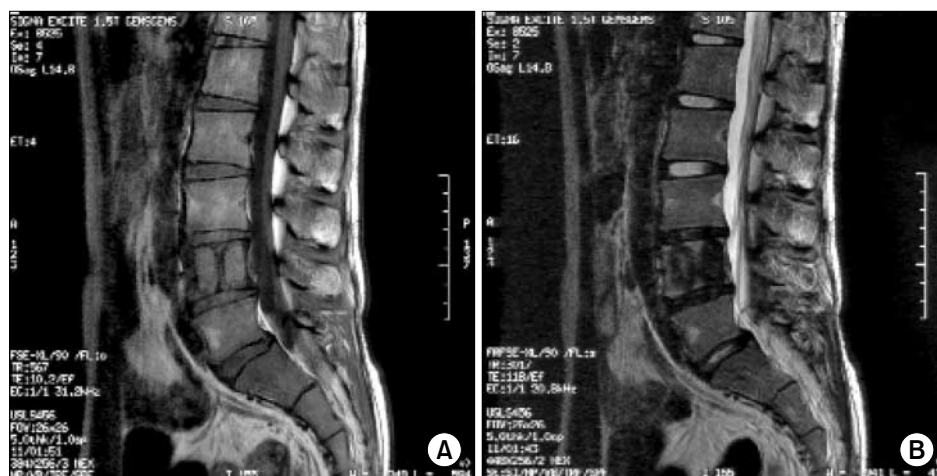

Fig. 1. L-spine MRI shows low-intensity signal on T I (A) and high-intensity signal on T II weighted images (B).

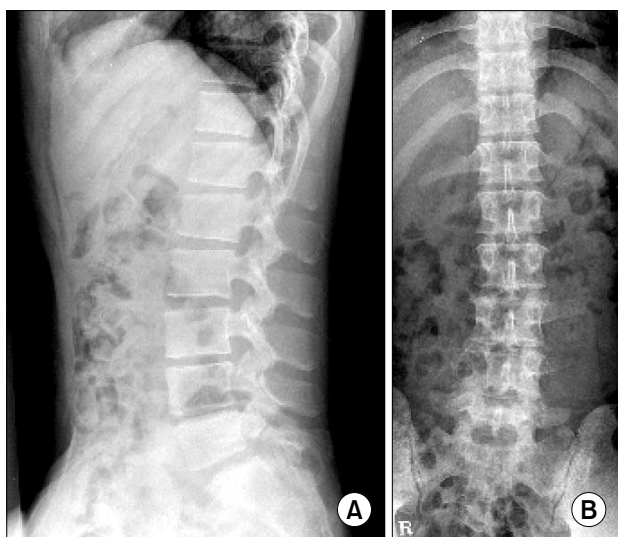


Fig. 2. L-spine AP (B), lateral (A). X-ray shows osteolytic lesion on L4.

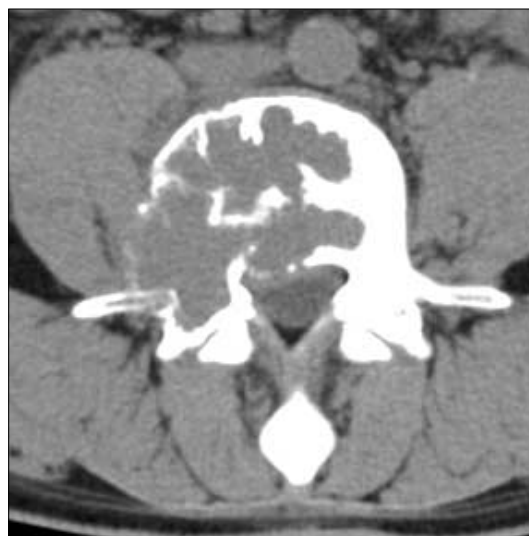

Fig. 3. L-spine CT shows Low density mass like lesion.

Case Report

A 21 years old male patient visited our hospital for lumbago persistent for 6 months. During the army service, he developed lumbago, L-spine MRI was performed, and a tumor was detected in the L4 (Fig. 1), and thus he was transferred to our hospital. The patient did not show specific results in laboratory tests and neurological examination, and among radiological results, on lumbar vertebral X-ray, osteolytic findings in the 4th lumbar vertebra were detected (Fig. 2), and also in lumbar CT, a tumor suspected to be a primary bone tumor was detected (Fig. 3). To assess the property of tumor, CT-guided bone biopsy was performed.

The result of biopsy shows relatively undifferentiated hypercellular tissues consisting of cells with round or polygonal chondroblast shape as well as the presence of the cartilaginous

interstitium, which was findings satisfying chondroblastoma. S-100 protein was detected to be equivocal (Fig. 4). On PET CT performed to assess its metastasis status, nodules with increased FDG uptake in both lower lobes of the lung were detected (Fig. 5). To block feeding vessels, we performed embolization on the RT 4th lumbar artery twice, and on angiography taken after embolization, the reduction of the staining of tumors was confirmed. Afterward, total laminectomy of L4, the primary site, was performed, the patient recovered after the surgery, and transferred to the department of thoracic surgery for pulmonary biopsy, and by performing wedge resection applying Video-Assisted Thoracic Surgery, biopsy results fitting with chondroblastoma identical to the primary site were obtained.

The patient is discharged and under 3 years follow up observation by PET CT, lumbar MRI, etc. and the further growth of tumors has not been observed.

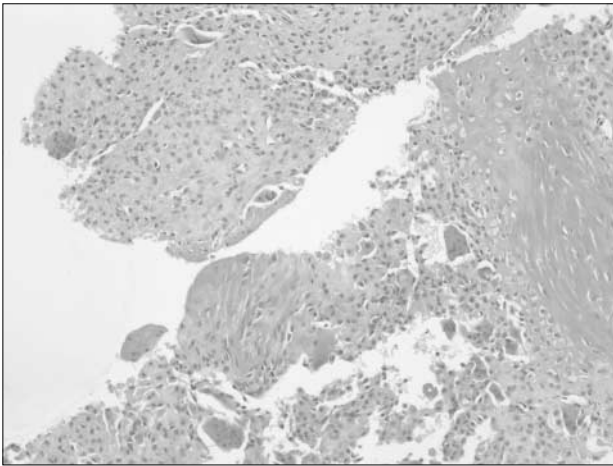


Fig. 4. Histopathological findings tissue from L-spine CT guided bone Biopsy. Round to poly gonal cells, round to ovoid nuclei, osteoclastic giant cells (H&E staining, $\times 40$).

Discussion

Chondroblastoma is a rare benign cartilaginous bone tumor consisting of 1% of the entire bone tumors, and the average onset age is 10~20 years. Chondroblastoma is formed by chondroblast that is primitive cells of the epiphyseal cartilaginous lamina, and because of it, it is developed frequently in the epiphysis of long bones, and although rare, it is developed in small tubular bone of upper and lower extremities in some cases (11,12). On X-ray, together with metaphyseal distension and sclerotic margin, the result of the osteolysis of the epiphysis of long bones may be shown. On T1-weighted image of MRI, it appears as low signal intensities, and on T2-weighted image, it appears as diverse signal intensities. Some low signal intensities detected on T2-weighted images are associated with the volume of immature cartilaginous stroma and the cellularity of chondroblasts. On T2-weighted images, it is required to differentiate from enchondroma, osteochondroma, and well-differentiated osteosarcoma that show high signal intensities, clear cell chondrosarcoma shows characteristics similar to chondroblastomas and shows diverse signal intensities on T2-weighted images, and thus it may be difficult to differentiate from them (13). Histological results show relatively undifferentiated hypercellular tissues with round or polygonal cartilaginous

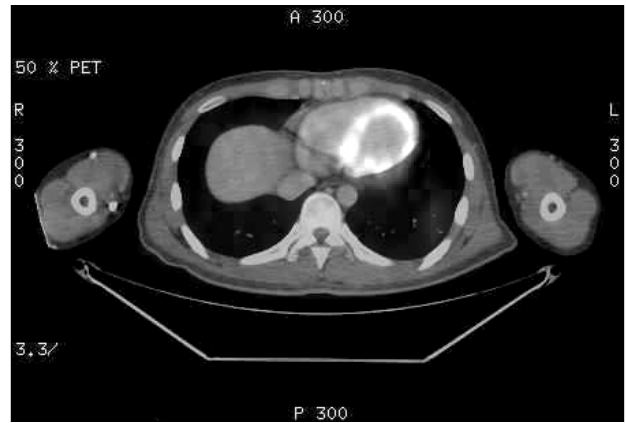


Fig. 5. PET-CT shows metastatic lung nodules.

interstitium, and histological results were identical regardless of metastasis (7). In addition, rare histological results such as mitotic activity, necrosis, cellular atypia, were observed. However, regardless of such specificity, the course of all diseases was benign with limited local aggressiveness, however, postsurgical local recurrence was reported in some cases. In regard to the metastasis of chondroblastoma, it was investigated by Kunze et al. (3), and in their study, metastatic chondroblastoma was observed in all 7 patients, and among them, even multiple lung metastasis patients were included. The period from the diagnosis of primary tumor to the detection of lung metastasis was average 8.4 years, which is a relatively long time, and their average survival time was 12.3 years. The period from the detection of metastasis to death was average 6.3 years (14). It has been reported that the pathological result of metastatic chondroblastoma is not different from general chondroblastoma, and it is impossible to predict the status of metastasis by pathological findings. Nonetheless, it has been reported that in cases detected tumor emboli in the primary site, the possibility to metastasize is high (14). For cases that tumor emboli are detected, the size of primary tumor is big, developed in flat bones, or invaded soft tissues, aggressive surgical approach is required, and even in cases detected lung metastasis, for good prognosis and complete cure, surgical resection in the metastasized area has been recommended (14). In our case, primary chondroblastoma was detected in the lumbar vertebra, on PET-CT taken to assess metastasis, pulmonary nodules showing FDG uptake were detected, and thus after performing spinal surgery, lung resection was performed simultaneously.

References

1. Kurt AM, Unni KK, Sim FH, McLeod RA. Chondroblastoma of bone. *Hum Pathol.* 1989;20:965-76.
2. Kyriakos M, Land VJ, Penning HL, Parker SG. Metastatic chondroblastoma. Report of a fatal case with a review of the literature on atypical, aggressive, and malignant chondroblastoma. *Cancer.* 1985;55:1770-89.
3. Kunze E, Graewe T, Peitsch E. Histology and biology of metastatic chondroblastoma. report of a case with a review of the literature. *Pathol Res Pract.* 1987;182:113-20.
4. Jambhekar NA, Desai PB, Chitale DA, Patil P, Arya S. Benign metastasizing chondroblastoma: a case report. *Cancer.* 1998;82:675-8.
5. Huvo AG, Higinbotham NL, Marcove RC, O'Leary P. Aggressive chondroblastoma. Review of the literature on aggressive behavior and metastases with a report of one new case. *Clin Orthop Relat Res.* 1977;126:266-72.

6. Kyriakos M, Land VJ, Penning HL, Parker SG. Metastatic chondroblastoma. Report of a fatal case with a review of the literature on atypical aggressive, and malignant chondroblastoma. *Cancer*. 1985;55:1770-89.
7. Aigner T, Loos S, Inwards C, Perris R, Perissinotto D, Unni KK, et al. Chondroblastoma is an osteoid-forming, but not cartilage-forming neoplasm. *J Pathol*. 1999;189:463-9.
8. Akai M, Tateishi A, Machinami R, Iwano K, Asao T. Chondroblastoma of the sacrum. A case report. *Acta Orthop Scand*. 1986;57:378-81.
9. Buraczewski J, Lysakowska J, Rudowski W. Chondroblastoma (Codman's tumour) of the thoracic spine. *J Bone Joint Surg Br*. 1957;39-B:705-10.
10. Hoeffel JC, Brasse F, Schmitt M, Plenat F, Vignaud JM, Czorny A, et al. About one case of vertebral chondroblastoma. *Pediatr Radiol*. 1987;17:392-6.
11. Bertoni F, Unni KK, Beabout JW, Harner SG, Dahlin DC. Chondroblastoma of the skull and facial bones. *Am J Clin Pathol*. 1987;88:1-9.
12. Brien EW, Mirra JM, Ippolito V. Chondroblastoma arising from a non-epiphyseal site. *Skeletal Radiol*. 1995;24:220-2.
13. Jee WH, Park YK, McCauley TR, Choi KH, Ryu KN, Suh JS, et al. Chondroblastoma: MR characteristics with pathologic correlation. *J Comput Assist Tomogr*. 1999;23:721-6.
14. Kunze E, Graewe T, Peitsch E. Histology and biology of metastatic chondroblastoma. Report of a case with a review of the literature. *Pathol Res Pract*. 1987;182:113-23.