

Intraoperative Templating in Lateral Meniscal Allograft Transplantation

Bong-Seok Yang, MD, Nam-Hong Choi, MD*, Byeong-Yeon Kim, MD*

Department of Orthopaedic Surgery, Gwangmyeong Sungae Hospital, Gwangmyeong,

**Department of Orthopaedic Surgery, Eulji Medical Center, Seoul, Korea*

Recently, studies have emphasized the importance of anatomical placement of the lateral meniscal allograft to decrease postoperative extrusion. However, it is infeasible to identify the exact rotation of the allograft during transplantation. We present a patient who underwent a lateral meniscal transplantation using a wire for correct positioning of the allograft. The use of a wire intraoperatively shaped to resemble the contour of the lateral meniscal allograft will aid in more accurate and anatomical graft placement.

Keywords: Lateral meniscus, Meniscal allograft transplantation, Intraoperative template

Meniscal allograft transplantation has been performed to prevent development of arthritic degeneration in meniscus deficient knees. Despite the favorable short-term clinical outcomes, long-term results have been less satisfactory.¹⁾ Verdonk et al.²⁾ reported that follow-up magnetic resonance imaging (MRI) demonstrated partial extrusion of the meniscal allograft in the majority of patients at a minimum follow-up of 10 years. Extrusion of the meniscus is a well-known risk factor for development of osteoarthritis.^{3,4)} Therefore, during every surgical step of the meniscal allograft transplantation, our best efforts have to be focused on prevention of extrusion of the meniscal allograft. Recently published articles emphasized the importance of anatomical placement of the lateral meniscal allograft to decrease postoperative extrusion.^{5,6)} Here, we present a patient who underwent a lateral meniscal transplantation using a wire that was formed to the contour of the allograft for correct graft placement.

CASE REPORT

A 15-year-old girl presented with sudden pain and sense

of giving way of the right knee for 1 week. She underwent total meniscectomy for the lateral meniscus at another hospital 8 years ago. Physical examination showed mild effusion, no joint line tenderness, and negative McMurray test. Her knee was stable and showed a full range of motion. Radiographs and MRI showed a displaced, large osteochondritis dissecans in the lateral femoral condyle. Autogenous osteochondral grafting using multiple plugs was performed immediately, and lateral meniscal transplantation was undertaken 5 years after the osteochondral grafting.

For meniscal transplantation, the patient was positioned supine on the operating table and the right knee was placed in the figure-of-4 position. The size of the meniscal allograft was measured using the radiographic method proposed by Pollard et al.⁷⁾ After thawing the lateral meniscal allograft, redundant soft tissues of the allograft were excised carefully and a 9-mm bony bridge connecting the anterior and posterior horns of the lateral meniscal allograft was prepared. A 1-mm wire was bent along the medial border of the bony bridge and the periphery of the lateral meniscal allograft (Fig. 1). The prepared wire was introduced through the lateral mini-arthrotomy while the patellar tendon was retracted medially. The straight part of the wire was placed along the lateral tibial spine (Fig. 2A). However, some portion of the round part of the wire was extruded from the anterolateral margin of the lateral tibial plateau. The straight part of the wire was moved more medially and rotated internally. The round part of the wire

Received May 7, 2016; Accepted July 25, 2016

Correspondence to: Nam-Hong Choi, MD

Department of Orthopaedic Surgery, Eulji Medical Center, 68 Hangeulbiseok-ro, Nowon-gu, Seoul 01830, Korea

Tel: +82-2-970-8260, Fax: +82-2-973-3024

E-mail: cnh2406@yahoo.com

Copyright © 2016 by The Korean Orthopaedic Association

This is an Open Access article distributed under the terms of the Creative Commons Attribution Non-Commercial License (<http://creativecommons.org/licenses/by-nc/4.0>) which permits unrestricted non-commercial use, distribution, and reproduction in any medium, provided the original work is properly cited.

Clinics in Orthopedic Surgery • pISSN 2005-291X eISSN 2005-4408

was placed accurately along the anterolateral margin of the lateral tibial plateau (Fig. 2B). The direction of the straight portion of the wire was marked with electrocautery. After removal of the wire, a bony trough was made along the marked line using a U-shaped chisel. The rest of the transplantation procedure of the lateral meniscal allograft was done in the usual manner.

At 1 year after surgery, she had no pain or effusion or pain during McMurray test on the right knee. Her Lysholm score was 86 and Tegner activity scale was 4. Fol-

low-up MRI showed low-signal intensity of the midbody of the allograft that was positioned adequately without extrusion (Fig. 3).

DISCUSSION

The anterior horn of the lateral meniscus always blends with the anterolateral bundle of the anterior cruciate ligament.⁸⁾ The posterior horn inserts more centrally than the posterior aspect of the lateral tibial spine. The anterior aspect of the lateral tibial spine can be visualized with a

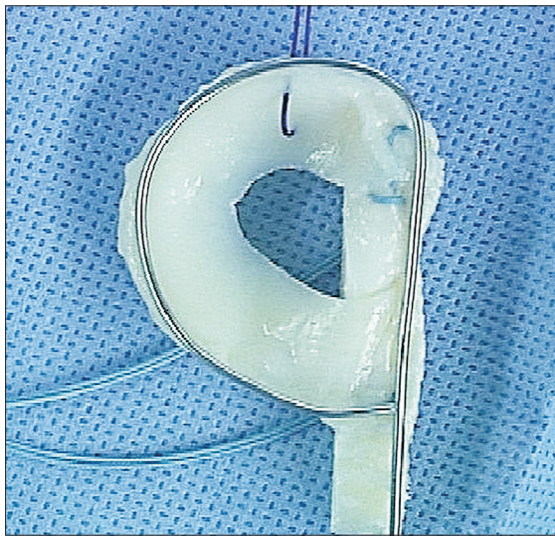


Fig. 1. A 1-mm wire is bent along the medial border of the bony bridge and the periphery of the allograft. An absorbable suture is placed on the posterior horn and two nonabsorbable sutures are placed on the bony bridge of the allograft.

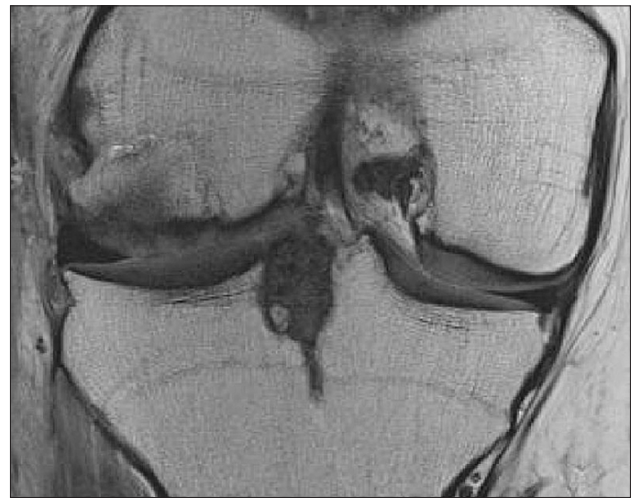

Fig. 3. The midbody of the lateral meniscal allograft showed no extrusion on coronal magnetic resonance imaging and the previous osteochondritis dissecans lesion was covered satisfactorily with the autogenous osteochondral graft.

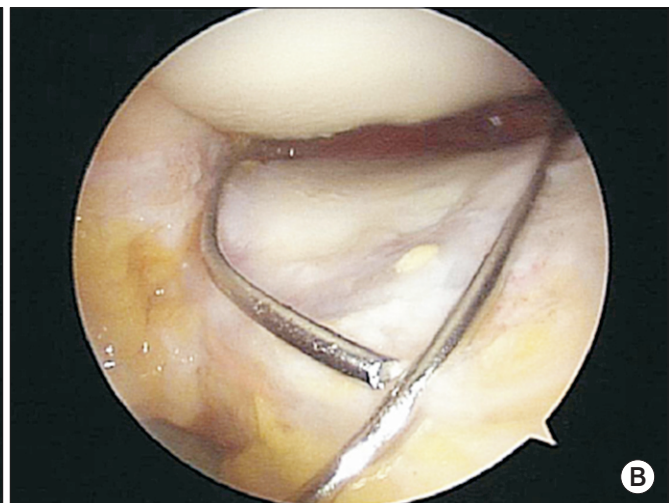
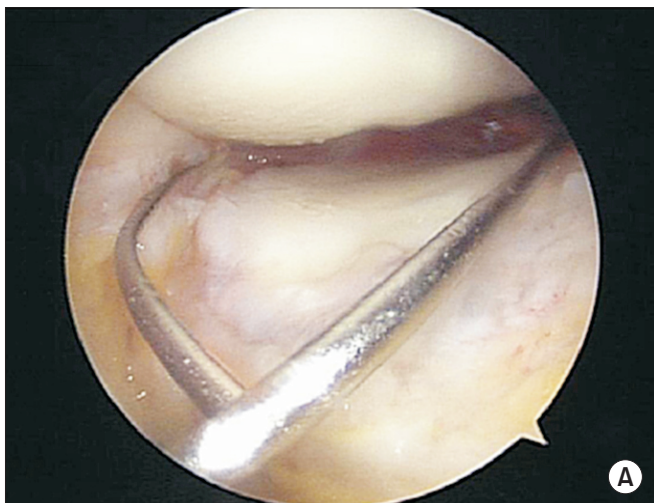


Fig. 2. (A) The straight part of the wire is placed along the lateral tibial spine. (B) The straight part of the wire is moved more medially and rotated internally.

mini-arthrotomy. However, the posterior aspect of the lateral tibial spine can be barely seen, because it is mostly obscured by the anterior cruciate ligament.⁹⁾ Anatomic complexity of the insertions of the horns of the lateral meniscus can lead to a relatively lateralized transplantation of the meniscal allograft. It is also impossible to know the exact rotation of the allograft during transplantation even under the fluoroscopic control. A recent study demonstrated that an externally rotated keyhole of the graft is a factor responsible for midbody extrusion.⁶⁾ The technique described in this report using a wire that is shaped

to conform to the contour of the lateral meniscal allograft will help surgeons to place the graft more accurately and anatomically. For this technique, however, the use of a thin wire should be avoided to prevent distortion during insertion via a mini-arthrotomy.

CONFLICT OF INTEREST

No potential conflict of interest relevant to this article was reported.

REFERENCES

1. Hommen JP, Applegate GR, Del Pizzo W. Meniscus allograft transplantation: ten-year results of cryopreserved allografts. *Arthroscopy*. 2007;23(4):388-93.
2. Verdonk PC, Verstraete KL, Almqvist KF, et al. Meniscal allograft transplantation: long-term clinical results with radiological and magnetic resonance imaging correlations. *Knee Surg Sports Traumatol Arthrosc*. 2006;14(8):694-706.
3. Berthiaume MJ, Raynauld JP, Martel-Pelletier J, et al. Meniscal tear and extrusion are strongly associated with progression of symptomatic knee osteoarthritis as assessed by quantitative magnetic resonance imaging. *Ann Rheum Dis*. 2005;64(4):556-63.
4. Gale DR, Chaisson CE, Totterman SM, Schwartz RK, Gale ME, Felson D. Meniscal subluxation: association with osteoarthritis and joint space narrowing. *Osteoarthritis Cartilage*. 1999;7(6):526-32.
5. Choi NH, Yoo SY, Victoroff BN. Position of the bony bridge of lateral meniscal transplants can affect meniscal extrusion. *Am J Sports Med*. 2011;39(9):1955-9.
6. Lee DH, Kim JM, Lee BS, Kim KA, Bin SI. Greater axial trough obliquity increases the risk of graft extrusion in lateral meniscus allograft transplantation. *Am J Sports Med*. 2012;40(7):1597-605.
7. Pollard ME, Kang Q, Berg EE. Radiographic sizing for meniscal transplantation. *Arthroscopy*. 1995;11(6):684-7.
8. Kohn D, Moreno B. Meniscus insertion anatomy as a basis for meniscus replacement: a morphological cadaveric study. *Arthroscopy*. 1995;11(1):96-103.
9. Johnson DL, Swenson TM, Livesay GA, Aizawa H, Fu FH, Harner CD. Insertion-site anatomy of the human menisci: gross, arthroscopic, and topographical anatomy as a basis for meniscal transplantation. *Arthroscopy*. 1995;11(4):386-94.