

The Floating Upper Limb: Multiple Injuries Involving Ipsilateral, Proximal, Humeral, Supracondylar, and Distal Radial Limb

Qazi Manaam, MS, Adil Bashir, MS, Adnan Zahoor, MS,
Taseem A. Mokhdomi, PhD*, Qazi Danish, PhD*.[†]

Government Bone & Joint Hospital, Srinagar,

**Department of Biotechnology, University of Kashmir, Srinagar,*

[†]Multi-Disciplinary Research Unit, Government Medical College, Srinagar, India

Floating arm injury represents a common yet complicated injury of the childhood severely associated with limb deformation and even morbidity, if not precisely addressed and credibly operated. Here, we report a rare floating upper limb case of a 9-year-old boy with multiple injuries of ipsilateral proximal humeral, supracondylar and distal radial limb. This is the first report to document such a combined floating elbow and floating arm injury in the same limb. In this report, we discuss the surgical procedures used and recovery of the patient monitored to ascertain the effectiveness of the method in limb reorganisation.

Keywords: *Humeral fractures, Multiple trauma, Kirschner wires*

Supracondylar fracture of the humerus is a common childhood injury. The morbidity of this injury is related to a lesser degree to the fracture itself but results more often from associated injuries. The incidence of a supracondylar fracture with an ipsilateral forearm bone fracture, known as floating arm injury, is a very rare paediatric injury and has been reported to occur in 2% to 13% of children. This combined injury has been termed floating elbow in view of the fact that the elbow is completely dissociated from the rest of the upper limb. There are relatively few case reports in the literature on an ipsilateral supracondylar fracture associated with a proximal humeral fracture, the so called floating arm injury. We describe the case of a 9-year-old boy who had a combination of the above-mentioned injuries in the ipsilateral limb. To the best of our knowledge, this is the only case report of a combined floating elbow and floating arm injury in the same limb.

CASE REPORT

A 9-year-old boy was brought to the emergency ward of Government Hospital for Bone and Joint Surgery in Srinagar 7 hours after the trauma of a fall from a tree (10 m high) onto an outstretched hand with the forearm pronated and the wrist hyperextended. The boy complained of severe pain in the right upper limb. The right elbow, proximal part of the right arm, and the right distal forearm were swollen and tender with a palpable crepitus. There was a 3-cm laceration over the anterior aspect of the right elbow. The hand was well-perfused (red and warm). Distal neurovascular status was normal. Pulses could be felt at radial and ulnar nerves. Movement of fingers and thumb was precise. Roentgenograms demonstrated a displaced fracture at the proximal humeral metaphyseal-diaphyseal junction, with an extension (Gartland type III) supracondylar humeral fracture with a Salter-Harris type II physeal injury of the distal forearm (Fig. 1). All injuries were found in the right upper limb. His upper extremity was splinted using a Cramer wire splint extending right from the tip of the shoulder to the fingertips, and a cuff and collar bandage was applied.

Under general anaesthesia, debridement of the

Received November 23, 2015; Accepted February 19, 2016

Correspondence to: Qazi Danish, PhD

Multi-Disciplinary Research Unit, Government Medical College, Jammu and Kashmir 190010, Srinagar, India

Tel: +91-194-245-3114, Fax: +91-194-245-3114

E-mail: qazi.danish@gmail.com

Copyright © 2016 by The Korean Orthopaedic Association

This is an Open Access article distributed under the terms of the Creative Commons Attribution Non-Commercial License (<http://creativecommons.org/licenses/by-nc/4.0>) which permits unrestricted non-commercial use, distribution, and reproduction in any medium, provided the original work is properly cited.

Clinics in Orthopedic Surgery • pISSN 2005-291X eISSN 2005-4408

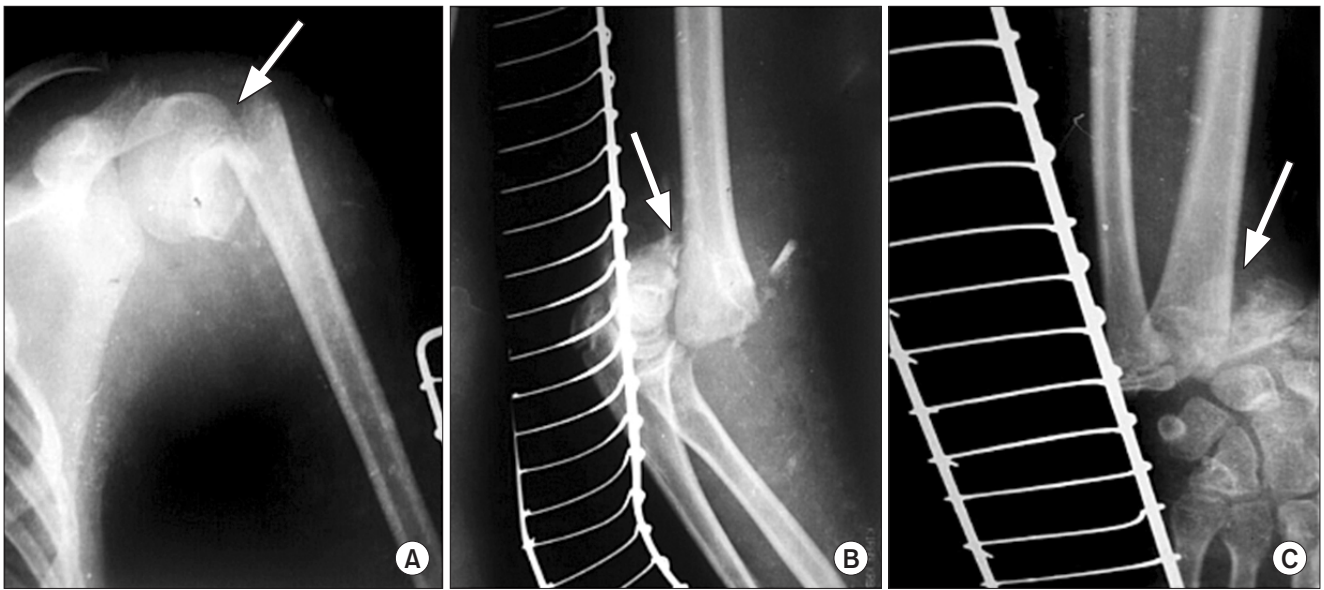


Fig. 1. Floating upper limb. X-rays showing injury of the ipsilateral humeral (A), supracondylar (B), and distal radial limb (C; 7 hours post injury). Each arrow indicates the point of injury.

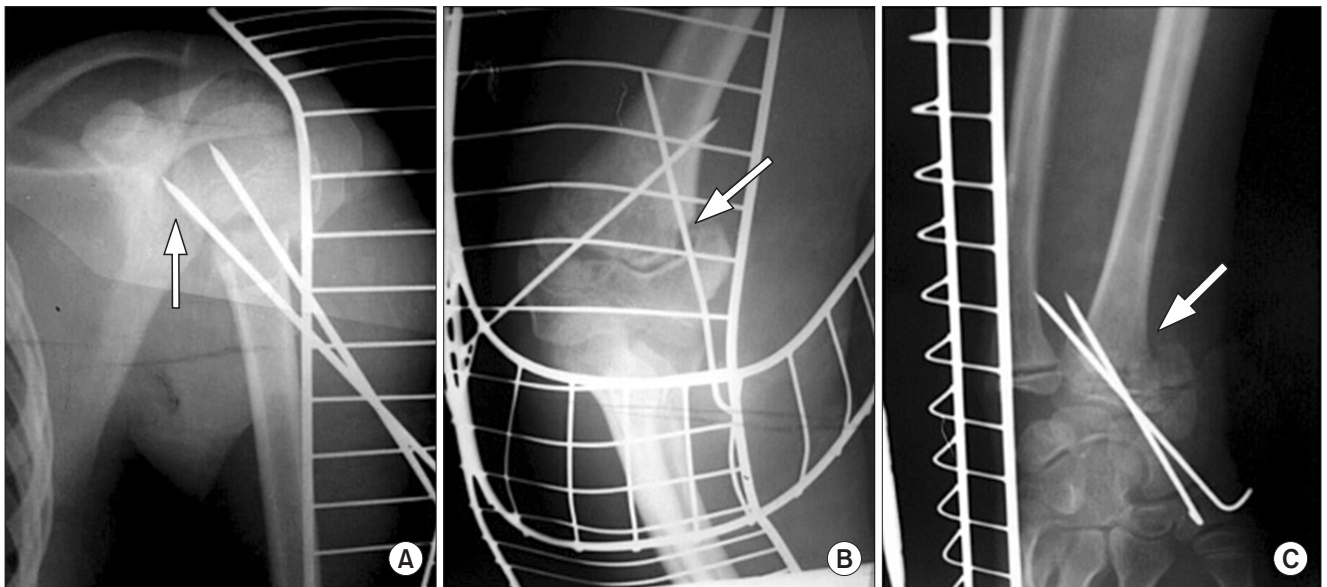


Fig. 2. X-rays showing reunion of the limb at 6 weeks after surgery in the ipsilateral humeral (A), supracondylar (B), and distal radial limb (C). Each arrow indicates the point of injury.

Gustilo-Anderson type II open supracondylar fracture of the humerus was done, and it was copiously irrigated with normal saline. Open reduction of the fracture was done. Reduction was stabilized using 2 lateral Kirschner wires. Next, under fluoroscopic control, closed reduction of the proximal humeral fracture was done using a temporary Kirschner wire. The Kirschner wire was driven from lateral to medial in the humeral shaft and used as a joystick.

Reduction was stabilized using 2 Kirschner wires. Lastly, closed reduction of the distal forearm injury was done, and the radial physeal injury was stabilized using 2 lateral Kirschner wires. All the Kirschner wires were left protruding from the skin and covered with a sterile dressing. After completion of the surgical procedure, a long plaster of Paris splint extending right from the tip of the shoulder to the fingertips was applied, and an arm pouch was given.

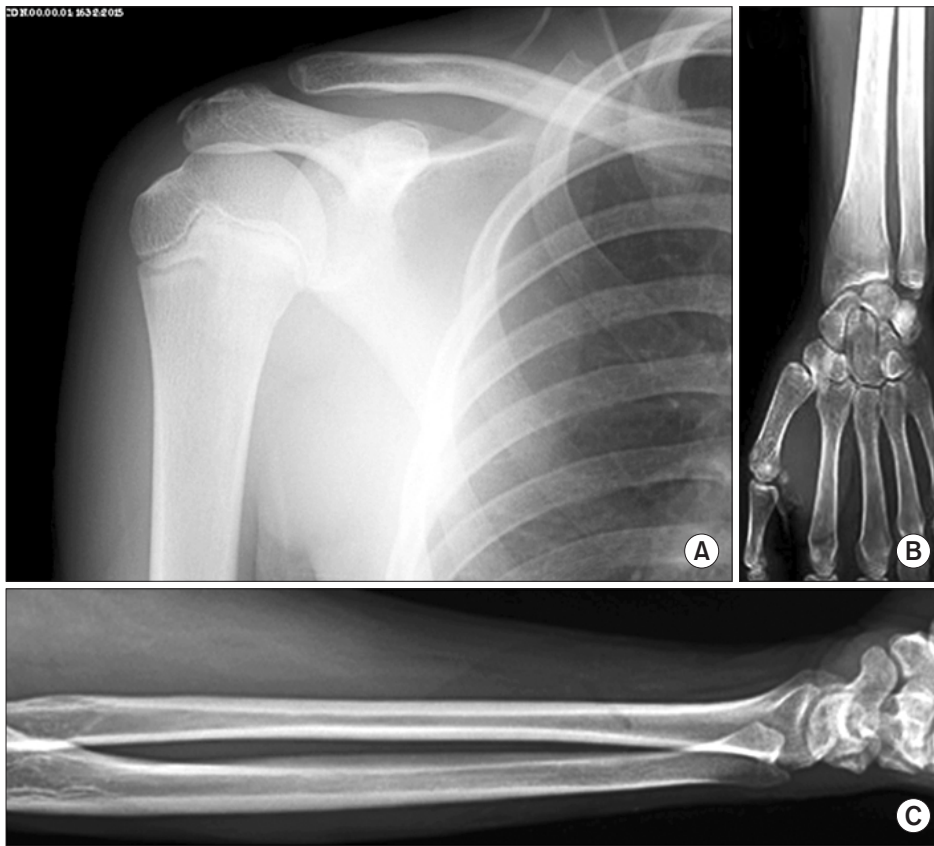


Fig. 3. Final follow-up X-rays showing no observable deformity of the limb at 6 months after discharge. (A) Ipsilateral humerus. (B) Distal radial limb. (C) Supracondylar limb.

The wound over the elbow healed uneventfully and delayed primary closure was done. The Kirschner wires were removed 4 weeks after radiological confirmation of healing or reunion. It took almost 6 weeks for reunion to be observed (Fig. 2). A splint was provided to support the hand and forearm movement, which was followed by range of motion exercises that began 1 week after the use of the splint support. A 6-month follow-up was scheduled. The patient achieved a full wrist, elbow extension/flexion of 0°–130° and pronation/supination, and normal shoulder range of motion when measured with a hand-held goniometer, and had no functional deficits (Fig. 3).

DISCUSSION

Various descriptive terms have been used to describe a combination of upper limb injuries at different sites. The “floating elbow” describes a combination of ipsilateral forearm and supracondylar fractures.^{1,2)} The term “floating arm” refers to a rare injury, describing a combination of ipsilateral supracondylar and proximal humeral fractures.^{3–5)} To the best of our knowledge, this is the first case report in English literature describing a combination of an ipsilat-

eral floating arm and a floating elbow, which resulted from a fall from height. The intensity of trauma was so severe as to result in 3 level upper limb injuries in the patient. Various authors have recommended that the supracondylar fracture should be fixed before other injuries because of the much greater risk of complications associated with this fracture.^{4,5)} In our case, we used the method described by Parmaksizoglu et al.⁶⁾ of using a temporary Kirschner wire as a reducing joystick to aid in closed reduction of the proximal humeral fracture. The distal radial fracture was reduced in a closed manner with traction at the fingers and counter-traction at the level of the forearm. The swelling and the less than adequate traction and counter-traction precluded perfect reduction of the distal radial physal injury; however, this was considered acceptable due to the remaining growth and distal nature of the physal injury.

In conclusion, this is the first report of a floating upper limb, a combination of a floating elbow and a floating arm. Due to the severe nature of the injury with the attendant swelling, closed reduction is difficult to achieve. The use of a temporary Kirschner wire in the humeral shaft helps in closed reduction of the proximal humeral injury.

CONFLICT OF INTEREST

No potential conflict of interest relevant to this article was reported.

REFERENCES

1. Stanitski CL, Micheli LJ. Simultaneous ipsilateral fractures of the arm and forearm in children. *Clin Orthop Relat Res*. 1980;(153):218-22.
2. Harrington P, Sharif I, Fogarty EE, Dowling FE, Moore DP. Management of the floating elbow injury in children: simultaneous ipsilateral fractures of the elbow and forearm. *Arch Orthop Trauma Surg*. 2000;120(3-4):205-8.
3. Guven M, Akman B, Kormaz T, Poyanli O, Altintas F. "Floating arm" injury in a child with fractures of the proximal and distal parts of the humerus: a case report. *J Med Case Rep*. 2009;3:9287.
4. Gul A, Sambandam S. Ipsilateral proximal and flexion supracondylar humerus fracture with an associated olecranon fracture in a 4-year-old child: a case report. *Eur J Orthop Surg Traumatol*. 2006;16(3):237-9.
5. James P, Heinrich SD. Ipsilateral proximal metaphyseal and flexion supracondylar humerus fractures with an associated olecranon avulsion fracture. *Orthopedics*. 1991;14(6):713-6.
6. Parmaksizoglu AS, Ozkaya U, Bilgili F, Sayin E, Kabukcuoglu Y. Closed reduction of the pediatric supracondylar humerus fractures: the "joystick" method. *Arch Orthop Trauma Surg*. 2009;129(9):1225-31.