

# Surgical Release of the First Extensor Compartment for Refractory de Quervain's Tenosynovitis: Surgical Findings and Functional Evaluation Using DASH Scores

Hyun-Joo Lee, MD, Poong-Taek Kim, MD\*, Iman Widya Aminata, MD<sup>†</sup>,  
Han-Pyo Hong, MD, Jong-Pil Yoon, MD, In-Ho Jeon, MD<sup>‡</sup>

*Department of Orthopaedic Surgery, Kyungpook National University Hospital, Kyungpook National University School of Medicine, Daegu,*

*\*Department of Orthopaedic Surgery, Daegu Park Hospital, Daegu, Korea,*

*<sup>†</sup>Department of Orthopaedic Surgery, Fatmawati National General Hospital, Jarkarta, Indonesia,*

*<sup>‡</sup>Department of Orthopedic Surgery, Asan Medical Center, University of Ulsan College of Medicine, Seoul, Korea*

**Background:** Few studies have evaluated surgical outcomes in patients with refractory de Quervain's disease using validated outcome measures. We assessed the clinical outcomes of dorsal release of the first extensor compartment for the treatment of de Quervain's disease using the disabilities of the arm, shoulder and hand (DASH) score.

**Methods:** From October 2003 to May 2009, we retrospectively evaluated 33 patients (3 men and 30 women) who underwent surgical treatment for de Quervain's disease. All patients had a positive Finkelstein test and localized tenderness over the first dorsal compartment. All operations were performed under local anesthesia. A 2-cm-long transverse skin incision was made over the first extensor compartment and the dorsal retinaculum covering the extensor pollicis brevis was incised longitudinally. Preoperative and postoperative clinical evaluation included the use of DASH score, Finkelstein test, and visual analogue scale (VAS) score.

**Results:** In 18 patients (55%), the extensor pollicis brevis tendon compartment was separated from the abductor pollicis longus compartment. Eight patients had intracompartmental ganglia in the extensor pollicis brevis subcompartment. All patients except one had negative sign on Finkelstein test at the last follow-up. The average VAS score decreased from 7.42 preoperatively to 1.33 postoperatively ( $p < 0.05$ ), and DASH score was improved from 53.2 to 3.45 ( $p < 0.05$ ). There were no postoperative complications such as subluxation of the tendon of the first dorsal compartment or injury to the sensory branch of the radial nerve.

**Conclusions:** Intracompartment ganglia and the separate septum of extensor pollicis brevis are often related to de Quervain's disease. The release of the first extensor compartment for refractory de Quervain's disease resulted in good clinical outcomes with minimal morbidity.

**Keywords:** *De Quervain disease, Tenosynovitis, Surgery, Function, Disability evaluation*

Received April 19, 2013; Accepted April 6, 2014

Correspondence to: In-Ho Jeon, MD

Department of Orthopaedic Surgery, Asan Medical Center, University of Ulsan College of Medicine, 88 Olympic-ro 43-gil, Songpa-gu, Seoul 138-736, Korea

Tel: +82-2-3010-3896, Fax: +82-2-488-7877

E-mail: jeonchoi@gmail.com

De Quervain's disease was first recognized in 1895 as a stenosing tenosynovitis of the abductor pollicis longus (APL) and the extensor pollicis brevis (EPB) within the first extensor compartment of the wrist, formed by the radius and dorsal carpal ligaments<sup>1-3)</sup> rather than inflammation.<sup>4)</sup> As pathology specimens demonstrate collagen disorientation and mucoid change,<sup>5,6)</sup> it may be more appropriate to regard de Quervain's disease as tendinosis rather than tendinitis. However, the natural history and pathophysiology

Copyright © 2014 by The Korean Orthopaedic Association

This is an Open Access article distributed under the terms of the Creative Commons Attribution Non-Commercial License (<http://creativecommons.org/licenses/by-nc/3.0>) which permits unrestricted non-commercial use, distribution, and reproduction in any medium, provided the original work is properly cited.

Clinics in Orthopedic Surgery • pISSN 2005-291X eISSN 2005-4408

of de Quervain's disease remain incompletely understood.

If splint immobilization, physiotherapy, and rehabilitation fail to resolve the symptoms, the disease might be treated by steroid injections into the tendon sheath. However, time to symptom resolution after corticosteroid injection<sup>7)</sup> may take at most 18 months. Further, repeated steroid injections may cause potential complications such as atrophy of the subcutaneous tissue. Thus, referral for surgery such as decompression of the first dorsal compartment is recommended for patients who do not respond to repeated steroid injections<sup>8)</sup> or who have symptoms persisting for longer than 6 months after nonsurgical treatments.<sup>9)</sup>

We assessed the clinical outcomes of releasing the first extensor compartment for the treatment of de Quervain's disease using the disabilities of the arm, shoulder and hand (DASH) score in a group of patients with refractory de Quervain's disease.

## METHODS

### Patients

Between October 2003 and May 2009, we evaluated 33 patients (3 men and 30 women) who were treated with surgical treatment for refractory de Quervain's disease. The medical records of these patients were retrospectively reviewed. All patients presented with clinical signs and symptoms of de Quervain's disease, which included positive Finkelstein tests, localized tenderness over the first dorsal compartment, and positive sign on active EPB extension test. In this active EPB extension test, the patient was asked to abduct the thumb and extend the metacarpophalangeal joint, and induction or aggravation of pain over the first compartment was determined as positive.

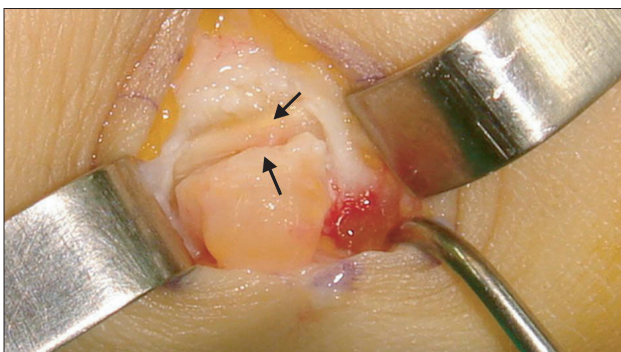
We defined the disease refractory when symptoms persisted for longer than 3 months after injection of 0.1

mL betamethasone and 0.4 mL 1% (w/v) lidocaine once or twice, or when symptoms recurred after repeated injection more than three times.

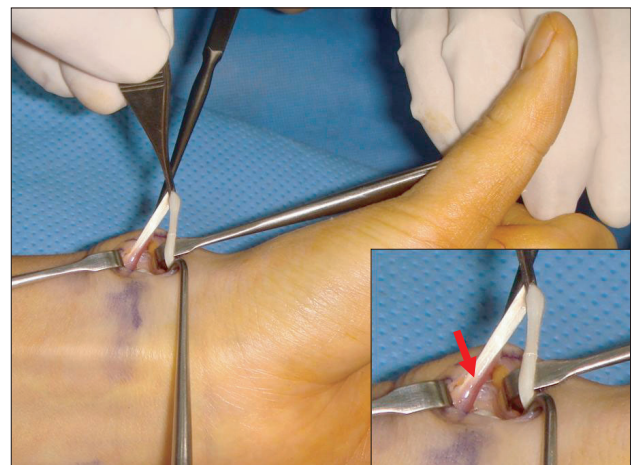
Of the 33 patients, 31 had unilateral and 2 had bilateral de Quervain's disease. The mean age of the patients included in this study was 37.6 years (range, 26 to 44 years) for men and 51.6 years (range, 30 to 67 years) for women. Four patients had associated diseases in the same upper extremity, which are one carpal tunnel syndrome, two cubital tunnel syndromes and one lateral epicondylitis. However de Quervain's disease at those cases was developed after the other diseases were cured. The mean duration of follow-up was 28.4 months (range, 18 to 39.5 months). All operations were performed by a single senior surgeon and intra-operative findings were recorded. We collected clinical data of Finkelstein test, DASH score,<sup>10)</sup> and overall and night visual analogue scale (VAS) pain score before operation and at the final follow-up.

### Surgical Technique

All operations were performed in the day surgery unit, under local anesthesia using intravenous midazolam and pethidine. A mixture of 0.1% (w/v) lidocaine and 0.25% (w/v) bicarbonate was injected into the area of skin incision and a pneumatic tourniquet was inflated. A 2-cm-long transverse skin incision was made over the first extensor compartment of the radial styloid process. Great care was taken to identify and retract the radial sensory nerve branches. The EPB tendon was exposed and identified just distal to the first extensor compartment. After lifting the EPB tendon, the extensor retinaculum covering the EPB subcompartment was incised longitudinally along



**Fig. 1.** The extensor retinaculum is incised longitudinally along the extensor pollicis brevis tendon.

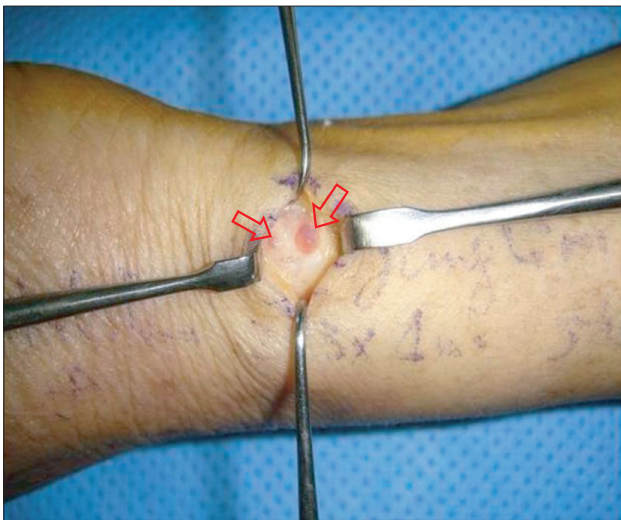

**Fig. 2.** Any entanglement was double-checked by pulling and lifting up the tendon distally.

the EPB tendon (Fig. 1) on its dorsal side. If there was a septum between the EPB and APL tendons, the septum was incised longitudinally. Any entanglement was double-checked by pulling and lifting up the tendon distally (Fig. 2). When we found a ganglion from the tendon sheath, we removed the mass from the tendon sheath without excision of the tendon sheath. After meticulous hemostat control, the skin was closed and a compressive dressing was applied. No immobilization was performed.

### Statistical Analysis

Paired *t*-test was used to compare the preoperative and postoperative clinical examination parameters with SPSS ver. 17.0 (SPSS Inc., Chicago, IL, USA). A *p*-value of < 0.05 was considered to be statistically significant.



**Fig. 3.** A dorsal ganglion over the extensor pollicis brevis tendon sheath.

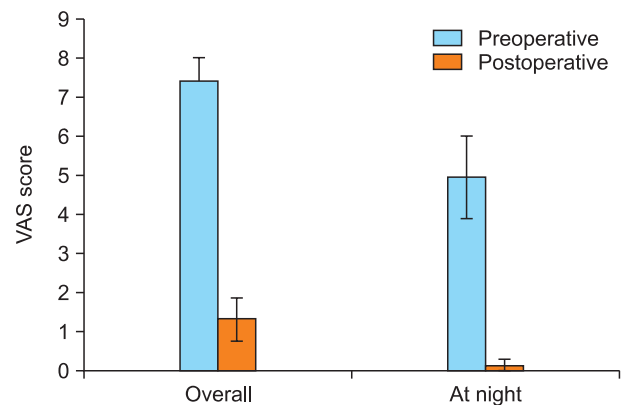
## RESULTS

### Surgical Findings

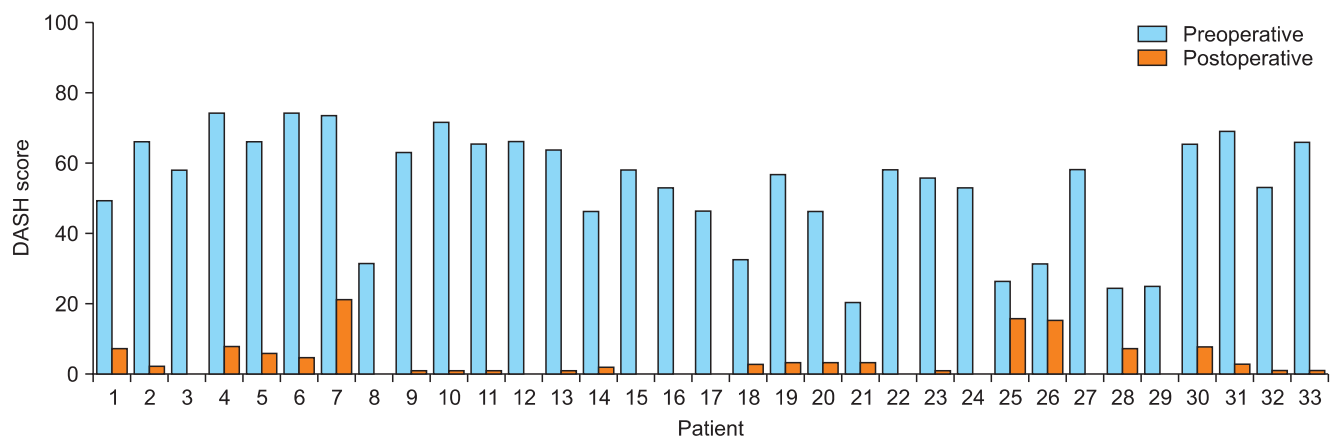
In 18 patients (55%), the EPB tendon compartment was separated from the APL compartment. A thick retinaculum and neovascularization of the tendon sheath were noted. The EPB tendon was easily identified by its dorsal location to the APL tendon and relatively distal musculotendinous junction compared to that of the APL tendon. We also identified small ganglia from the tendon sheaths of eight patients (Fig. 3). These ganglia were removed from the sheath at the time of release. The diseases were treated by operation before the index surgery.

### Clinical Outcomes and Complications

Only one patient showed a positive sign of Finkelstein test at the last follow-up. However, this patient reported that the symptom severity decreased after surgery. Although the patient had mild pain, the hand functioned normally.



**Fig. 4.** Visual analogue scale (VAS) score of overall pain and pain at night.



**Fig. 5.** Preoperative and postoperative disabilities of the arm, shoulder and hand (DASH) score.

All returned to normal daily activities.

We found that the average VAS pain score significantly decreased, from 7.42 before surgery to 1.33 at the final follow-up ( $p < 0.05$ ). Individuals with pain during night showed a decrease in VAS score from 5 preoperatively to 0.15 postoperatively ( $p < 0.05$ ) (Fig. 4). The DASH score also decreased from 53.2 to 3.45 ( $p < 0.05$ ) (Fig. 5).

There was no postoperative infection or subluxation of the tendon of the first extensor compartment when an active thumb extension or flexion was tested. No injury to the sensory branch of the radial nerve, adhesion between sensory branches and the fascia, scar hypertrophy or wound dehiscence was noted.

## DISCUSSION

We achieved excellent clinical outcome in terms of pain relief with minimal complication using a dorsal release of the first extensor compartment for the treatment of refractory de Quervain's disease. There was no subluxation or instability of the tendon after the index surgery. Because of troublesome complication of tendon subluxation,<sup>11)</sup> complete excision of the tendon sheath is not recommended anymore.<sup>12)</sup> Instead of complete excision, several methods were reported to prevent tendon subluxation.<sup>12,13)</sup> But these methods cannot warrant the release of APL tendon if the pathology is on the side of APL.<sup>14)</sup> Because releasing the dorsal aspect of the first extensor compartment does not violate the volar side that contains the APL tendon, we also could prevent volar subluxation of the tendons. Moreover, direct inspection is possible from the incision, we probably do not need preoperative ultrasonogram. If the septum exists, it can be incised from the dorsal side.

Several studies on the long-term results of surgical release of the first extensor compartment have been reported.<sup>15)</sup> However, those reports have limitations by their small number of patients. Moreover, no study evaluated the results using validated scoring system, which was applied in our study. The DASH developed by "Upper Extremity Collaborative Group"<sup>10)</sup> is considered as a reliable outcome measure in pathology of upper extremities<sup>16)</sup> and is widely accepted. Regarding the pain relief, this pro-

cedure provided good pain relief, which was effective for both overall and night pain.

One interesting finding was ganglia over the first extensor compartment in eight patients. There have been few reports in the literature reporting this ganglion.<sup>17)</sup> Even though we cannot know the cause-and-effect relationship between the ganglia and de Quervain's disease, we can speculate the association between the ganglion and de Quervain's disease by the incidence of ganglion. After resection of these ganglia, the symptoms disappeared and there was no recurrence case at the final clinical follow-up.

The septum in the first extensor compartment we identified in this study was also of interest, because the EPB tendon sheath was separated from the APL in over half of the patients' cohort. This thick retinaculum may be related to the symptoms of de Quervain's disease.

Our study has limitations. First, the study is limited by its retrospective, non-comparative nature. Second, we had four patients with other upper extremity disease that can affect DASH and VAS score. However, we included the cases after the other diseases were cured. We consider the effect on the result was minimal.

In summary, ganglia over the first extensor compartment and the separate septum of EPB are often related to de Quervain's disease. Dorsal release of first extensor compartment for refractory de Quervain's disease resulted in good clinical outcome with minimal morbidity.

## CONFLICT OF INTEREST

No potential conflict of interest relevant to this article was reported.

## ACKNOWLEDGEMENTS

This work was supported by the Global Frontier R&D Program on Human-Centered Interaction for Coexistence funded by the National Research Foundation of Korea grant funded by the Korean Government (NRF-M1AXA003-2011-0028358). This work was attributed to Kyungpook National University Hospital.

## REFERENCES

1. Clarke MT, Lyall HA, Grant JW, Matthewson MH. The histopathology of de Quervain's disease. *J Hand Surg Br.* 1998; 23(6):732-4.
2. de Quervain F. On a form of chronic tendovaginitis. (Translated article: *Cor-Bl.f.schweiz. Aerzte* 1895;25:389-94). *J Hand Surg Br.* 2005;30(4):388-91.
3. Kay NR. De Quervain's disease. Changing pathology or changing perception? *J Hand Surg Br.* 2000;25(1):65-9.



4. Green DP, Hotchkiss RN, Pederson WC, Wolfe SW, eds. *Green's operative hand surgery*. 5th ed. New York: Elsevier, Churchill-Livingstone; 2005.
5. Sawaizumi T, Nanno M, Ito H. De Quervain's disease: efficacy of intra-sheath triamcinolone injection. *Int Orthop*. 2007;31(2):265-8.
6. Zingas C, Failla JM, Van Holsbeeck M. Injection accuracy and clinical relief of de Quervain's tendinitis. *J Hand Surg Am*. 1998;23(1):89-96.
7. McKenzie JM. Conservative treatment of de Quervain's disease. *Br Med J*. 1972;4(5841):659-60.
8. Witt J, Pess G, Gelberman RH. Treatment of de Quervain tenosynovitis: a prospective study of the results of injection of steroids and immobilization in a splint. *J Bone Joint Surg Am*. 1991;73(2):219-22.
9. Capasso G, Testa V, Maffulli N, Turco G, Piluso G. Surgical release of de Quervain's stenosing tenosynovitis postpartum: can it wait? *Int Orthop*. 2002;26(1):23-5.
10. Hudak PL, Amadio PC, Bombardier C. Development of an upper extremity outcome measure: the DASH (disabilities of the arm, shoulder and hand). The Upper Extremity Collaborative Group (UECG). *Am J Ind Med*. 1996;29(6):602-8.
11. White GM, Weiland AJ. Symptomatic palmar tendon subluxation after surgical release for de Quervain's disease: a case report. *J Hand Surg Am*. 1984;9(5):704-6.
12. Littler JW, Freedman DM, Malerich MM. Compartment reconstruction for De Quervain's disease. *J Hand Surg Br*. 2002;27(3):242-4.
13. Yuasa K, Kiyoshige Y. Limited surgical treatment of de Quervain's disease: decompression of only the extensor pollicis brevis subcompartment. *J Hand Surg Am*. 1998;23(5):840-3.
14. Maruyama M, Takahara M, Kikuchi N, Ito K, Watanabe T, Ogino T. De Quervain disease caused by abductor pollicis longus tenosynovitis: a report of three cases. *Hand Surg*. 2009;14(1):43-7.
15. Scheller A, Schuh R, Honle W, Schuh A. Long-term results of surgical release of de Quervain's stenosing tenosynovitis. *Int Orthop*. 2009;33(5):1301-3.
16. Jester A, Harth A, Wind G, Germann G, Sauerbier M. Disabilities of the arm, shoulder and hand (DASH) questionnaire: Determining functional activity profiles in patients with upper extremity disorders. *J Hand Surg Br*. 2005;30(1):23-8.
17. Tan MY, Low CK, Tan SK. De Quervain's tenosynovitis and ganglion over first dorsal extensor retinacular compartment. *Ann Acad Med Singapore*. 1994;23(6):885-6.