

# A Comparison of Conventional Ultrasonography and Arthrosonography in the Assessment of Cuff Integrity after Rotator Cuff Repair

Kwang Won Lee, MD, Dae Suk Yang, MD, Tong Jin Chun, MD\*,  
Kyoung Wan Bae, MD, Won Sik Choy, MD, Hyeon Jong Park, MD<sup>†</sup>

Departments of Orthopedic Surgery and \*Radiology, Eulji University College of Medicine, Daejeon,

<sup>†</sup>Department of Orthopedic Surgery, Yeonmu Hospital, Nonsan, Korea

**Background:** This study was designed to perform conventional ultrasonography, magnetic resonance arthrography (MRA) and arthrosonography exams after rotator cuff repair to compare the results of conventional ultrasonography and arthrosonography with those of MRA as the gold standard.

**Methods:** We prospectively studied 42 consecutive patients (14 males, 28 females; average age, 59.4 years) who received arthroscopic rotator cuff repair due to full-thickness tears of the supraspinatus tendon from 2008 to 2010. The integrity assessment of the repaired rotator cuff was performed 6 months postoperatively using conventional ultrasonography, MRA, and arthrosonography.

**Results:** The diagnostic accuracy of the conventional ultrasonography compared to MRA was 78.6% and the McNemar test results were 0.016 in full-thickness tear and 0.077 in partial-thickness tear. The diagnostic accuracy of arthrosonography compared to MRA was 92.9% and the McNemar test results were 0.998 in full-thickness tear and 0.875 in partial-thickness tear.

**Conclusions:** It was found that the integrity assessment of the repaired rotator cuff by ultrasonography must be guarded against and that arthrosonography is an effective alternative method in the postoperative integrity assessment. Also, an arthrosonography seems to be a suitable modality to replace the conventional ultrasonography.

**Keywords:** Shoulder, Rotator cuff retear, Ultrasonography, Arthrosonography

Because the integrity of repaired rotator cuff is closely related to the functional results of patients,<sup>1-3)</sup> its accurate determination can have important implications for the management of postoperative shoulder pain. There are several methods to evaluate rotator cuff integrity before and after repair including ultrasonography,<sup>4-9)</sup> multidetector computed tomographic arthrography (CTA),<sup>1,10)</sup> magnetic resonance imaging (MRI),<sup>1,2,11-13)</sup> magnetic resonance arthrography (MRA),<sup>14)</sup> and second look arthroscopy.<sup>5)</sup> Of them,

ultrasonography is recognized as a simple and relatively accurate method for the detection of rotator cuff integrity. However, it is difficult to identify the integrity of the rotator cuff after a surgery with ultrasonography because bone and soft tissue ultrasonographic landmarks around the tendon become distorted or absent and tendons are hyper-echoic which leads to further difficulties in the diagnosis of recurrent rotator cuff tears.<sup>4,9,15)</sup> Furthermore, it may not be possible to accurately identify the integrity of the rotator cuff with ultrasonography if the ends of torn rotator cuffs are not retracted or a gap in the tear is not filled with synovial fluid.<sup>16)</sup> We thought the sonography could be combined with arthrography (arthrosonography) to overcome those disadvantages. This technique was reported in previous studies.<sup>16-18)</sup> However, to our knowledge, there has been no report on comparing the results between

Received August 19, 2013; Accepted November 13, 2013

Correspondence to: Dae Suk Yang, MD

Department of Orthopedic Surgery, Eulji University College of Medicine,  
95 Dunsanse-ro, Seo-gu, Daejeon 302-799, Korea

Tel: +82-42-611-3271, Fax: +82-42-259-1289

E-mail: yds123@eulji.ac.kr

Copyright © 2014 by The Korean Orthopaedic Association

This is an Open Access article distributed under the terms of the Creative Commons Attribution Non-Commercial License (<http://creativecommons.org/licenses/by-nc/3.0>) which permits unrestricted non-commercial use, distribution, and reproduction in any medium, provided the original work is properly cited.

Clinics in Orthopedic Surgery • pISSN 2005-291X eISSN 2005-4408

conventional ultrasonography and arthrosonography in assessing the repaired cuff integrity. Therefore, the present study was designed to compare the repaired cuff integrity measured by two methods. The hypothesis of the present study was that arthrosonography would provide a higher accuracy in detecting the integrity of the repaired rotator cuff than conventional ultrasonography.

## METHODS

This prospective study was carried out on 42 patients of 148 patients who underwent arthroscopic rotator cuff repair between 2008 and 2010. Approval was obtained from Eulji University Hospital's Institutional Review Board. The determination of the necessary sample size was made according to the reported accuracy of ultrasonography in previous studies. Taking into consideration the fact that the accuracy of ultrasonography and MRA in rotator cuff tear has been reported to range between 70% and 98%,<sup>5,12,14,19,20)</sup> our statistical analysis showed that at least 42 patients had to be enrolled in this study in order to see a difference of 14% (the approximate middle of the reported range of 28%) between equivalent groups with a sufficient power of 0.8 and an alpha value of 0.05. Following patients were included: those who received arthroscopic repair of the rotator cuff due to full-thickness tears and were willing to undergo a shoulders examination at six months postoperatively. Following patients were excluded: patients with partial rupture of the supraspinatus tendon or only rupture of the subscapularis tendon, concomitant disorders such as glenohumeral arthritis, fracture, osteonecrosis or labral pathology and those who received an open or revision surgery on the rotator cuff and had a severe limitation of motion in the shoulder after surgery. Fourteen men and 28 women were included. The mean age of the patients was 59.4 years (range, 44 to 82 years) at the time of surgery with 26 cases in the right shoulder and 16 cases in the left shoulder. All 42 patients were diagnosed with full-thickness tear of the rotator cuff by clinical assessment and MR imaging. The arthroscopic findings of all patients showed full-thickness tears of the supraspinatus tendon, 5 cases were combined with tears of the infraspinatus tendon and 22 cases were combined with tear of the subscapularis tendon. The extent of tears was intraoperatively determined under direct arthroscopic visualization after debridement of the degenerated tendon edges. The tear size was measured in anterior-posterior dimension using a calibrated probe introduced through the posterior portal while viewing from the lateral portal. According to the classification of DeOrto and Cofield,<sup>21)</sup> the tear size was classified into

small-sized, medium-sized or large-sized/massive. The arthroscopic findings showed small-sized tears in 7 shoulders (16.7%), medium-sized tears in 19 (45.2%), and large-sized/massive tears in 16 (38.1%). All patients underwent completed arthroscopic rotator cuff repairs using suture bridging technique by the senior author. All of them used an abduction brace for 4 weeks after the operation and started pendulum exercises on the first operative day. At first, they performed passive range of motion in a tolerable range since 3 days after operation. No active motion was allowed for 4 to 6 weeks or until passive motion had been completely recovered. Gradual full active motion was instituted starting at 4 to 6 weeks and muscle strengthening exercises followed for 3 to 6 months.

## Study Design and Imaging Technique

The rotator cuff repair integrity was assessed by conventional ultrasonography and arthrosonography 6 months after arthroscopic repair. MRA was used as standard in the comparison of conventional ultrasonography and arthrosonography because it was difficult to perform a second look arthroscopy in all patients. Also, MRA has the advantage that is possible to provide multiplanar imaging of the postoperative shoulder. The six months' time reference point for the examination of cuff integrity was selected based on a previous study that described sufficient tendon healing and rehabilitation of the shoulder occur at 6 months postoperatively.<sup>22)</sup>

First, conventional ultrasonography was performed by the orthopedic surgeon. Following the conventional ultrasonography, a single arthrography using a contrast medium was performed by a musculoskeletal specialized radiologist with the patient in supine position on a fluoroscopic table. The authors used contrast medium instead of fluid to perform MRA and arthrosonography by a single injection. A 22-gauge spinal needle was inserted with fluoroscopic guidance into the glenohumeral joint. After that, the intra-articular location of the needle tip was confirmed with a few drops of contrast medium injection. The contrast medium consisted of the following content: 5 mL of Telebrix (Guerbet, Aulnay-Sous-Bois, France), 5 mL of Lidocaine (Huons, Hwaseong, Korea), 10 mL of normal saline (JW Pharmaceutical, Seoul, Korea), 0.1 mL of Magnevist (Bayer Schering Pharma AG, Berlin, Germany) and 0.45 mL of 1:1,000 epinephrine. After confirming the needle tip being inserted into the joint space, the contrast medium was injected until the joint was fully expanded. The average volume of the injected contrast medium was 15.2 mL (range, 7 to 30 mL). After the contrast medium was injected, the shoulder joint was gently exercised fol-

lowed by MRA. After finishing the MRA as quickly as possible, an arthrosonography was immediately conducted by the orthopedic surgeon. The time until arthrosonography was on average 66 minutes (range, 30 to 100 minutes) after contrast medium injection in line with the previous study that reported the usefulness of arthrosonography.<sup>23)</sup> The results were categorized into intact, partial and full-thickness tears. In this study, a partial tear on the articular side of rotator cuff only was considered as partial-thickness tear because a bursa side partial-thickness tear may be not influenced by arthrography. The results of conventional ultrasonography and arthrosonography were compared with those of MRA.

In addition, 17 volunteers among 42 patients participated in an intraobserver reliability test using the conventional and arthrosonography one week after they performed the assessment of rotator cuff integrity.

#### **Ultrasonography and Diagnostic Criteria**

Conventional ultrasonography and arthrosonography were conducted both before and after arthrography using a Philips iU22 scanner with a linear 12-MHz transducer (Philips Medical Systems, Andover, MA, USA) by two board certified orthopedic surgeons specialized in shoulder arthroscopy. Both of them had performed more than approximately 300 scans prior to the start of this study. Patients were placed in a sitting position on a stool without back support, and the ultrasonography was performed on the patient's back-side by two orthopedic surgeons. In order to assess the integrity of the supraspinatus tendon, the patients were asked to extend and also internally rotate their shoulder by flexing the elbow joint and placing the hand on the iliac wing. The transducer was oriented paral-

lel to the tendon in order to visualize the fibers in a longitudinal plane. Also the transducer was rotated 90° in order to examine the tendons in the transverse plane.

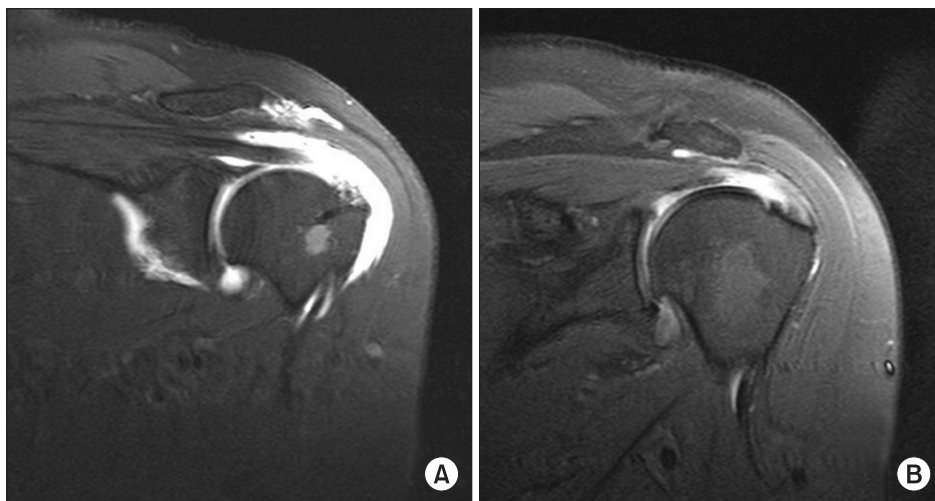
The diagnostic criteria for full-thickness rotator cuff tear<sup>5)</sup> were as follows: the rotator cuff could not be visualized because of retraction under the acromion, there was focal defect in the rotator cuff and the torn cuff was retracted in a variable degree from the surgical trough. The diagnostic criteria for partial-thickness tear were as follows: distinct hypoechoic or mixed hyperechoic and hypoechoic defects were visualized in both longitudinal and transverse plane at the deep articular side of the rotator cuff (an articular-side partial-thickness tear). A thinned cuff or one with a subtle concave contour was considered to be intact in the absence of a focal defect.

#### **MRA Diagnostic Criteria**

All MRA examinations were obtained through a 1.5-T scanner (Sonata, Siemens Medical System, Erlangen, Germany) by using routine pulse sequences. As reported by Gusmer et al.<sup>12)</sup> and Magee et al.,<sup>13)</sup> the MRA diagnosis of full-thickness tear of the rotator cuff was based on the fluid signal transversing full-thickness of the tendon (Fig. 1A), and the MRA diagnosis of partial-thickness tear of the rotator cuff was based on the fluid transversing portion of the tendon whether on the articular side but not transversing full-thickness of the tendon (Fig. 1B). The interpretations of MRA were performed by a musculoskeletal specialized radiologist.

#### **Intraobserver and Interobserver Reliability**

Intraobserver and interobserver variability in the conventional ultrasonography and arthrosonography measure-



**Fig. 1.** (A) The oblique coronal T1-weighted image of magnetic resonance arthrography (MRA) with fluid signal transversing full-thickness of the tendon shows a full-thickness tear of the rotator cuff. (B) The oblique coronal T1-weighted image of MRA with a fluid transversing portion of the articular side of the tendon shows a partial-thickness tear of the rotator cuff.

ments was assessed with intraclass correlation coefficients (ICCs). Because the ICC shows the rate of variation between different data, the variability was evaluated using 2 measurements by 1 examiner (intraobserver; interval between the 2 measurements at least 1 week) and measurements by 2 examiners (interobserver; double blinded). Examiners were two orthopedic surgeons. An ICC greater than 0.90 was considered to represent a good level of agreement.

### Statistical Analysis

A cross tabulation was prepared to compare the results of conventional ultrasonography and arthrosonography with those of the MRA. The predictive values (sensitivity, specificity, positive predictive value, and negative predictive value) of conventional ultrasonography and arthrosonography for full-thickness tears and partial-thickness

tears were compared with MRA. McNemar tests were used to analyze for significant differences comparing the results of conventional ultrasonography and MRA or arthrosonography and MRA. The diagnostic accuracy values were evaluated with 95% confidence interval (CI) level of significance. All collected data were statistically analyzed using SPSS ver. 18.0 (SPSS Inc., Chicago, IL, USA). For all tests, a *p*-value (McNemar test value) of less than 0.05 was considered significant.

## RESULTS

The intraclass correlation coefficient for the intraobserver reliability of the measurements on the conventional ultrasonography was 0.93 (95% CI, 0.87 to 0.96) for the first author and 0.96 (95% CI, 0.92 to 0.98) for the second author. On arthrosonography, it was 0.95 (95% CI, 0.91 to 0.97) for the first author and 0.95 (95% CI, 0.90 to 0.97) for the second author. On the conventional ultrasonography, the ICC for the interobserver reliability of the measurements by the two examiners was 0.93 (95% CI, 0.88 to 0.96) and on the arthrosonography 0.94 (95% CI, 0.88 to 0.97).

Table 1 compares the findings of conventional ultrasonography and arthrosonography with those of MRA in the assessment of the integrity of a repaired rotator cuff. The diagnostic accuracy of conventional ultrasonography, compared with MRA as the gold standard was 78.6% (33 matching cases out of 42 cases). Its specificity for the detection of rotator cuff retear was 100% in full-thickness tear, 85.7% in partial-thickness tear, and 95.7% in both. However, its sensitivity was 50% in full-thickness, 71.4%

**Table 1.** Conventional Ultrasonography and Arthrosonography vs. MRA Findings in the Assessment of Rotator Cuff Integrity

MRA	Conventional ultrasonography			Arthrosonography		
	FTT	PTT	No tear	FTT	PTT	No tear
FTT	6	4	2	11	1	0
PTT	0	5	2	0	6	1
No tear	0	1	22	0	1	22

MRA: magnetic resonance arthrography, FTT: full-thickness tear, PTT: partial-thickness tear.

**Table 2.** Sensitivity, Specificity, and Predictive Values of Conventional Ultrasonography and Arthrosonography Compared with Magnetic Resonance Arthrography

Type of RCT	Sensitivity	Specificity	Positive predictive value	Negative predictive value
Conventional ultrasonography				
FTT	50.0	100.0	100.0	83.3
PTT	71.4	85.7	50.0	93.7
Both	78.9	95.7	93.75	84.6
Arthrosonography				
FTT	91.7	100.0	100.0	96.8
PTT	85.7	94.3	75.0	97.1
Both	94.7	95.7	94.7	95.7

Values are presented as percentage.

RCT: rotator cuff tear, FTT: full-thickness tear, PTT: partial-thickness tear.



in partial-thickness, and 78.9% in both. The diagnostic accuracy of arthrosonography, also compared with MRA as the gold standard, was 92.9% (39 matching cases out of 42 cases). Its specificity for the assessment of integrity of the repaired rotator cuff was 100% in full-thickness tear, 94.3% in partial-thickness tear, and 95.7% in both. And its sensitivity was 91.7% in full-thickness tear, 85.7% in partial-thickness tear, and 94.7% in both (Table 2).

Comparing the results between conventional sonography and MRA, there was a significant difference in full-thickness tear ( $p = 0.016$ ), but no significant difference in partial-thickness tear ( $p = 0.774$ ). On the other hand, comparing the results between arthrosonography and MRA, there were no significant differences in full-thickness ( $p = 0.998$ ) and partial-thickness tear ( $p = 0.875$ ). According to those results, the arthrosonography was more helpful than conventional sonography in the assessment of the repaired cuff integrity.

## DISCUSSION

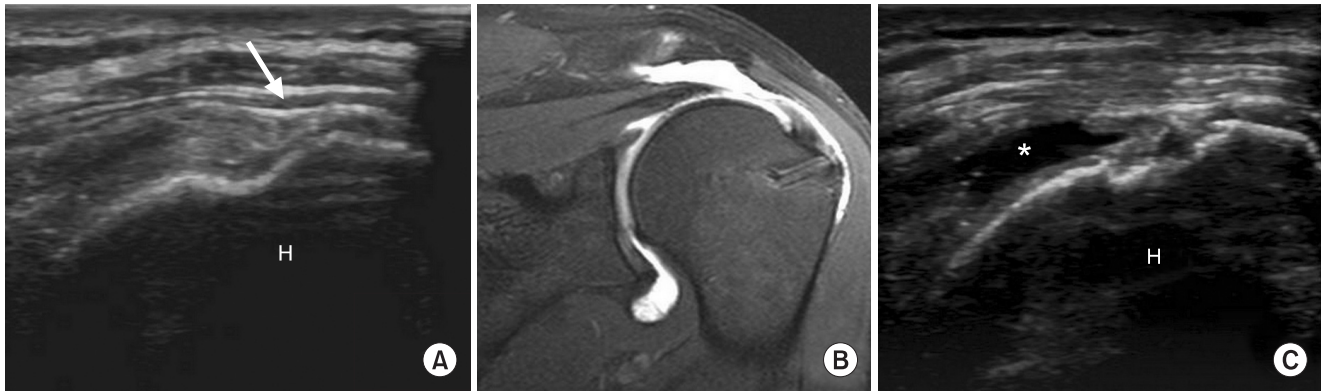
The assessment of the repaired rotator cuff integrity is important in the follow-up management after rotator cuff repair. For its assessment, a secondary look arthroscopy would be the most accurate. However, considering the time, costs and need for local, regional or general anesthesia, it is impossible in the reality to conduct this examination in all patients who received rotator cuff repair. Therefore, we performed imaging evaluations for the assessment of the integrity of repaired rotator cuff instead of a second look arthroscopy. There are various methods for assessing the integrity of the repaired rotator cuff including arthrography, ultrasonography, multidetector CTA, MRI and MRA. Of them, arthrography was reported to provide substantial false-positive results following rotator cuff repair because contrast medium may leak through an incompletely healed but well repaired rotator cuff and have substantial false-negative results because contrast medium may fail to leak from the joint because of scar tissue despite tear.<sup>21)</sup> The multidetector CTA is known to have some advantages compared with MRI and ultrasonography and it shows a high accuracy.<sup>10,24)</sup> However, it may be impossible to perform multidetector CTA in patients due to the radiation exposure whenever patients visit to hospital. MRI (or MRA) has been accepted as the most useful examination tool.<sup>12)</sup> It has a greater sensitivity and specificity compared to ultrasonography and arthrography, especially in the assessment of full-thickness or articular side partial-thickness tears.<sup>13,25-27)</sup> However, MRA (or MRI) is very expensive and time-consuming compared with conventional

ultrasonography and arthrosonography and it is inefficient and difficult to conduct MRA as primary assessment method for the integrity of repaired rotator cuff. In comparison, ultrasonography is known to have a high accuracy for evaluating the integrity of the rotator cuff before and after operations on shoulder and it is widely used to assess the integrity of repaired rotator cuff<sup>5,6,28-30)</sup> because of its inexpensive, noninvasive, well tolerated, and timely fashion with immediate results. However, there has been a variable degree of sensitivity and specificity of preoperative and postoperative ultrasonography from 50% to 100%.<sup>5-9)</sup> Furthermore, it may be difficult to accurately identify the cuff integrity with ultrasonography if the ends of torn rotator cuffs are not retracted or a gap in the tear is not filled with synovial fluid.<sup>16)</sup> In order to overcome these shortcomings of ultrasonography, we conceived the technique of ultrasonography after the distention of the glenohumeral joint.

In the present study, the conventional sonography was useful for only evaluating the articular side partial-thickness tear of the rotator cuff after an operation on the shoulder. However, the arthrosonography was a highly reliable method for assessing the integrity of the repaired rotator cuff. After the repair, tissues of cuff torn were filled with a thin fibrous and bursal tissue and inelastic tissue. Therefore, torn tendon ends were left with immobile scar.<sup>21)</sup> The conventional ultrasonography detected six full-thickness tears as four partial-thickness and two no tears and the arthrosonography only detected one full-thickness tear as a partial-thickness tear in our study (Table 1). We think full-thickness tears were assessed as partial-thickness and no tears by immobile cuff scar, consisting of fibrous and inelastic tissue. Because the joint was distended and torn tendon ends were separated by the intra-articular injection of contrast medium, the full-thickness tear was assessed as itself by arthrosonography as a result (Fig. 2). We think that an arthrosonography may be helpful in evaluating a full-thickness tear of the rotator cuff after cuff repair.

The current study had some limitations. It was impossible to compare results of conventional ultrasonography and arthrosonography with those of the secondary arthroscopy. In addition, it was not possible to identify between retear and residual defect on repaired rotator cuff that were categorized as full-thickness tear or partial-thickness tear in all of the imaging modalities. However, this study was able to describe relatively accurate comparisons of conventional ultrasonography and arthrosonography with MRA because the MRA showed the most comparable anatomical structure of shoulder among all imaging modalities.

In conclusion, an arthrosonography demonstrates a



**Fig. 2.** (A) Although the longitudinal image of conventional ultrasonography after arthroscopic rotator cuff repair demonstrates a focal flattening of the convexity of the supraspinatus tendon (arrow), this finding could not confirm the diagnosis of full-thickness tear of the rotator cuff. (B) On an oblique coronal T1-weighted image of magnetic resonance arthrography, the repaired rotator cuff shows the full-thickness tear of the supraspinatus tendon and increased effusion of the subacromial space. (C) On a longitudinal image of arthrosonography, the repaired rotator cuff shows a full-thickness tear of the supraspinatus tendon and an increased effusion of the subacromial space (asterisk). H: humeral head.

comparable diagnostic consistency with MRA. Therefore, we think the assessment of integrity of the repaired rotator cuff by ultrasonography must be guarded against and an arthrosonography may be an effective alternative method in the postoperative assessment of rotator cuff integrity. Also it seems to be a suitable modality to replace the con-

ventional ultrasonography.

### CONFLICT OF INTEREST

No potential conflict of interest relevant to this article was reported.

### REFERENCES

- Boileau P, Brassart N, Watkinson DJ, Carles M, Hatzidakis AM, Krishnan SG. Arthroscopic repair of full-thickness tears of the supraspinatus: does the tendon really heal? *J Bone Joint Surg Am.* 2005;87(6):1229-40.
- Gerber C, Fuchs B, Hodler J. The results of repair of massive tears of the rotator cuff. *J Bone Joint Surg Am.* 2000;82(4):505-15.
- Sugaya H, Maeda K, Matsuki K, Moriishi J. Repair integrity and functional outcome after arthroscopic double-row rotator cuff repair: a prospective outcome study. *J Bone Joint Surg Am.* 2007;89(5):953-60.
- Crass JR, Craig EV, Feinberg SB. Sonography of the postoperative rotator cuff. *AJR Am J Roentgenol.* 1986;146(3):561-4.
- Prickett WD, Teefey SA, Galatz LM, Calfee RP, Middleton WD, Yamaguchi K. Accuracy of ultrasound imaging of the rotator cuff in shoulders that are painful postoperatively. *J Bone Joint Surg Am.* 2003;85(6):1084-9.
- Teefey SA, Hasan SA, Middleton WD, Patel M, Wright RW, Yamaguchi K. Ultrasonography of the rotator cuff: a comparison of ultrasonographic and arthroscopic findings in one hundred consecutive cases. *J Bone Joint Surg Am.* 2000;82(4):498-504.
- Mack LA, Matsen FA 3rd, Kilcoyne RF, Davies PK, Sickler ME. US evaluation of the rotator cuff. *Radiology.* 1985;157(1):205-9.
- Miniati A, Salonen D. Rotator cuff evaluation: imaging and diagnosis. *Orthop Clin North Am.* 1997;28(1):43-58.
- Mack LA, Nyberg DA, Matsen FR 3rd, Kilcoyne RF, Harvey D. Sonography of the postoperative shoulder. *AJR Am J Roentgenol.* 1988;150(5):1089-93.
- Oh JH, Kim SH, Ji HM, Jo KH, Bin SW, Gong HS. Prognostic factors affecting anatomic outcome of rotator cuff repair and correlation with functional outcome. *Arthroscopy.* 2009;25(1):30-9.
- Bishop J, Klepps S, Lo IK, Bird J, Gladstone JN, Flatow EL. Cuff integrity after arthroscopic versus open rotator cuff repair: a prospective study. *J Shoulder Elbow Surg.* 2006;15(3):290-9.
- Gusmer PB, Potter HG, Donovan WD, O'Brien SJ. MR imaging of the shoulder after rotator cuff repair. *AJR Am J Roentgenol.* 1997;168(2):559-63.

13. Magee TH, Gaenslen ES, Seitz R, Hinson GA, Wetzel LH. MR imaging of the shoulder after surgery. *AJR Am J Roentgenol.* 1997;168(4):925-8.
14. Duc SR, Mengiardi B, Pfirrmann CW, Jost B, Hodler J, Zanetti M. Diagnostic performance of MR arthrography after rotator cuff repair. *AJR Am J Roentgenol.* 2006;186(1):237-41.
15. Harryman DT 2nd, Mack LA, Wang KY, Jackins SE, Richardson ML, Matsen FA 3rd. Repairs of the rotator cuff: correlation of functional results with integrity of the cuff. *J Bone Joint Surg Am.* 1991;73(7):982-9.
16. Lee HS, Joo KB, Park CK, et al. Sonography of the shoulder after arthrography (arthrosonography): preliminary results. *J Clin Ultrasound.* 2002;30(1):23-32.
17. Seltzer SE, Finberg HJ, Weissman BN, Kido DK, Collier BD. Arthrosonography: gray-scale ultrasound evaluation of the shoulder. *Radiology.* 1979;132(2):467-8.
18. Seltzer SE, Finberg HJ, Weissman BN. Arthrosonography: technique, sonographic anatomy, and pathology. *Invest Radiol.* 1980;15(1):19-28.
19. Iannotti JP, Ciccone J, Buss DD, et al. Accuracy of office-based ultrasonography of the shoulder for the diagnosis of rotator cuff tears. *J Bone Joint Surg Am.* 2005;87(6):1305-11.
20. Teefey SA, Rubin DA, Middleton WD, Hildebolt CF, Leibold RA, Yamaguchi K. Detection and quantification of rotator cuff tears: comparison of ultrasonographic, magnetic resonance imaging, and arthroscopic findings in seventy-one consecutive cases. *J Bone Joint Surg Am.* 2004;86(4):708-16.
21. DeOrto JK, Cofield RH. Results of a second attempt at surgical repair of a failed initial rotator-cuff repair. *J Bone Joint Surg Am.* 1984;66(4):563-7.
22. Kamath G, Galatz LM, Keener JD, Teefey S, Middleton W, Yamaguchi K. Tendon integrity and functional outcome after arthroscopic repair of high-grade partial-thickness supraspinatus tears. *J Bone Joint Surg Am.* 2009;91(5):1055-62.
23. Lee HS, Lee KW, Han TI, et al. Arthrosonography of the shoulder joint for evaluation of the glenoid labrum, glenoid rim and humeral head: comparison with conventional ultrasonography and MR arthrography. *J Korean Radiol Soc.* 2003;48(1):69-76.
24. Charousset C, Bellaiche L, Duranthon LD, Grimberg J. Accuracy of CT arthrography in the assessment of tears of the rotator cuff. *J Bone Joint Surg Br.* 2005;87(6):824-8.
25. Knudsen HB, Gelineck J, Sojbjerg JO, Olsen BS, Johannsen HV, Sneppen O. Functional and magnetic resonance imaging evaluation after single-tendon rotator cuff reconstruction. *J Shoulder Elbow Surg.* 1999;8(3):242-6.
26. Ferrari FS, Governi S, Burresi F, Vigni F, Stefani P. Supraspinatus tendon tears: comparison of US and MR arthrography with surgical correlation. *Eur Radiol.* 2002;12(5):1211-7.
27. Waldt S, Bruegel M, Mueller D, et al. Rotator cuff tears: assessment with MR arthrography in 275 patients with arthroscopic correlation. *Eur Radiol.* 2007;17(2):491-8.
28. Levy O, Venkateswaran B, Even T, Ravenscroft M, Copeland S. Mid-term clinical and sonographic outcome of arthroscopic repair of the rotator cuff. *J Bone Joint Surg Br.* 2008;90(10):1341-7.
29. Park JY, Siti HT, Keum JS, Moon SG, Oh KS. Does an arthroscopic suture bridge technique maintain repair integrity?: a serial evaluation by ultrasonography. *Clin Orthop Relat Res.* 2010;468(6):1578-87.
30. Ko SH, Friedman D, Seo DK, Jun HM, Warner JJ. A prospective therapeutic comparison of simple suture repairs to massive cuff stitch repairs for treatment of small- and medium-sized rotator cuff tears. *Arthroscopy.* 2009;25(6):583-89. e4.