

An Anatomic Study on the Overlap Patterns of Structural Components in the Keystone Area in Noses of Koreans

In-Sang Kim, MD · Young-Jun Chung, MD · Young Il Lee, MD¹

Departments of Otorhinolaryngology-Head and Neck Surgery and ¹Anatomy, College of Medicine, Dankook University, Cheonan, Korea

Objectives. The keystone area has critical importance in maintaining the stability of the nasal dorsum. However, overlap patterns between structural components in the keystone area have rarely been studied, especially in the noses of Koreans.

Methods. Dissections were performed on 18 cadaveric noses. The length and width of the structural components in the keystone area were measured. The shape of the caudal margin of the nasal bone and the overlap patterns between the upper lateral cartilage and the nasal bone were classified.

Results. The shape of the caudal margin of the nasal bone were classified as follows: type A, curvilinear margin; type B, paramedian retractions or "M" shape; type C, elongated midline; and type D, retracted midline. The overlap area between the upper lateral cartilage and the nasal bone was classified as follows: type Ao, crescent shape; type Bo, short midline extension; and type Co, long midline extension. The cephalocaudal length of the overlap area between the upper lateral cartilage and the nasal bone was 4-10 mm (mean, 7 mm) in the midline, and 0-7 mm (mean, 3.1 mm) in the paramedian area. The overlap width of the upper lateral cartilage with the nasal bone was 8-14 mm (mean, 9.7 mm).

Conclusion. The overlap pattern of the structural components in the keystone area is variable. Therefore, a thorough understanding and a cautious evaluation of the relationships of these components before and during surgery is important in performing safe and effective nasal procedures.

Key Words. Keystone area, Nasal septum, Nasal bone, Rhinoplasty

INTRODUCTION

The keystone area of the nose is critical for maintaining the structural stability of the nasal dorsum. The keystone area is comprised of the nasal bone (NB), cartilaginous septum (CS), bony septum (BS), and upper lateral cartilages (ULCs). Each component is firmly connected with muco-periosteum, muco-perichondrium, and dense fibrous articulations. When the stability of any component in the keystone area is interrupted during rhinoplasty or septal surgery, the stability of the remaining structures should be pre-

served.

Embryologically, the CS and ULCs have the same origin and they can be considered as a single structural unit, the so-called quadrilateral cartilage (QLC) (1-4). The QLC is overlapped by the NB in variable lengths. The overlapped portion of the QLC and the NB is covered by a continuation of the muco-periosteum and muco-perichondrium, which extend to the entire nasal cavity on both the dorsal and ventral surfaces. Therefore, it is practically impossible to detach the ULCs from the NB with a cephalo-caudal directed force. However, the connection between the QLC and the NB is relatively weak to dorso-ventral forces, making the connection vulnerable to trauma. The connection between the QLC and NB is also easily damaged during rhinoplasty procedures, such as hump resection and osteotomies.

Therefore, the strong connection of the components in the keystone area has been of primary interest for rhinoplasty surgeons. Rorich et al. (5) reported the overlap length of the ULCs under

• Received August 5, 2008

Accepted after revision August 26, 2008

• Corresponding author : In-Sang Kim, MD

Department of Otorhinolaryngology-Head and Neck Surgery, College of Medicine, Dankook University, Dankook University Hospital, 359

Manghyang-ro, Dongnam-gu, Cheonan 330-715, Korea

Tel : +82-41-550-3974, Fax : +82-41-556-1090

E-mail : codoctor@dreamwiz.com

the NB was 6-8 mm, while Daniel (4) reported the overlap length to be 11 mm in the midline and 4 mm at the lateral sides.

Asians tend to have a shorter nasal length, shorter nasal bones, and smaller cartilages compared to Caucasians. However, the overlap patterns of the structural components in the keystone area have rarely been studied in the noses of Asians.

Therefore, we identified the overlap patterns and anatomic variations in the keystone area in noses of Koreans in an effort to ensure safe nasal procedures involving this anatomic area.

MATERIALS AND METHODS

Eighteen cadavers (12 males and 6 females) were used for dissection. The ages at death ranged from 55-70 yr. There were no identifiable nasal or facial deformities or evidence of previous sinonasal surgical procedures in the cadavers. The soft tissues were dissected along the entire nasal dorsum, exposing the NB, ULCs, CS, and lower lateral cartilages. After meticulous removal of the periosteum on the NB, the caudal margin of the NB was inspected and photographed. The caudal margin of the NB was marked on the CS with a marking pen. Then, the caudal portion of the NB was carefully removed using sphenoid punch forceps

in a piecemeal fashion until the entire ULC under the NB was exposed. The bony-cartilaginous junction of the nasal septum was identified under the NB and the distance from the most caudal point of the NB to the bony-cartilaginous junction was measured.

RESULTS

The midline cephalocaudal length of the overlap area between the NB and ULCs was 4-10 mm (average, 7.0 mm), which nearly coincided with the distance from the most caudal point of the NB to the bony-cartilaginous junction of the septum. On the line bisecting the width of the NB on each side, the cephalocaudal overlap length of the NB with the ULCs was 0-7 mm (average, 3.1 mm).

The overlap width of the NB and ULCs was widest at the caudal margin of the NB (range, 8-14 mm; average, 9.7 mm).

The shape of the caudal margin of the NB was classified into four types, as follows: type A, curvilinear margins; type B, "M" shape with paramedian retractions; type C, a caudal extension of the midline over the cartilaginous dorsum; and type D, a cephalic retraction on the midline (Fig. 1, 2). Types A, B, C, and D existed in eight, two, four, and two cadavers respectively, and there were combined patterns in two cadavers (types A+B and A+D). The combined patterns had different types on each side showing asymmetry in the paired NBs.

The shape of the overlap area was classified into three types, as follows: type Ao, a crescent shape with a curvilinear cephalic margin; and types Bo and Co, midline extensions. The types were easily discerned by the average overlap length of 7 mm for all types. Type Bo had a short midline extension, in which the midline was elongated in the cephalic direction by <7 mm. Type Co had a long midline extension in which the midline portion was markedly elongated by >7 mm (Fig. 3). The number of cadavers with types Ao, Bo, and Co was three, four, and nine, respectively, and the combined patterns existed in two cadavers (types Ao+Co and Bo+Co). In the combined patterns, the overlap types were different on the right and left sides.

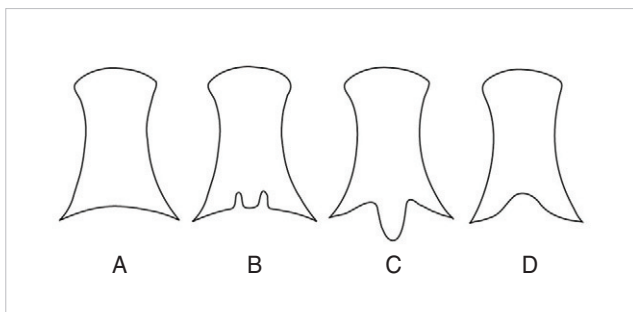


Fig. 1. Classification of the caudal margin of the nasal bone. Type A, curvilinear margin; type B, paramedian retractions or "M" shape; type C, a caudal extension of the midline over the cartilaginous dorsum; and type D, a cephalic retraction on the midline.

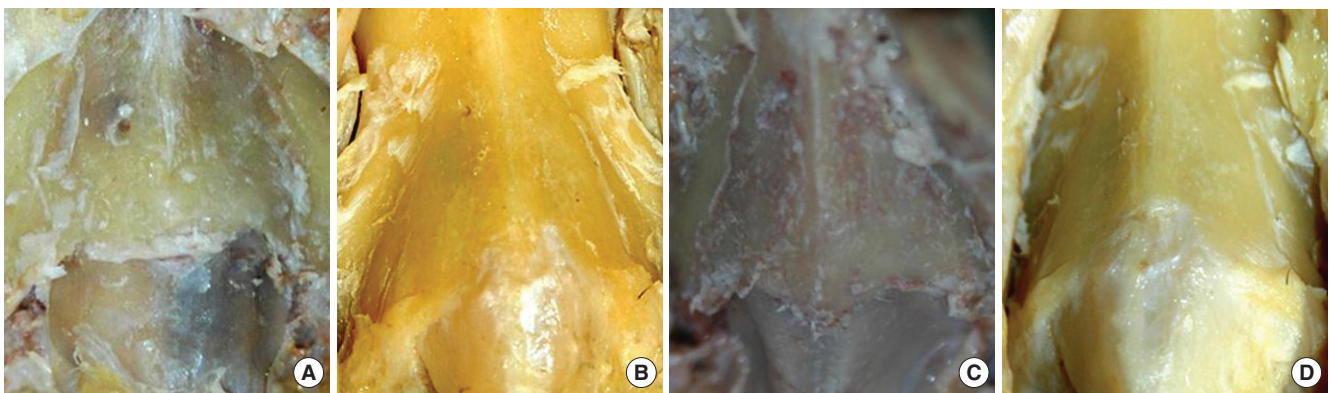


Fig. 2. Types of caudal margin of the nasal bone in cadaver dissections. (A) Type A. (B) Type B. (C) Type C. (D) Type D.

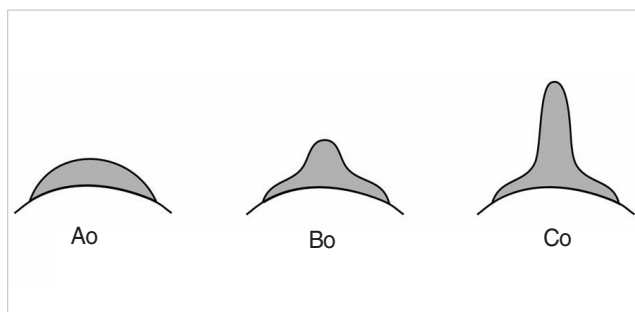


Fig. 3. Classification of the overlap area between the upper lateral cartilages and the nasal bone.

Type Ao, crescent shape; type Bo, short midline extension; and type Co, long midline extension.

DISCUSSION

In a study using 60 adult cadavers, Godley et al. (6) reported the cartilaginous dorsum of the nose was 21 ± 5 mm long, and it was shorter in females by 5 ± 4 mm. It was also reported that the cartilaginous dorsum was overlapped by the NB by 4 ± 2 mm (6).

In our previous study using magnetic resonance imaging, the length of the cartilaginous dorsum was 26 ± 4 mm in adults, and there was no significant difference between genders (7). The overlap length between the NB and CS was 7 ± 2 mm in adults, which decreased with age, possibly due to calcification of CS. In the current study, the midline overlap length of the NB and ULC was 7.0 mm on average, which was similar to the radiologic findings.

In consideration of these findings, if the NB in the rhinion area is removed during hump resection >7 mm from the caudal margin, the overlap between the NB and QLC could be damaged for the most part. In that case, other components of the keystone area should be secured, such as the stability of the septal cartilage itself, the strong connection between the CS and the perpendicular plate of the ethmoid, the overlap between the ULC and the pyriform aperture, and the surrounding soft tissue connections. Even if the overlap between the NB and QLC is severely damaged, a saddle nose would not result if these supports are carefully preserved.

The overlap length between the NB and QLC decreases with age, possibly due to calcification of the septal cartilage. The overlap length also decreases with a decrease in the overall nasal length (7). Rorich et al. (8) reported that elderly people have weaker strength and support of the nasal bone and cartilages. Lam and Williams (9) also reported that in those with short NBs, there is a higher risk of instability in the keystone area during rhinoplasty.

Therefore, for the elderly and the patients with the short nose, very cautious manipulation is necessary in the keystone area because they tend to have a shorter and weaker overlap between the NB and QLC.

In the current study, we determined that ULCs are overlapped under the NB in variable length, width, and shape. This variability of the connection between the ULC, SC, and NB is also increased

by the variable shape of the caudal margin of the NB. Therefore, there might be weaker or stronger combinations of connections. For example, an overlap of a type Ao and a caudal margin of type D would be the weakest form of a connection. In contrast, an overlap involving a type Co and the caudal margin of a type C would be the strongest combination of connections with the largest overlap area.

These anatomic variations may be the cause of different results after aggressive nasal procedures, such as hump resection, osteotomies, and wide septal resection resulting in certain degrees of saddle nose in some patients, while not in other patients.

Therefore, the relationships and overlap patterns of the structural components in the keystone area should be thoroughly evaluated pre- or intra-operatively in individual patients. Preoperatively, the shape of the NB should be examined because the patients with a short nasal bone are known to have a weaker keystone area. Intraoperatively, fine dissection in the proper supraperichondrial plane should be performed to identify the shape of the caudal margin of the NB. The overlap length of the NB with the CS can be evaluated by carefully comparing the position of the caudal end of the NB on the cartilaginous dorsum with the bony-cartilaginous junction of the nasal septum inside.

If there is a risk of weakness or instability, proper management should be performed to secure the structural stability of the components.

CONFLICTS OF INTEREST STATEMENT

The authors had no conflicts of interest with this study.

REFERENCES

1. Charles DB. Phylogenetic aspects and embryology. In: Bulestone CD, Stool SE, Scheetz MD, editors. *Pediatric otolaryngology*. 4th ed. Pennsylvania: Saunders; 2003. 5-7p.
2. van Loosen J, Verwoerd-Verhoef HL, Verwoerd CD. The nasal septal cartilage in the newborn. *Rhinology*. 1988 Sep;26(3):161-5.
3. Sandikcioglu M, Mølsted K, Kjaer I. The prenatal development of the human nasal and vomeral bones. *J Craniofac Genet Dev Biol*. 1994 Apr-Jun;14(2):124-34.
4. Daniel RK. Dorsum. In: Daniel RK. *Rhinoplasty: An atlas of surgical techniques*. New York: Springer; 2005. 23-58p.
5. Rorich RJ, Adams WP, Gunter JP. Advanced rhinoplasty anatomy. In: Gunter JP, Rorich RJ, Adams WP, editors. *Dallas rhinoplasty: Nasal surgery by the masters*. 2nd ed. St. Louis: Quality medical publishing; 2007. 11-29p.
6. Godley FA. Nasal septal anatomy and its importance in septal reconstruction. *Ear Nose Throat J*. 1997 Aug;76(8):498-501, 504-6.
7. Kim IS, Lee MY, Lee KI, Kim HY, Chung YJ. Analysis of the development of the nasal septum according to age and gender using MRI. *Clin Exp Otorhinolaryngol*. 2008 March;1(1):29-34.
8. Rohrich RJ, Hollier LH Jr, Janis JE, Kim J. Rhinoplasty with advancing age. *Plast Reconstr Surg*. 2004 Dec;114(7):1936-44.
9. Lam SM, Williams EF 3rd. Anatomic considerations in aesthetic rhinoplasty. *Facial Plast Surg*. 2002 Nov;18(4):209-14.