

# Safety and efficacy of liquid nitrogen spray cryotherapy-assisted balloon dilation for refractory anastomotic strictures

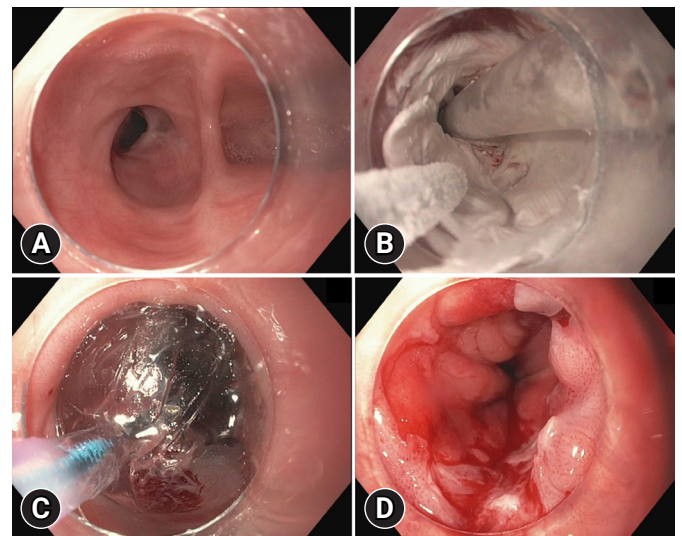
Christopher Adam Bouvette<sup>1</sup>, Ahmad Basel Nasir<sup>1,2</sup>, James Matthew Reinersman<sup>3</sup>, Amir Rumman<sup>4</sup>

Departments of <sup>1</sup>Medicine and <sup>2</sup>Pediatrics, University of Oklahoma College of Medicine, Oklahoma City, OK; <sup>3</sup>Section of Cardiac, Thoracic & Vascular Surgery, Department of Surgery, University of Oklahoma College of Medicine, Oklahoma City, OK; <sup>4</sup>Section of Digestive Diseases and Nutrition, Department of Medicine, University of Oklahoma College of Medicine, Oklahoma City, OK, USA

Endoscopic dilation remains the primary approach for the treatment of gastrointestinal anastomotic strictures. However, strictures are commonly encountered challenges, often resulting in substantial morbidity and healthcare utilization. Recently, the use of liquid nitrogen spray-assisted balloon dilation, termed cryo-dilation, was described as an emerging adjunct in the management of refractory benign strictures.<sup>1</sup> However, the role and utility of cryo-dilation in such management remain unclear.

In this study, we retrospectively analyzed a single-center case series to assess the safety and utility of cryo-dilation for managing refractory strictures at anastomotic sites. The study methodology was approved and overseen by the University of Oklahoma Health Sciences Center Institution Review Board (IRB00000588; 16650), and waiver of informed consent was also approved. Refractory anastomotic strictures were defined as those that remained symptomatic in spite of four or more endoscopic dilation procedures. Single-operator cryo-dilation was performed under general anesthesia using the truFreeze Spray Cryotherapy System (STERIS Healthcare) with an active venting tube. This involved application of a liquid nitrogen spray for

30 seconds, followed by a 60-second thaw, for a total of three cycles. Following the final thaw, dilation with a 4 cm controlled radial expansion balloon was performed, with the maximum inflation size left to the discretion of the endoscopist (Fig. 1). We compared the number of dilation procedures required by each patient in the six months preceding and succeeding cryo-dilation. Data on post-procedural complications were collected via chart review.



**Fig. 1.** Treatment protocol (patient no. 1). (A) Procedure image before treatment showing a benign recalcitrant stricture at an esophago-colonic anastomotic site. (B) Procedure image showing liquid nitrogen application in the freezing phase. (C) Procedure image after the thawing phase showing dilation with a 4 cm controlled radial expansion balloon. (D) Procedure image post-dilation showing the treatment effect with improved patency of the stenotic site.

Received: January 10, 2024    Revised: March 3, 2024

Accepted: April 1, 2024

**Correspondence:** Christopher Adam Bouvette

Department of Medicine, University of Oklahoma College of Medicine, 800 Stanton L. Young Blvd AAT 6300, Oklahoma City, OK 73104, USA

E-mail: Christopher.a.bouvette@gmail.com

© This is an Open Access article distributed under the terms of the Creative Commons Attribution Non-Commercial License (<http://creativecommons.org/licenses/by-nc/4.0/>) which permits unrestricted non-commercial use, distribution, and reproduction in any medium, provided the original work is properly cited.

The study comprised seven patients (average age, 56.9 years). The distribution of anastomotic sites was as follows: esophago-gastric in four patients, esophago-colonic in one patient, gastro-jejunal in one patient, and ileo-colonic in one patient. The average inner diameter of the stricture before cryo-dilation was 7.1 mm. The average maximum dilation size reached was 15.2 mm, with a range of 12 to 18 mm. In the six months leading up to cryo-dilation, patients underwent a mean of seven dilation procedures, ranging from 2 to 16. Over the six months after cryo-dilation, the mean number of dilation procedures had decreased significantly to 0.6, with a range of 0 to 2. Four patients remained symptom free, with no dilation requirements at the six-month mark. Three patients reported a return of symptoms, necessitating repeat dilation. No instances of early or delayed bleeding or perforation were documented (Table 1). One patient experienced post-procedural pain, which was managed conservatively in the outpatient setting.

Balloon dilation with traditional, wire-guided, and through-the-scope dilators remains at the forefront of anastomotic stricture management. In the setting of recalcitrant strictures, several approaches augment therapy. Dilation coupled with intralesional steroid injections is speculated to inhibit inflammation and hinder progressive fibrosis. Under a similar motif, intralesional mitomycin C injections act by suppressing fibroblast proliferation and fibroblastic collagen synthesis.<sup>2</sup> Studies of both techniques suggest they increase the asymptomatic duration and reduce the frequency of future dilation requirements. Esophageal stents have also been incorporated, driven

by dilation failure or as an adjunct to dilation efforts. Stents support esophageal remodeling and may hinder the progression of a refractory lesion.<sup>2,3</sup> However, this method is limited by incidences of stent migration and patient intolerance secondary to pain.<sup>4</sup> Among the methods used to manage recalcitrant strictures, incisional therapy (radial incision and cutting method) is well described. Studies have demonstrated incisional therapy to have equivocal risk to that of traditional dilation methods, with potentially highest efficacy for strictures at anastomotic sites.<sup>5,6</sup> Self-dilation is highly efficacious but remains patient dependent with respect to implementation. When all interventions fail, surgical revision remains definitive.

Spray cryotherapy (SCT) has gained favor in the management of Barrett's esophagus, gastric antral vascular ectasia, and radiation proctitis. Recently, its novel use for the management of a benign refractory stricture at an anastomotic site was described.<sup>1</sup> SCT has the unique ability to induce tissue necrosis while preserving the extracellular matrix. The relative resistance of collagen and elastin minimizes an inflammatory response, theoretically circumventing compensatory fibrosis and scarring. In the case of anastomotic strictures, this paradigm has proven both safe and beneficial.

Treatment effects are speculated to be driven by four parameters: the cooling rate, final temperature, time maintained at final temperature, and thawing rate.<sup>7</sup> Within the freezing phase, extracellular ice crystals promote an osmotic gradient while intracellular ice crystals disrupt the cellular membranes.<sup>7</sup> At the periphery where cellular membranes may remain stable, mito-

**Table 1.** Cohort characteristics, prior intervention, and dilation requirement before and after cryo-dilation

Case no.	Age (yr)	Sex	Anastomosis type	Reason for resection	Prior endoscopic intervention	Dilations in 6 mo preceding cryo-dilation (n)	Diameter of stricture at time of cryo-dilation (mm)	Maximum balloon size (mm)	Dilations in 6 mo following cryo-dilation (n)
1	42	Male	Esophago-colonic	End-stage achalasia	Bougienage, balloon dilation, steroid injection, covered stent	16	7	16	2
2	56	Male	Esophago-gastric	Esophageal adenocarcinoma	Bougienage, balloon dilation	8	10	18	1
3	65	Male	Esophago-gastric	Esophageal adenocarcinoma	Bougienage, balloon dilation	6	8	15	0
4	49	Female	Esophago-gastric	Esophageal adenocarcinoma	Bougienage, balloon dilation, covered stent	6	8	18	0
5	62	Male	Gastro-jejunal	Peptic pyloric stricture	Balloon dilation	3	5	12	0
6	55	Male	Ileo-colonic	Colon adenocarcinoma	Balloon dilation	2	5	12	0
7	69	Female	Esophago-gastric	Esophageal adenocarcinoma	Balloon dilation	8	7	16	1

chondrial injury induces cytochrome C release and upregulates apoptosis.<sup>8</sup> The thawing cycle promotes an intracellular osmotic fluid shift and introduces further membrane damage through ice crystal fusion.<sup>8</sup> Endothelial damage and vascular stasis contribute to localized ischemic necrosis. Dosimetry data in this area remain limited, and existing protocols are delivery system specific. Specifically, it remains uncertain whether freezing, thawing, or the treatment duration plays the largest role in the therapeutic effect. Current SCT indications have been primarily explored within the setting of pathologic epithelia, malignant lesions, or porcine models.<sup>9,10</sup> Further studies on SCT physiology as it relates to fibrotic lesions may prove beneficial for optimizing treatment protocols.

Recalcitrant strictures are a challenging problem for both patients and endoscopists. Management usually requires multiple serial dilations, which diminishes the quality of life and bears significant costs. In many cases, frequent and failed dilation procedures are burdensome and can foster discordant patient-provider relationships. This case series suggests that SCT for recalcitrant anastomotic strictures is safe and may offer a more durable response compared with conventional approaches. The reduction in the number and frequency of dilation procedures required may provide significant quality of life improvements for patients and potential cost savings for health-care systems. However, these findings are limited by the sample size. Furthermore, with only six months of follow-up data, we are limited in concluding on the longevity of the benefits. We hope to expand upon prior reports of use of this intervention and advocate for its continued evaluation. Further studies are needed to validate the technique and to provide a more comprehensive assessment of patient selection, risk profile, and treatment effects.

Overall, the use of liquid nitrogen SCT-assisted balloon dilation for managing refractory anastomotic strictures appears to be a safe and effective approach. However, although we have demonstrated a reduced frequency of short-term dilation requirements across a limited sample, a more comprehensive assessment is needed to verify the durability of this technique.

## Conflicts of Interest

The authors have no potential conflicts of interest.

## Funding

None.

## Author Contributions

Conceptualization: CAB, AR; Data curation: CAB, JMR; Formal analysis: CAB; Investigation: all authors; Methodology: JMR; Project administration: AR; Supervision: JMR, AR; Visualization: ABN; Writing—original draft: CAB; Writing—review & editing: ABN, JMR, AR.

## ORCID

Christopher Adam Bouvette <https://orcid.org/0000-0003-3870-7469>  
 Ahmad Basel Nasir <https://orcid.org/0000-0003-1588-303X>  
 James Matthew Reinersman <https://orcid.org/0000-0002-4458-0743>  
 Amir Rumman <https://orcid.org/0000-0003-3808-0117>

## REFERENCES

1. Roccato MK, Duh E, Mai D, et al. 1828 CryoDilation: a novel treatment for benign esophageal strictures using liquid nitrogen spray cryotherapy. *Am J Gastroenterol* 2019;114:S1025.
2. Boregowda U, Goyal H, Mann R, et al. Endoscopic management of benign recalcitrant esophageal strictures. *Ann Gastroenterol* 2021; 34:287–299.
3. Spaander MC, van der Bogt RD, Baron TH, et al. Esophageal stenting for benign and malignant disease: European Society of Gastrointestinal Endoscopy (ESGE) Guideline: update 2021. *Endoscopy* 2021;53:751–762.
4. Fuccio L, Hassan C, Frazzoni L, et al. Clinical outcomes following stent placement in refractory benign esophageal stricture: a systematic review and meta-analysis. *Endoscopy* 2016;48:141–148.
5. Lee TH, Lee SH, Park JY, et al. Primary incisional therapy with a modified method for patients with benign anastomotic esophageal stricture. *Gastrointest Endosc* 2009;69:1029–1033.
6. Yano T, Yoda Y, Satake H, et al. Radial incision and cutting method for refractory stricture after nonsurgical treatment of esophageal cancer. *Endoscopy* 2013;45:316–319.
7. Erinjeri JB, Clark TW. Cryoablation: mechanism of action and devices. *J Vasc Interv Radiol* 2010;21(8 Suppl):S187–S191.
8. ASGE Technology Committee, Parsi MA, Trindade AJ, et al. Cryotherapy in gastrointestinal endoscopy. *VideoGIE* 2017;2:89–95.
9. Raju GS, Ahmed I, Xiao SY, et al. Graded esophageal mucosal ablation with cryotherapy, and the protective effects of submucosal saline. *Endoscopy* 2005;37:523–526.
10. Shin EJ, Amateau SK, Kim Y, et al. Dose-dependent depth of tissue injury with carbon dioxide cryotherapy in porcine GI tract. *Gastrointest Endosc* 2012;75:1062–1067.