

Unroofing of subepithelial lesions in the upper gastrointestinal tract using cold snare: an easy and efficient technique for diagnosis

Bernhard Morell, Frans Olivier The, Christoph Gubler*, Fritz Ruprecht Murray*

Gastroenterology and Hepatology Unit, Stadtspital Zürich, Zürich, Switzerland

Subepithelial lesions (SELs) are neoplastic or non-neoplastic tumors that can originate from various layers between the muscularis mucosa and the serosa anywhere in the gastrointestinal tract.¹ SELs manifest as discrete, small protrusions that have histologically unremarkable mucosal lining. They are commonly encountered as incidental findings during gastric endoscopy, with an observed prevalence rate of approximately 1.7%.² Most of these lesions are benign, and less than 15% display malignant features.³ Nevertheless, malignant differential diagnoses, such as small gastrointestinal stromal tumors (GISTs) must be considered.⁴

Characterizing these lesions can be challenging because the overlying mucosa and submucosa limit the diagnostic yield of sampling using standard biopsy forceps.¹ Endoscopic ultrasonography (EUS) is an invaluable tool that can be used to evaluate SELs. However, the accuracy of this modality is limited; therefore, tissue sampling is recommended, particularly for GISTs measuring >20 mm.¹ The recently published guidelines of the European Society of Gastrointestinal Endoscopy¹ recommend mucosal incision-assisted biopsy (MIAB) for tissue

acquisition from small SELs; however, EUS-guided fine-needle biopsy (EUS-FNB) is regarded as an alternative method. With a diagnostic yield of 90.7%, a recent meta-analysis demonstrated that MIAB is an effective and safe method for diagnostic work-up of SELs.⁵

In 2020, Zimmer and Eltze⁶ described a modified MIAB technique using a cold snare to expose the SELs. However, to the best of our knowledge, this method has not been further evaluated. Herein, we describe a retrospective analysis of 20 cases of unroofing using a cold snare to facilitate tissue sampling with a standard forceps biopsy.

The patients provided written consent for the evaluation of pertinent data, and the project was presented to a competent ethics committee, which waived the need for a formal ethical review.

With respect to the study by Zimmer and Eltze,⁶ the standard operating procedure (SOP) for the diagnostic workup of SELs in the upper gastrointestinal tract (UGT) was adapted in our institution in August 2021 to avoid the sometimes cumbersome use of needle knives in the context of MIAB. Regardless of the coincidental diagnosis during routine gastroscopy or after specific outpatient referral for EUS, 20 patients with UGT SELs were evaluated according to the SOP in our institution between September 2022 and March 2023. Unroofing biopsies were performed whenever sufficiently specific endoscopic (e.g., “pillow sign” in case of lipomas, central umbilication in case of ectopic pancreas) or endosonographic features were missing or whenever patients (3 cases) had a very strong wish to receive a histopathological diagnosis. One patient with an SEL that was suspected to be a lipoma was excluded from the analysis be-

Received: March 22, 2023 Revised: April 24, 2023 Accepted: April 25, 2023

Correspondence: Bernhard Morell

Gastroenterology and Hepatology Unit, Stadtspital Zürich, 497 Birmensdorferstrasse, CH-8063 Zürich, Switzerland

E-mail: bernhardkaspar.morell@stadtspital.ch

*Christoph Gubler and Fritz Ruprecht Murray contributed equally to this work.

© This is an Open Access article distributed under the terms of the Creative Commons Attribution Non-Commercial License (<http://creativecommons.org/licenses/by-nc/4.0/>) which permits unrestricted non-commercial use, distribution, and reproduction in any medium, provided the original work is properly cited.

cause no biopsy was performed after unroofing, which revealed typical macroscopic features (yellow fatty tissue). In the other 19 patients ($n=15$ stomach, $n=3$ duodenum, $n=1$ cardia), the mucosa of the apex of each SEL was resected with a standard cold snare (10 mm), similar to polypectomy (Fig. 1). If required, the procedure was repeated until the underlying lesion was endoscopically visible. After successful unroofing, targeted biopsies (1–8, mean 4.4) were obtained using standard forceps (Fig. 1C). Subsequently, the unroofing site was carefully observed for a sufficient period to rule out bleeding. Prophylactic clipping was performed at the discretion of the examiner.

Table 1 summarizes the clinical characteristics of the 19 SELs examined after cold snare unroofing. Fifteen (78.9%) out of the 19 patients were additionally evaluated using EUS before unroofing. The mean lesion size, as determined using EUS was 9.8 mm (range, 7–15 mm). In 18/19 (94.7%), representative tissue samples could be obtained. In one patient with an SEL in the antrum compatible with an ectopic pancreas due to its central umbilication, biopsies were non-diagnostic.

Notably, no major complications occurred during or after

unroofing. Two patients experienced self-limiting epigastric pain. In six patients, prophylactic clipping of the biopsy site was performed.

This case series demonstrates the feasibility of a modified unroofing technique in the diagnostic workup of UGT SELs, which offers several advantages over MIAB using a needle knife. For the latter method, as described by Okuzono et al.⁷ in 2014, incision of the mucosa and submucosa with a tip knife was performed until the SEL was exposed and became amenable to forceps biopsy. As cold snare unroofing does not depend on the use of electrocautery, it is readily available and does not carry any risk of thermal tissue injury that would restrict histological assessability.⁷ Furthermore, it is conceivable that cold snare unroofing can be performed rapidly because the average number of biopsies (4.4) in our study was comparable to that described by Okuzono et al.⁷ However, we were unable to prove this assumption because most interventions include EUS, and the examination time was thus not exploitable. Whether EUS examination is mandatory before cold snare unroofing is debatable; however, EUS should be performed if gastric varices, arte-

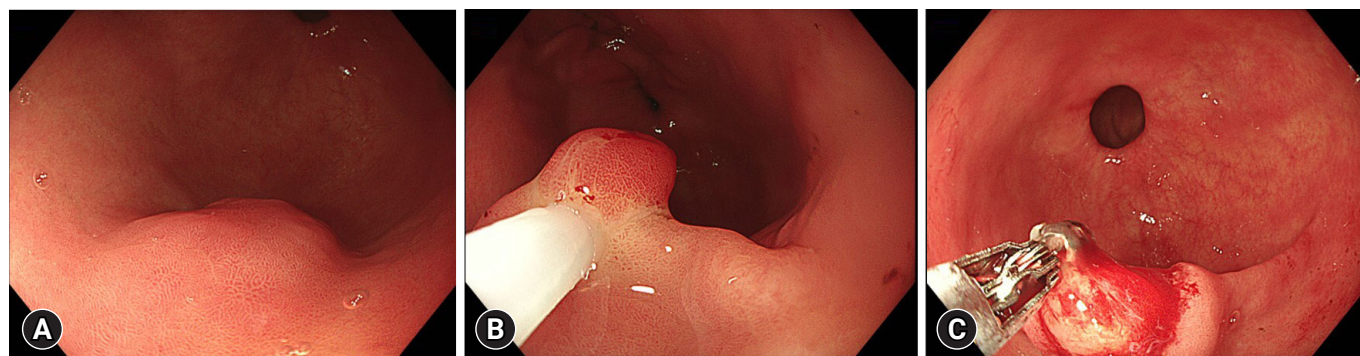


Fig. 1. Illustrative images of cold snare unroofing. (A) A subepithelial lesion in the antrum. Even though the shape of the lesion was suggestive of a lipoma, endosonographic features were non-diagnostic. Histopathology showed an ectopic pancreas. (B) Cold snare unroofing. (C) Biopsy using standard forceps.

Table 1. Clinical characteristics of 19 subepithelial lesions biopsied using cold snare unroofing

Diagnosis	No. of patients (male/female)	Location	Layer in EUS	Median size (mm, range)	Clipping (n)	Median no. of biopsies	Complication
Lipoma	7 (1/6)	s=5, d=2	4/4 in layer 3, no EUS in n=3	9.5 (6–15)	3	4	Mild pain (n=1)
Ectopic pancreas ^{a)}	6 (4/2)	s=6	5/6 in layer 3, no EUS in n=1	7 (7–10)	2	4.5	Mild pain (n=1)
Schwannoma	1 (0/1)	s=1	Layer 4	12	None	8	None
Leiomyoma	3 (2/1)	s=2, c=1	2/3 in layer 4, 1 in layer 2	5 (8–14)	None	5	None
Lymphangioma	1 (1/0)	d=1	Layer 3	n/a	None	3	None
Foreign body ^{b)}	1 (0/1)	s=1	Layer 4	15	1	5	None

No., number; EUS, endoscopic ultrasonography; s, stomach; d, duodenum; c, cardia; n/a, not available.

^{a)}n=1 patient with negative histology, ^{b)}Histological examination showed an inflammatory reaction to a foreign body of unknown origin.

riovenous malformations, or duplication cysts are considered in the differential diagnosis.

The extent to which a diagnostic yield of 94.5% could be reproduced in a larger cohort remains uncertain. In particular, the question of whether SELs arising from the 4th wall layer can be reliably characterized using this method requires further evaluation. Interestingly, a meta-analysis by Dhaliwal et al.⁸ suggested that SELs arising within the deeper wall layers may be reliably characterized using MIAB, as 38.6% of the SELs were GISTs. However, it is noteworthy that the average size of the SELs in this cohort was only 9.8 mm, which is again in favor of this method, as opposed to the expected yield of EUS-FNB for the evaluation of very small SELs.

No major complications occurred in this case series. Two patients (2/19, 10.5%) reported self-limiting epigastric pain after the procedure. However, no bleeding was recorded from the biopsy site. Whether prophylactic clipping should be performed remains unclear and warrants further investigation.

Taken together, cold snare unroofing is a quick, safe, and efficient technique that can be easily applied in clinical practice. Further studies are required to prove the reliability of this method, particularly for diagnosing SELs arising from the 4th layer.

Conflicts of Interest

The authors have no potential conflicts of interest.

Funding

None.

Author Contributions

Conceptualization: BM, FRM, CG; Data curation: BM, FRM, CG; Formal analysis: FOT; Methodology: BM, FRM, CG; Writing—original draft: BM, FM, CG; Writing—review & editing: all authors.

ORCID

Bernhard Morell	https://orcid.org/0000-0002-8507-0619
Frans Olivier The	https://orcid.org/0000-0003-3541-8370
Christoph Gubler	https://orcid.org/0000-0002-0426-8069
Fritz Ruprecht Murray	https://orcid.org/0000-0002-7381-780X

REFERENCES

1. Deprez PH, Moons LM, O'Toole D, et al. Endoscopic management of subepithelial lesions including neuroendocrine neoplasms: European Society of Gastrointestinal Endoscopy (ESGE) Guideline. *Endoscopy* 2022;54:412–429.
2. Lee JH, Lee HL, Ahn YW, et al. Prevalence of gastric subepithelial tumors in Korea: a single center experience. *Korean J Gastroenterol* 2015;66:274–276.
3. Polkowski M. Endoscopic ultrasound and endoscopic ultrasound-guided fine-needle biopsy for the diagnosis of malignant submucosal tumors. *Endoscopy* 2005;37:635–645.
4. Cho JW; Korean ESD Study Group. Current guidelines in the management of upper gastrointestinal subepithelial tumors. *Clin Endosc* 2016;49:235–240.
5. Giri S, Afzalpurkar S, Angadi S, et al. Mucosal incision-assisted biopsy versus endoscopic ultrasound-assisted tissue acquisition for subepithelial lesions: a systematic review and meta-analysis. *Clin Endosc* 2022;55:615–625.
6. Zimmer V, Eltze E. Cold snare decapitation and blunt endoscopic dissection for tissue diagnosis of a gastric subepithelial lesion under direct vision. *Gastrointest Endosc* 2020;91:193–195.
7. Okuzono T, Mishima T, Badran A, et al. Endoscopic biopsy by mucosal incision for upper gastrointestinal submucosal tumors. *Video J Encycl GI Endosc* 2014;1:644–646.
8. Dhaliwal A, Kolli S, Dhindsa BS, et al. Clinical efficacy and safety of mucosal incision-assisted biopsy for the diagnosis of upper gastrointestinal subepithelial tumors: a systematic review and meta-analysis. *Ann Gastroenterol* 2020;33:155–161.