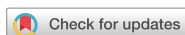

## Case Report



# Continuation of Enteral Nutrition and Relief from Vomiting by Administration of a New Formula: a Case Report

Tetsuro Akashi , Kazuhide Matsumoto, Risa Hashimoto

Department of Internal Medicine, Saiseikai Fukuoka General Hospital, Fukuoka, Japan



**Received:** Jun 19, 2017

**Revised:** Sep 1, 2017

**Accepted:** Sep 8, 2017

### Correspondence to

**Tetsuro Akashi**

Department of Internal Medicine, Saiseikai  
Fukuoka General Hospital, 1-3-46, Tenjin,  
Chuo-ku, Fukuoka 810-0001, Japan.

Tel: +81-92-771-8151

Fax: +81-92-716-0185

E-mail: tetsu71jpp@yahoo.co.jp

Copyright © 2017. The Korean Society of  
Clinical Nutrition

This is an Open Access article distributed  
under the terms of the Creative Commons  
Attribution Non-Commercial License (<https://creativecommons.org/licenses/by-nc/4.0/>)  
which permits unrestricted non-commercial  
use, distribution, and reproduction in any  
medium, provided the original work is properly  
cited.

### ORCID iDs

Tetsuro Akashi

<https://orcid.org/0000-0002-3788-6787>

### Conflict of Interest

The authors declare that they have no  
competing interests.

## ABSTRACT

Gastro-esophageal reflux (GER) is a common and serious complication in patients receiving enteral nutrition, making continuation of enteral nutrition difficult. Semi-solid enteral nutrients were developed to prevent feeding-related GER. Semi-solid enteral nutrients have high viscosity and, therefore, are typically administered through a large-diameter percutaneous endoscopic gastrostomy (PEG) tube. Recently, a new formula (Mermed®, Mermed Plus®) was introduced that uses alginate, which behaves like a gelatin in acidic conditions. This formula improved GER during enteral feedings. Our case report shows that this new formula enables the continuation of enteral nutrition via a nasogastric tube (NGT) in patients with difficulty tolerating enteral nutrition secondary to vomiting. An 86-year-old woman with an atherothrombotic cerebral infarction vomited during tube feeding, resulting in aspiration pneumonia. After 1 week, we introduced a viscosity regulator and restarted enteral feeding using a 100 mL liquid diet, but vomiting persisted. Because of the continued difficulty in tolerating enteral nutrition, the patient was transferred to our hospital. From hospital day 4, Mermed Plus® (300 mL/225 kcal, administered for 1 hour, 3 times a day) was started, eventually increasing to 535 mL/400 kcal at hospital day 5. After this, vomiting ceased. Mermed Plus® was easily administered via NGT, and its effects were immediate. This treatment appeared to improve the patient's quality of life while reducing the burden on medical staff.

**Keywords:** Enteral nutrition; Gastroesophageal reflux; Viscosity; Alginates

## INTRODUCTION

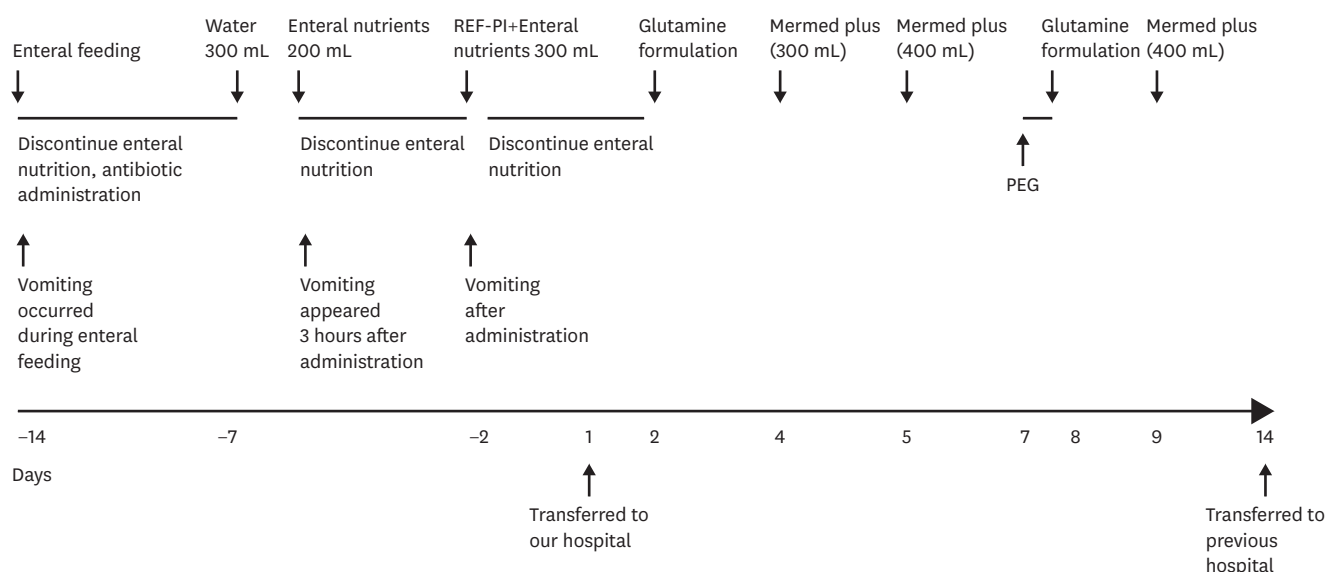
Enteral nutrition is the first-choice nutritional therapy for patients without gastrointestinal tract impairment [1]. Aspiration pneumonitis, caused by gastro-esophageal reflux (GER) of fed nutrients, is a frequent and life-threatening inflammatory event in patients who are fed enterally [2]. Semi-solid enteral nutrients are widely used in Japan and were developed as an alternative to conventional liquid enteral nutrients to prevent feeding-related GER [3,4]. Semi-solid enteral nutrients have a higher viscosity compared to liquid enteral nutrients and, therefore, are typically administered through a large-diameter percutaneous endoscopic gastrostomy (PEG) tube, rather than a nasogastric tube (NGT). In Japan, a pectin solution is used to semi-solidify liquid nutrients administered via small-diameter NGT. Low methoxide pectin in the presence of ionized calcium increases viscosity; therefore, the pectin

solution increases the viscosity of liquid enteral nutrients, improving GER [5,6]. Because the pectin solution and liquid enteral nutrients are administered separately, it can be easily administered via NGT. A new formula (Mermed®; Terumo Corporation, Tokyo, Japan) uses alginate, which behaves as a gelatin in acidic conditions, improving GER and diarrhea that result from enteral feeding [7,8]. Mermed® is in a liquid state when administered through a NGT, and changes into a semi-solidified state in the stomach prior to reverting to a liquid state within the intestines [7]. We present a case where administration of Mermed Plus® (with increased water content; Terumo Corporation, Tokyo, Japan) in a patient undergoing rehabilitation after cerebral infarction, reduced vomiting, thereby enabling the continuation of enteral nutrition. The ethics committee of Saiseikai Fukuoka General Hospital (2017-7-3) approved this case report and waived the requirement for informed consent.

## CASE

The patient is an 86-year-old woman. Prior to entering our care, the patient performed usual daily living activities independently, including eating and toileting, albeit needing to use a cane for support. One month earlier, the patient developed an atherothrombotic cerebral infarction in the right anterior cerebral artery and right middle cerebral artery area, and was hospitalized at another hospital for 2 weeks before being transferring to our hospital. The clinical course of the patient is shown in **Figure 1**. On the first day of hospitalization, the patient experienced vomiting during enteral feeding via NGT and developed aspiration pneumonia. Enteral feeding was discontinued, and the patient was then changed to peripheral parenteral nutrition and antibiotics were administered. After 1 week, enteral feeding was restarted using 300 mL of water with no signs of vomiting. A liquid diet was slowly introduced beginning the next day. The patient started vomiting 3 hours later, and enteral feeding was discontinued once again.

REF-P1, a viscosity regulator, was introduced for use in combination with her liquid diet and enteral feeding was restarted using a 100 mL liquid diet but vomiting persisted. As a result,



**Figure 1.** The patient's clinical course.

PEG, percutaneous endoscopic gastrostomy; REF-P1, a viscosity regulator (Kewpie Corporation, Tokyo, Japan).

the patient was unable to continue enteral nutrition and was transferred to our hospital to resume nutritional therapy.

Computed tomography (CT) and esophagogastroduodenoscopy were performed on hospital day 2, and was negative for transit disorder, upper gastrointestinal ulcer, or feces accumulation. From hospital day 2, enteral feeding was resumed using a glutamine formulation, after which no vomiting was observed. Beginning from hospital day 4, the proton pump inhibitor was discontinued and Mermed Plus® (300 mL/225 kcal, administered for 1 hour, 3 times a day) was started. No vomiting was observed after resuming enteral feedings with Mermed Plus® and dietary intake of the patient was increased to 535 mL/400 kcal (administered for 1 hour, 3 times a day) beginning on hospital day 5, after which no vomiting was observed. Because the patient required enteral nutrition for more than 1 month, a PEG was performed on hospital day 7 after obtaining informed consent. The postoperative course of the patient was uneventful, and there was no vomiting while continuing with Mermed Plus® (535 mL/400 kcal, administered for 1 hour, 3 times a day). On hospital day 14, the patient was transferred back to the previous hospital to continue rehabilitation.

## DISCUSSION

Enteral nutrition is more affected by physiological parameters than parenteral nutrition. Enteral nutrition improves patient outcomes and decreases healthcare costs compared to parenteral nutrition [9]. GER is a common and serious complication in patients receiving enteral nutrition, potentially making continuation of enteral nutrition difficult. Our case report showed that a new semi-solid formula enabled continuation of enteral nutrition via NGT in a patient who had difficulty in tolerating enteral nutrition due to vomiting.

In our case, no vomiting occurred with the administration of water, but vomiting re-occurred when liquid enteral nutrients were administered. The oral rehydration solution was quickly discharged from the stomach, and its effect was applied before introducing general anesthesia [10]. Gastric emptying time is affected by the stomach expansion following the ingestion of a set volume load. Gastric emptying time increases in proportion to intake, up to a single intake of 600 mL [11]. In addition, chemical receptors in the stomach and the small intestine react to ingested substances then digestive juices are secreted and stimulate the movement of the gastrointestinal tract. This movement is affected by the type of digestive juices secreted from gastrointestinal wall [12]. Therefore, for enteral nutrients that contain proteins and lipids, gastric emptying time was prolonged and vomiting occurred.

On the contrary, “adaptive relaxation” modulates gastric tone in response to specific meal properties, promotes physiological movement within the stomach [13,14] and is an important factor relating to enteral nutrient viscosity. Semi-solid enteral nutrients that appeared in recent years are more likely to exhibit adaptive relaxation than liquid enteral nutrients, potentially suppressing GER. Semi-solid enteral nutrients have high viscosity, and therefore are typically administered through a large-diameter PEG tube.

In our case, REF-P1 and Mermed Plus®, which are easily administered via NGT, were used. Vomiting occurred when REF-P1 and 100 mL enteral nutrients were administered but did not occur with the administration of 300 mL Mermed Plus®. To facilitate adaptive relaxation of

the stomach, REF-P1 and the small amount of enteral nutrients were not sufficiently viscous; however, with Mermed Plus®, we were able to achieve adequate viscosity and volume.

To prevent vomiting, it is common to slow the administration rate of enteral nutrients and/or use a duodenal tube [15], however these methods increase the burden on the patients and the medical staff. In the present case, Mermed Plus® was easily administered via NGT, and the effect was quickly obtained. Therefore, its use may improve the patient's quality of life while reducing the burden on the medical staff.

## REFERENCES

1. ASPEN Board of Directors and the Clinical Guidelines Task Force. Guidelines for the use of parenteral and enteral nutrition in adult and pediatric patients. JPEN J Parenter Enteral Nutr 2002;26:1SA-138SA.
2. Marik PE. Aspiration pneumonia and aspiration pneumonia. N Engl J Med 2001;344:665-71.  
[PUBMED](#) | [CROSSREF](#)
3. Kanie J, Suzuki Y, Iguchi A, Akatsu H, Yamamoto T, Shimokata H. Prevention of gastroesophageal reflux using an application of half-solid nutrients in patients with percutaneous endoscopic gastrostomy feeding. J Am Geriatr Soc 2004;52:466-7.  
[PUBMED](#) | [CROSSREF](#)
4. Kanie J, Suzuki Y, Akatsu H, Kuzuya M, Iguchi A. Prevention of late complications by half-solid enteral nutrients in percutaneous endoscopic gastrostomy tube feeding. Gerontology 2004;50:417-9.  
[PUBMED](#) | [CROSSREF](#)
5. Inada H, Kaneda K, Yamagata T. Prevention of aspiration pneumonia in patients with gastroesophageal reflux using REF-P1 (pectin gel). J Jap Soc Parenter Enter Nutr 1998;20:1031-6.
6. Adachi K, Furuta K, Aimi M, Fukazawa K, Shimura S, Ohara S, Nakata S, Inoue Y, Ryuko K, Ishine J, Katoh K, Hirata T, Ohhata S, Katoh S, Moriyama M, Sumikawa M, Sanpei M, Kinoshita Y. Efficacy of pectin solution for preventing gastro-esophageal reflux events in patients with percutaneous endoscopic gastrostomy. J Clin Biochem Nutr 2012;50:190-4.  
[PUBMED](#) | [CROSSREF](#)
7. Inoue H, Kawashima Y, Hamada K, Yokota S, Sasaki M. Functional evaluations of a new type formula that features a state change from liquid to semi-solidified state depending upon pH. Clin Nutr ESPEN 2014;9:e185-91.
8. Nishimura S, Takata T, Nakamura F, Goda F, Akashi T, Mizuno H, Mihara C, Sato H, Kurihara M, Sasaki M. Clinical usefulness of new type formula that features a state change from liquid to semisolidified state depending upon pH. J Jap Soc Parenter Enter Nutr 2016;31:1270-3.
9. Pritchard C, Duffy S, Edington J, Pang F. Enteral nutrition and oral nutrition supplements: a review of the economics literature. JPEN J Parenter Enteral Nutr 2006;30:52-9.  
[PUBMED](#) | [CROSSREF](#)
10. Taniguchi H, Sasaki T, Fujita H, Takamori M, Kawasaki R, Momiyama Y, Takano O, Shibata T, Goto T. Preoperative fluid and electrolyte management with oral rehydration therapy. J Anesth 2009;23:222-9.  
[PUBMED](#) | [CROSSREF](#)
11. Costill DL, Saltin B. Factors limiting gastric emptying during rest and exercise. J Appl Physiol 1974;37:679-83.  
[PUBMED](#)
12. De Schepper H, Camilleri M, Cremonini F, Foxx-Orenstein A, Burton D. Comparison of gastric volumes in response to isocaloric liquid and mixed meals in humans. Neurogastroenterol Motil 2004;16:567-73.  
[PUBMED](#) | [CROSSREF](#)
13. Jahnberg T, Martinson J, Hultén L, Fasth S. Dynamic gastric response to expansion before and after vagotomy. Scand J Gastroenterol 1975;10:593-8.  
[PUBMED](#)
14. Schwizer W, Steingötter A, Fox M, Zur T, Thumshirn M, Bösigler P, Fried M. Non-invasive measurement of gastric accommodation in humans. Gut 2002;51 Suppl 1:i59-62.  
[PUBMED](#) | [CROSSREF](#)
15. Blumenstein I, Shastri YM, Stein J. Gastroenteric tube feeding: techniques, problems and solutions. World J Gastroenterol 2014;20:8505-24.  
[PUBMED](#) | [CROSSREF](#)