



# 림프절변연부 B세포림프종 환자에서 *Mucor circinelloides*에 의한 복막염 및 파종성 털곰팡이증 증례

## A Case of Peritonitis and Disseminated Mucormycosis Caused by *Mucor circinelloides* in a Patient with Nodal Marginal Zone B-cell Lymphoma

윤수미<sup>1</sup> · 김한아<sup>1</sup> · 문희원<sup>1</sup> · 허희재<sup>2</sup> · 허미나<sup>1</sup> · 윤여민<sup>1</sup> · 이홍기<sup>3</sup>

Sumi Yoon, M.D.<sup>1</sup>, Hanah Kim, M.D.<sup>1</sup>, Hee-Won Moon, M.D.<sup>1</sup>, Hee Jae Huh, M.D.<sup>2</sup>, Mina Hur, M.D.<sup>1</sup>, Yeo-Min Yun, M.D.<sup>1</sup>, Mark Hong Lee, M.D.<sup>3</sup>

건국대학교병원 진단검사의학과<sup>1</sup>, 성균관대학교 의과대학 삼성서울병원 진단검사의학과<sup>2</sup>, 건국대학교병원 내과<sup>3</sup>

Department of Laboratory Medicine<sup>1</sup>, Konkuk University School of Medicine, Seoul; Department of Laboratory Medicine and Genetics<sup>2</sup>, Samsung Medical Center, Sungkyunkwan University School of Medicine, Seoul; Department of Internal Medicine<sup>3</sup>, Konkuk University School of Medicine, Seoul, Korea

Mucormycosis is a fungal infection, which is difficult to treat due to its rapid dissemination and low susceptibility to anti-fungal agents. Peritonitis preceded by gastrointestinal mucormycosis is very rare, and only a few cases have been reported. We present a case of peritonitis and disseminated mucormycosis caused by *Mucor circinelloides* in an immunocompromised patient. A 59-year-old man, diagnosed with nodal marginal zone B-cell lymphoma, was diagnosed with liver failure due to severe septic shock. A white, woolly cotton-like growth, which was consistent with that of *Mucor* species, was isolated from ascites and sputum specimens. Targeted DNA sequencing confirmed the isolate as *M. circinelloides* with 100% identity. Despite anti-fungal treatment, the patient died after four days. This is a rare case of peritonitis and disseminated mucormycosis that was probably preceded by gastrointestinal mucormycosis caused by *M. circinelloides*, as determined by molecular methods. Accurate and rapid identification of mold using molecular methods might be necessary for early treatment in critical cases, and more cases should be clinically evaluated further.

**Key Words:** *Mucor circinelloides*, Mucormycosis, Gastrointestinal, Peritonitis, Disseminated

### INTRODUCTION

Mucormycosis is one of the most common fungal infections caused by species belonging to the order Mucorales such as *Mucor* and *Rhizopus* [1]. Similar to other invasive fungal infections,

mucormycosis can occur in immunocompromised patients with cancer, inherited immunodeficiency, diabetes mellitus, and even organ transplant recipients [2, 3]. Mucormycosis is difficult to treat due to fast dissemination and low susceptibility to anti-fungal agents, which results in worse outcomes than other common fungal infections, such as aspergillosis [4]. Peritonitis preceded by gastrointestinal (GI) mucormycosis is very rare, and only a few cases have been reported, which were caused by *Rhizopus microsporus* [5-7]. We present a case of peritonitis and disseminated mucormycosis caused by *Mucor circinelloides* in a patient with nodal marginal zone B-cell lymphoma.

**Corresponding author:** Hee-Won Moon, M.D., Ph.D.

<https://orcid.org/0000-0001-9509-6073>

Department of Laboratory Medicine, Konkuk University School of Medicine, Konkuk University Medical Center, 120-1 Neungdong-ro, Gwangjin-gu, Seoul 05030, Korea

Tel: +82-2-2030-5583, Fax: +82-2-2636-6764, E-mail: hannasis@hanmail.net

Received: October 17, 2019

Revision received: November 21, 2019

Accepted: January 29, 2020

This article is available from <https://www.labmedonline.org>

© 2020, Laboratory Medicine Online

© This is an Open Access article distributed under the terms of the Creative Commons Attribution Non-Commercial License (<https://creativecommons.org/licenses/by-nc/4.0/>) which permits unrestricted non-commercial use, distribution, and reproduction in any medium, provided the original work is properly cited.

### CASE REPORT

A 59-year-old man who was diagnosed with nodal marginal zone B-cell lymphoma and received scheduled chemotherapy was hospitalized for one day for high fever (39.5°C) and general

weakness. His complete blood counts were as follows: hemoglobin 86 g/L, white blood cells (WBC)  $0.11 \times 10^9/L$ , platelets  $36 \times 10^9/L$ . He also had a neutropenic fever. After two days, he showed abnormal results of liver function test (LFT), and his other blood tests reports were as follows: aspartate aminotransferase 13,476 IU/L, alanine aminotransferase 4,591 IU/L, total bilirubin 3.37 mg/dL,  $\gamma$ -glutamyl transferase 51 IU/L, and high-sensitivity C-reactive protein 18.80 mg/dL. *Pseudomonas aeruginosa* was grown on sputum and blood culture in all of two culture bottles. The galactomannan test (PLATELIA *Aspergillus* Ag, Bio-Rad, Marnes-la-Coquette, France) of serum was positive, and chest computed tomography revealed multifocal pneumonia combined with pulmonary aspergillosis. He received antibiotics (meropenem, cefepime, and vancomycin) for pneumonia and caspofungin (35 mg daily for two weeks) for aspergillosis. Ten days after showing LFT abnormality, an abdominal computed tomography to evaluate LFT abnormality revealed a large amount of ascites (Fig. 1A). He was diagnosed with liver failure due to severe septic shock. The laboratory test results of serum were: total protein 47 g/L, albumin 27 g/L, glucose 133 mg/dL, lactate dehydrogenase (LDH) 814 IU/L. Cell counts and other laboratory test results of ascites were: WBC  $4.5 \times 10^9/L$  (neutrophils were 93% of WBC), red blood cells  $24.0 \times 10^9/L$ , total protein 13 g/L, albumin 7 g/L, glucose 117 mg/dL, LDH 630 IU/L. The serum ascites to albumin gradient was 20 g/L.

A specimen of ascites in a blood culture bottle was transferred to laboratory, and cultured on a blood agar plate at 37°C and 5% CO<sub>2</sub> atmosphere for 15 hours. Mold grown on blood agar plate was inoculated on a Sabouraud dextrose agar and incubated at 30°C. A fluffy, white, cottony growth was observed on Sabouraud

dextrose agar at 48 hours (Fig. 1B). The color turned greyish brown with time, though the part visible from the bottom of the plate remained pale white. Staining with lactophenol cotton blue showed irregular aseptate hyphae branched at obtuse angles without rhizoids. Globose sporangia were filled with round spores and located at the end of long sporangiophores (Fig. 1C). The macroscopic and microscopic morphologies were consistent with *Mucor* species. The (1,3)- $\beta$ -D-glucan and galactomannan tests of ascites and serum were negative. Only *P. aeruginosa* and *Stenotrophomonas maltophilia* were seen growing in sputum culture, and no growth was observed on pleural fluid culture. After five days, another set of ascites and sputum specimens of the same patient were cultured, and the same mold was isolated.

For accurate identification of the species, the pure culture isolated on Sabouraud dextrose agar was analyzed by using polymerase chain reaction and direct sequencing analysis targeting the internal transcribed spacer (ITS) and the D1/D2 regions. DNA extraction was performed on a MagNA Pure 96 system (Roche Diagnostics, Mannheim, Germany) according to the procedure recommended by the manufacturer. BigDye Terminator Cycle Sequencing Ready Reaction Kit (Applied Biosystems, Foster City, CA, USA) and ABI Prism 3730 Genetic Analyzer (Applied Biosystems) were used for sequencing of the extracted and amplified DNA products. According to the Clinical and Laboratory Standards Institute guidelines (MM18-A) [8], primer sets of ITS-1/ITS-4 and ITS-5/ITS-4 were used for amplifying ITS, and a primer set of NL-1/NL-4 was used for amplifying the D1/D2 region of ribosomal DNA. For identification, the BLAST search was performed in the GenBank database available at the NCBI website (<http://www.ncbi>.

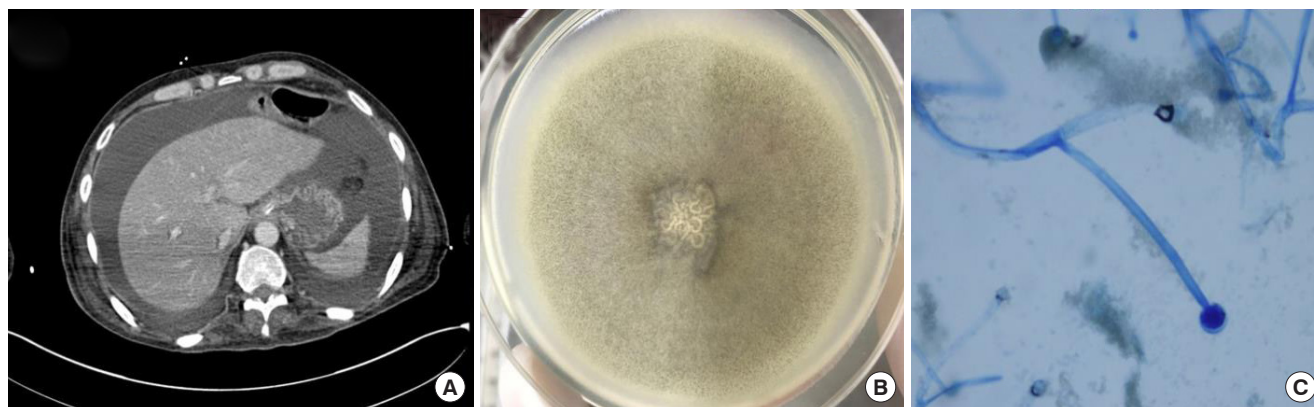


Fig. 1. Computed tomography (CT) scan and identified *Mucor circinelloides* from the patient. (A) Ascites in abdominal CT. (B) Macroscopic feature on Sabouraud dextrose agar plate. (C) Microscopic features (x200) after lactophenol cotton blue staining.

nlm.nih.gov). Targeted DNA sequencing confirmed the isolate as *M. circinelloides* with 100% identity for both ITS and D1/D2 regions. Though the patient received amphotericin B (300 mg daily) as soon as *Mucor* species was identified, he died four days after receiving amphotericin B.

## DISCUSSION

Mucormycosis is a fatal infection caused by fungi of the order Mucorales. The most common genera that cause mucormycosis are *Rhizopus*, *Mucor*, and *Lichtheimia* (formerly *Absidia* and *Mycocladius*). Mucormycosis is an opportunistic infection in immunocompromised patients, especially those with hematologic malignancy, severe neutropenia, and diabetes mellitus [2, 3]. Mucormycosis can cause outbreaks among the patients with risk factors, and the incidence rate of mucormycosis related hospitalizations shows an average every annual increase of >5%. Several outbreaks of mucormycosis were investigated, and all of them were associated with infections in healthcare environments caused by insufficient air filtration and contaminated objects [9]. We identified *Mucor* in only one patient, and the possibility of outbreak seems low.

Unlike other fungal infections, mucormycosis shows rapid progression and angioinvasion, and causes tissue necrosis and dissemination. Mucorales cause invasive infection at various levels including cutaneous, rhinocerebral, pulmonary, GI, and disseminated. In rare cases, mucormycosis can also cause peritonitis, endocarditis, and osteomyelitis [2, 3].

Several cases of mucormycosis peritonitis were reported, and most of them were related with peritoneal dialysis related mucormycosis [10-14]. Only a few cases of peritonitis were preceded by GI mucormycosis, three such reported cases are listed in Table 1 [5-7]: two were related to perforation of sigmoid colon or small intestine caused by *R. microspores*, while one was related to perforation of jejunum. The microscopic features of jejunum were con-

sistent with GI mucormycosis; however, the identification of fungal species was not available. After anti-fungal treatment including amphotericin B and voriconazole, all patients died within 47 days. In our case, the patient did not have peritoneal dialysis history, and there was a possibility that GI mucormycosis occurred and proceeded to peritonitis. This is a rare case of peritonitis and disseminated mucormycosis probably preceded by GI mucormycosis caused by *M. circinelloides*.

GI mucormycosis is uncommon, accounting for 0% to 9% of mucormycosis depending on the host conditions, notably 3% in patients with malignancy [2]. GI mucormycosis can occur after ingestion of foods contaminated with mold, and can proceed to perforation, peritonitis, and sepsis caused by fungal invasion to bowel walls and blood vessels [3]. In addition, an outbreak of GI mucormycosis has also been reported, which occurred after ingesting yogurts contaminated with mold that were later identified as *M. circinelloides* [15].

So far, there are no available serological biomarkers for diagnosing mucormycosis, such as (1,3)- $\beta$ -D-glucan and galactomannan, which are used for diagnosing other invasive fungal infection [4]. The traditional culture method is still important, however, it takes time to isolate and identify a fungus as compared to the rapid progression of Mucorales [4]. Amphotericin B has been recommended as first-line treatment for mucormycosis [16, 17]. Posaconazole and voriconazole are more effective against some Mucorales [4]. Various Mucorales and even the individual species show variable response to anti-fungal agents [4]. Therefore, mucormycosis is difficult to diagnose early and to be treated successfully, which results into higher mortality that exceeds 50% despite anti-fungal treatment [4]. Disseminated mucormycosis especially shows fatal outcome [3]. In this case, the patient died four days after receiving amphotericin B. He had several risk factors that were prone to fungal infection and its fast dissemination, including hematology malignancy, neutropenic status, and use of antibiotics. Five days after identifying *Mucor* species of initial ascites specimen,

Table 1. Cases of peritonitis preceded by GI mucormycosis

Reference	Country	Age/sex	Source of Infection	Specimen	Culture Result	Molecular Identification
Monecke et al. 2006 [5]	Germany	62/F	Perforation of sigmoid colon	Peritoneal swabs	<i>Rhizopus</i> spp.	<i>R. microsporus</i>
Hyvernath et al. 2010 [6]	France	52/F	Perforation of small intestine	Intra-abdominal fluid	<i>Rhizopus</i> spp.	<i>R. microsporus</i>
Kumar et al. 2017 [7]	India	24/F	Perforation of jejunum	Resected segment of jejunum	NA	NA
Present case	Korea	59/M	Unknown (probably GI origin)	Ascites and sputum	<i>Mucor</i> spp.	<i>M. circinelloides</i>

Abbreviations: F, female; GI, gastrointestinal; M, male; NA, information not available; spp., species.

the same mold was isolated in the sputum specimen. He might have shown GI mucormycosis of *M. circinelloides* followed by peritonitis and disseminated mucormycosis in the lung; however, the anti-fungal susceptibility test of the isolate was not performed in this case.

Yang et al. [18] have reported the identification of Mucorales using molecular methods. But there have been some discrepancies cases between microscopic morphological and molecular identification. Some species of Mucorales cannot be easily identified solely based on the morphology. Therefore, molecular methods are considered to be more reliable and need to be performed for accurate identification of Mucorales [18]. This case showed concordance between morphological and molecular identification.

In conclusion, we report a rare case of peritonitis and disseminated mucormycosis probably preceded by GI mucormycosis caused by *M. circinelloides*. Accurate and rapid identification of the mold using molecular methods might be necessary for early treatment in critical and rare cases, and more cases should be clinically evaluated further.

## 요 약

털곰팡이증(mucormycosis)은 진균 감염의 하나로, 빠른 진행과 낮은 항진균제 감수성으로 인해 치료하기 어렵다. 위장관계 털곰팡이증이 복막염으로 진행되는 경우는 매우 드물고, 소수의 증례만이 보고되었다. 저자들은 면역억제 환자에서 *Mucor circinelloides*에 의한 복막염 및 파종성 털곰팡이증 증례를 보고한다. 림프절변연부 B세포림프종으로 진단받았던 59세 남자 환자가 심한 패혈쇼크로 인한 간부전이 발생하였다. 복수와 객담 검체로부터 하얀색의 솜털 같은 집락이 분리되었고, *Mucor* 종에 합당한 소견이었다. 균주의 염기서열분석은 *M. circinelloides*와 100% 일치도를 보였다. 항진균제 치료에도 불구하고, 환자는 4일 후에 사망하였다. 본 증례는 분자방법을 이용하여 밝혀낸 *M. circinelloides*에 의해 발생한, 아마도 위장관계 털곰팡이증이 복막염 및 파종성 털곰팡이증으로 진행한 드문 증례이다. 감염이 중증인 경우에 분자방법을 이용한 곰팡이의 정확하고 빠른 식별이 조기치료를 위해 필요할 수 있고, 더 많은 사례가 임상적으로 평가되어야 할 것이다.

## Conflicts of Interest

None declared.

## REFERENCES

1. Spellberg B, Edwards J, Ibrahim A. Novel perspectives on mucormycosis: pathophysiology, presentation, and management. Clin Microbiol Rev 2005;18:556-69.
2. Roden MM, Zaoutis TE, Buchanan WL, Knudsen TA, Sarkisova TA, Schaufele RL, et al. Epidemiology and outcome of zygomycosis: a review of 929 reported cases. Clin Infect Dis 2005;41:634-53.
3. Petrikos G, Skiada A, Lortholary O, Roilides E, Walsh TJ, Kontoyannis DP. Epidemiology and clinical manifestations of mucormycosis. Clin Infect Dis 2012;54:S23-34.
4. Katragkou A, Walsh TJ, Roilides E. Why is mucormycosis more difficult to cure than more common mycoses? Clin Microbiol Infect 2014;20:74-81.
5. Monecke S, Hochauf K, Gottschlich B, Ehrlich R. A case of peritonitis caused by *Rhizopus microsporus*. Mycoses 2006;49:139-42.
6. Hyvernart H, Dunais B, Burel-Vandenbos F, Guidicelli S, Bernardin G, Gari-Toussaint M. Fatal peritonitis caused by *Rhizopus microsporus*. Med Mycol 2010;48:1096-8.
7. Kumar C, Jain P, Wadhwa N, Diwaker P, Nirupma Panikar K. Nosocomial jejunal mucormycosis - an unusual cause of perforation peritonitis. Iran J Pathol 2017;12:295-300.
8. Clinical and Laboratory Standards Institute. Interpretive criteria for identification of bacteria and fungi by DNA target sequencing: Approved guideline. CLSI document MM18-A. Wayne, PA: Clinical and Laboratory Standards Institute, 2008.
9. Hartnett KP, Jackson BR, Perkins KM, Glowicz J, Kerins JL, Black SR, et al. A guide to investigating suspected outbreaks of mucormycosis in healthcare. J Fungi (Basel) 2019;5:E69.
10. Polo JR, Luño J, Menarguez C, Gallego E, Robles R, Hernandez P. Peritoneal mucormycosis in a patient receiving continuous ambulatory peritoneal dialysis. Am J Kidney Dis 1989;13:237-9.
11. Nannini EC, Paphitou NI, Ostrosky-Zeichner L. Peritonitis due to *Aspergillus* and *zygomycetes* in patients undergoing peritoneal dialysis: report of 2 cases and review of the literature. Diagn Microbiol Infect Dis 2003;46:49-54.
12. Serna JH, Wanger A, Dosekun AK. Successful treatment of mucormycosis peritonitis with liposomal amphotericin B in a patient on long-term peritoneal dialysis. Am J Kidney Dis 2003;42:E14-7.
13. Pimentel JD, Dreyer G, Lum GD. Peritonitis due to *Cunninghamella bertholletiae* in a patient undergoing continuous ambulatory peritoneal dialysis. J Med Microbiol 2006;55:115-8.

14. Bhutada K, Borkar SS, Mendiratta DK, Shende VR. Successful treatment of peritonitis by *C. bertholletiae* in a chronic kidney failure patient on continuous ambulatory peritoneal dialysis after kidney rejection. Singapore Med J 2012;53:e106-9.
15. Lee SC, Billmyre RB, Li A, Carson S, Sykes SM, Huh EY, et al. Analysis of a food-borne fungal pathogen outbreak: virulence and genome of a *Mucor circinelloides* isolate from yogurt. mBio 2014;5:e01390-14.
16. Cornely OA, Arikan-Akdagli S, Dannaoui E, Groll AH, Lagrou K, Chakrabarti A, et al. ESCMID and ECMM joint clinical guidelines for the diagnosis and management of mucormycosis 2013. Clin Microbiol Infect 2014;20 Suppl 3:5-26.
17. Tissot F, Agrawal S, Pagano L, Petrikos G, Groll AH, Skiada A, et al. ECIL-6 guidelines for the treatment of invasive candidiasis, aspergillosis and mucormycosis in leukemia and hematopoietic stem cell transplant patients. Haematologica 2017;102:433-44.
18. Yang M, Lee JH, Kim YK, Ki CS, Huh HJ, Lee NY. Identification of Mucorales from clinical specimens: a 4-year experience in a single institution. Ann Lab Med 2016;36:60-3.