



## Erratum: Effect of needle approach to the axillary artery on transarterial axillary brachial plexus block quality

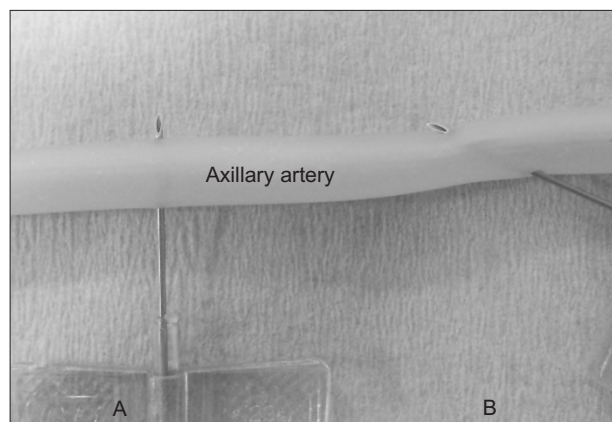
Young Jin Chang<sup>1</sup>, Dong Chul Lee<sup>1</sup>, Young Jun Oh<sup>2</sup>, Dong Hun Ha<sup>2</sup>, and Mi Geum Lee<sup>1</sup>

<sup>1</sup>Department of Anesthesiology and Pain Medicine, Gachon University Gil Medical Center, Incheon, <sup>2</sup>Department of Anesthesiology and Pain Medicine, Yonsei University College of Medicine, Seoul, Korea

Anesth Pain Med 2017;12:357-362

<https://doi.org/10.17085/apm.2017.12.4.357>

Figure 1 was printed with incorrect text. In the Figure, “Radial artery” should be corrected to “Axillary artery.”  
The corrected figure is shown below.



**Fig. 1.** Perpendicular approach group (PA group) versus the shallow needle approach group (SA group). When the scalp vein needle (23 G, 3/4') was advanced into the axillary artery, the needle was directed perpendicular to the axillary artery in the PA group (A), whereas in the SA group, a shallow needle approach to the axillary artery was used (B).