

Ultrasound–guided superficial cervical plexus block for carotid endarterectomy in a patient with Lemierre syndrome

–A case report–

Department of Anesthesiology and Pain Medicine, Jeju National University Hospital, Jeju, *Gachon University Gil Medical Center, Incheon, Korea

Yun Suk Choi, Youn Yi Jo*, Wol Seon Jung*, and Mi Geum Lee*

A 70-year-old woman with an infectious thrombus in her left internal jugular vein (IJV) underwent carotid endarterectomy for stenosis and a highly movable plaque in her right carotid artery. She had been treated with antibiotics for four weeks before surgery due to Lemierre syndrome, a rare septic thrombophlebitis in the IJV secondary to an oropharyngeal infection. The right IJV was in a two-fold dilated state due to compensation for a thrombotic left IJV. Accordingly, superficial cervical plexus block was performed under ultrasound guidance to ensure safety and accuracy. During surgery, the alertness was maintained and the patient did not complain of pain in the absence of additional analgesics. No block-related complications were encountered. The authors report for the first time their regional anesthetic experiences in a patient with Lemierre syndrome. (*Anesth Pain Med* 2016; 11: 345-348)

Key Words: Carotid endarterectomy, Lemierre syndrome, Superficial cervical plexus block.

Lemierre syndrome is characterized by acute oropharyngeal infection resulting in thrombophlebitis of the internal jugular vein (IJV), leading to metastatic septic embolization and bacteraemia [1-3]. In the preantibiotic era, Lemierre syndrome was considered fatal (a mortality rate of ~90%), but the introduction of penicillin significantly reduced mortality rates [2-4]. Lemierre syndrome used to be regarded as a “forgotten

disease”, but unfortunately, its incidence has actually increased because of recent restrictions of the use of antibiotics for oropharyngeal infections [1,4]. The syndrome can only be diagnosed if the clinician has a high degree of suspicion [2,3]. The anesthetic management of these patients remains challenging because of comorbid metastatic infections, difficulties securing an airway due to neck infection, and the risk of embolic infarction from the IJV [1,5]. Some reports describe narrowing of the carotid artery complicated by Lemierre syndrome [1] or cerebral infarction secondary to Lemierre syndrome [6], but no previous report has been issued describing the anesthetic management of carotid endarterectomy (CEA) in the patient with Lemierre syndrome.

Here, we report on our regional anesthetic experience of an ultrasound-guided superficial cervical plexus block in a patient with Lemierre syndrome.

CASE REPORT

A 70-year-old, 48 kg, 153 cm tall woman with a history of hypertension and diabetes was transferred to our hospital for carotid endarterectomy from other hospital, where she had been diagnosed with Lemierre syndrome. Approximately one month before admission to our hospital, she suffered from acute tonsillitis and left otitis media, which progressed to secondary septic phlebitis to her left IJV. Head and neck CT showed diffuse thrombosis in the left IJV and left sigmoid sinus (Fig. 1), and chest radiographs showed bilateral pleural effusion. Blood culture was positive for *Klebsiella pneumoniae*. At the other hospital, she had received intensive care unit (ICU) care with antibiotics for four weeks, and her septic condition and fever had subsided, but the infectious thrombus in her left IJV remained. In addition, right carotid artery stenosis was found

Received: March 18, 2016.

Revised: June 17, 2016.

Accepted: June 29, 2016.

Corresponding author: Mi Geum Lee, M.D., Ph.D., Department of Anesthesiology and Pain Medicine, Gachon University Gil Medical Center, Namdong-daero 774 beon-gil, Namdong-gu, Incheon 21565, Korea. Tel: 82-32-460-3636, Fax: 82-32-469-6319, E-mail: mikeum2@gilhospital.com

This is an Open Access article distributed under the terms of the Creative Commons Attribution Non-Commercial License (<http://creativecommons.org/licenses/by-nc/4.0>) which permits unrestricted non-commercial use, distribution, and reproduction in any medium, provided the original work is properly cited.

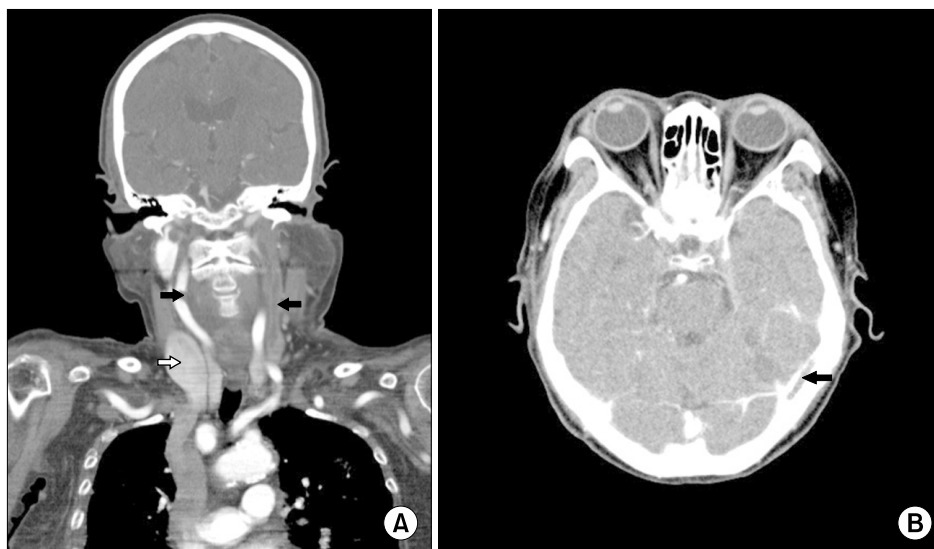


Fig. 1. (A) Head and neck CT image showing thrombosis in the left IJV (left black arrow) and a markedly dilated right IJV (right white arrow) caused by compensation for the thrombotic left IJV, and stenosis of the carotid artery (right black arrow) in frontal view. (B) Image showing thrombosis in the left sigmoid sinus (arrow) in axial view. IJV: internal jugular vein.

incidentally by head and neck CT (Fig. 1), on completing ICU care, she was transferred to our hospital, because it was closer to her hometown. After admission, carotid Doppler ultrasonography revealed a highly movable atheroma reminiscent of impending embolic plaque and 54% stenosis of the right carotid artery, and as a result was scheduled for right carotid endarterectomy. From the day of admission, she was provided heparinization until 6 h before surgery, and was alert with no neurological symptoms.

In the operating room, standard monitoring devices were applied and resuscitation equipment (lipid emulsion, vasoactive drugs, and intubation devices) were prepared. Her initial blood pressure (BP) and heart rate (HR) were 186/119 mmHg and 109 beats/min, and thus, nicardipine 600 µg and esmolol 40 mg were injected intravenously and nitroglycerin 0.5 µg/kg/min was administered by continuous intravenous infusion. Her BP and HR then decreased to 148/75 mmHg and 98 beats/min, respectively. Before starting cervical plexus block, alfentanil 250 µg was administered intravenously for anxiety and pain relief. An arterial line was inserted under local anesthesia into the left radial artery for continuous blood pressure monitoring and near infrared spectroscopy was used to monitor regional cerebral oxygen saturation (rSO₂).

The patient was placed in the supine position with head turned toward the non-operative side; 5 L/min of oxygen was provided using a facial mask. Skin was disinfected with povidone-iodine solution and dried, sterile vinyl was applied to the transducer. A 10 MHz linear ultrasound transducer (Z-one; Zonare Medical Systems, USA) was positioned at their-

tersection of sternocleidomastoid muscle (SCM) muscle and EJV in the transverse position [7]. Survey ultrasound visualized the SCM, carotid artery (CA), IJV, and levator scapulae muscle (LSM). Under ultrasound visualization, a 25-gauge, 2.54-cm needle attached to a 10 ml syringe containing local anesthetics (LA; 1.5% lidocaine 10 ml and 0.53% ropivacaine 20 ml, mixed with epinephrine [1 : 200,000]) was advanced to the posterior border of the SCM to penetrate investing cervical fascia (Fig. 2A). After negative aspiration, 15 ml of LA was injected. The transducer was then moved along the posterior border of the SCM vertically, and a total of 10 ml of LA was injected in a caudad and cephalad direction (Fig. 2B), and another 5 ml of LA was injected subcutaneously fan-like along the anterior fascia of the SCM muscle without ultrasound guidance. Ten minutes after the superficial cervical plexus block, blockade success was confirmed with a pin-prick test along the right side of the neck (C2-4 dermatomes). Having confirmed that the surgical site was fully anesthetized, surgery was initiated.

A skin incision was made along the course of the carotid artery, and the surgeon then injected 1.5% lidocaine 5 ml at the bifurcation site of the common carotid artery. Before cross-clamping, heparin 5,000 IU was administered intravenously. During 16 min of cross-clamping without a shunt, the patient was challenged to provide her name and age, and to count from one to ten. In addition, the anesthesiologist held her left hand and asked her to grasp it firmly to test her hand grip power every 1 min for 16 min. After removing the thrombus (sized 1.4 × 0.4 × 0.5 cm) in the carotid bulb, the 100-min

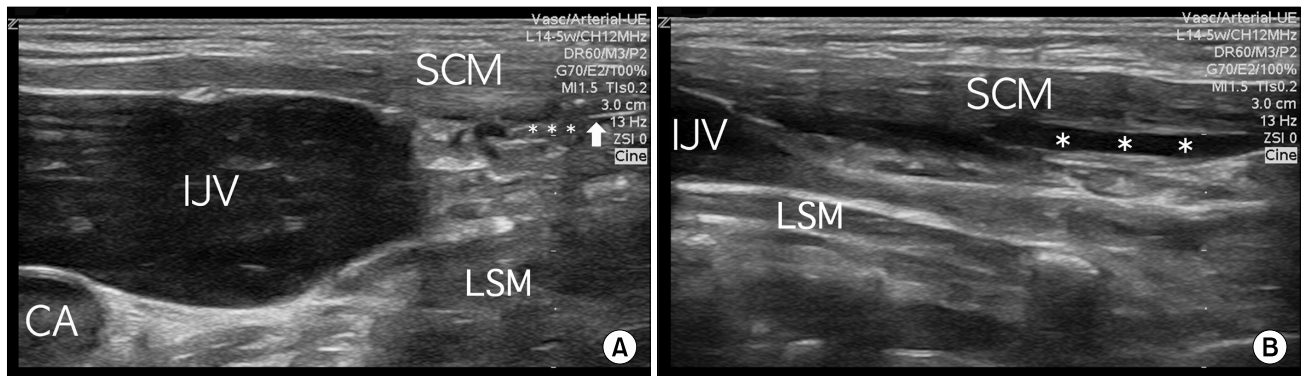


Fig. 2. (A) A 10 MHz linear transducer was positioned at the intersection of the SCM and external jugular vein in transverse position. Survey ultrasound scan showing the SCM, CA, IJV, and LSM. A 25-gauge, 2.54-cm needle (arrow) connected to a 10 ml syringe containing local anesthetic was advanced to the posterior border of the SCM muscle with penetration of the investing cervical fascia (asterisk). The right IJV was dilated to compensate for the left thrombotic IJV. (B) The transducer was then moved along the posterior border of the SCM vertically, and a total of 10 ml of local anesthetic was injected (asterisk) in a caudad and cephalad direction at the posterior border of the SCM. CA: Carotid artery, IJV: Internal jugular vein, LSM: Levator scapulae muscle, SCM: Sternocleidomastoid muscle.

operative procedure was finished. During the operation, vital signs were maintained at BP 130/70–150/90 mmHg, HR 80–90 beats/min, SaO₂ 100%, and rSO₂ 60–70% (baseline 63%). The patient did not suffer any cardiopulmonary or neurologic complication during her 7-day postoperative hospital stay.

DISCUSSION

Lemierre syndrome is diagnosed using four criteria: (1) a recent oropharyngeal infection, (2) clinical or radiological evidence of IJV thrombosis, (3) isolation of anaerobic pathogens, and (4) evidence of at least one septic focus (usually located in a lung) [3,4]. Initial recognition of venous thrombosis with appropriate antibiotic treatment can prevent life-threatening septic emboli [1,5], but successful treatment with antibiotics does not guarantee full resolution of a pre-existing infectious thrombosis in the IJV [5,6]. Furthermore, the effect of anticoagulation in this syndrome remains controversial [2,3].

We chose to use a regional block rather than general anesthesia for carotid endarterectomy for two reasons. First, general anesthesia is considered to be associated with a greater risk of deep vein thrombosis than regional anesthesia [8]. Second, the surgeon wanted the patient to remain alert during surgery to detect neurologic signs of pre-existing thrombus-related embolism and to monitor her neurological status during clamping.

When outcomes associated with new neurologic impairment were compared, it was not clear whether regional anesthesia was better than general anesthesia for carotid endarterectomy

[9,10]. However, regional anesthesia is considered to be better with regard to monitoring neurological status during carotid artery clamping [9,11], and regional block has been associated with more perioperative hemodynamic stability than general anesthesia [12,13], and our patient was hemodynamically stable during the operation.

We chose to use an ultrasound-guided superficial cervical plexus block without deep block. The superficial cervical branches that supply skin and subcutaneous tissues of the neck are sensory, and thus, do not provide neck muscle relaxation and it does not affect the carotid endarterectomy [11]. Furthermore, deep block has a high risk of involving deep structures, such as, the carotid and vertebral arteries, the phrenic nerve, and dura mater, thus, it has a higher rate of conversion to general anesthesia than superficial block [11,14]. We confirmed that LA did not infiltrate deep-neighboring structures such as the IJV or carotid artery by real time ultrasound. Ultrasound guidance does not guarantee the success of cervical plexus block [11], but our patient had a dilated right IJV in the operative site due to compensation for the thrombotic left IJV (Fig. 1), and thus, a blind technique would have introduced the risk of accidental puncture of the enlarged IJV.

Regional anesthesia would appear to be associated with a higher risk of additional infection than general anesthesia because of the needle penetration required during the block procedure. However, analysis of available literature indicated that the incidence of infectious complications associated with peripheral block is extremely low, particularly when a single

shot procedure is used [15]. Furthermore, pre-existing infectious conditions in our patient did not increase the risk of another infection during regional anesthesia [15]. Because she had only recently recovered from a septic condition, meticulous attention was paid to ensure an aseptic technique when the block was performed.

Summarizing, we successfully anesthetized a patient with an excessively dilated right IJV at her operative site due to compensation for a thrombotic left IJV constituting Lemierre syndrome using an ultrasound-guided superficial cervical plexus block. Consciousness was maintained throughout the procedure without complaint of pain, and hemodynamic stability was achieved during surgery without block-related complications.

ACKNOWLEDGMENTS

This research was supported by the 2016 Scientific Promotion Program funded by Jeju National University.

REFERENCES

- Westhout F, Hasso A, Jalili M, Afghani B, Armstrong W, Nwagwu C, et al. Lemierre syndrome complicated by cavernous sinus thrombosis, the development of subdural empyemas, and internal carotid artery narrowing without cerebral infarction. Case report. *J Neurosurg* 2007; 106(1 Suppl): 53-6.
- Chirinos JA, Lichtstein DM, Garcia J, Tamariz LJ. The evolution of Lemierre syndrome: report of 2 cases and review of the literature. *Medicine (Baltimore)* 2002; 81: 458-65.
- Syed MI, Baring D, Addidle M, Murray C, Adams C. Lemierre syndrome: two cases and a review. *Laryngoscope* 2007; 117: 1605-10.
- Asnani J, Jones S. Case review. Lemierre's syndrome. *J Fam Pract* 2014; 63: 193-6.
- Schubert AD, Hotz MA, Caversaccio MD, Arnold A. Septic thrombosis of the internal jugular vein: Lemierre's syndrome revisited. *Laryngoscope* 2015; 125: 863-8.
- Marulasiddappa V, Tejesh CA. Lemierre's syndrome presenting with septic shock. *Indian J Crit Care Med* 2013; 17: 382-4.
- Herring AA, Stone MB, Frenkel O, Chipman A, Nagdev AD. The ultrasound-guided superficial cervical plexus block for anesthesia and analgesia in emergency care settings. *Am J Emerg Med* 2012; 30: 1263-7.
- Zurawska U, Parasuraman S, Goldhaber SZ. Prevention of pulmonary embolism in general surgery patients. *Circulation* 2007; 115: e302-7.
- Guay J. Regional or general anesthesia for carotid endarterectomy? Evidence from published prospective and retrospective studies. *J Cardiothorac Vasc Anesth* 2007; 21: 127-32.
- Schechter MA, Shortell CK, Scarborough JE. Regional versus general anesthesia for carotid endarterectomy: the American College of Surgeons National Surgical Quality Improvement Program perspective. *Surgery* 2012; 152: 309-14.
- Stoneham MD, Stamou D, Mason J. Regional anaesthesia for carotid endarterectomy. *Br J Anaesth* 2015; 114: 372-83.
- Sternbach Y, Illig KA, Zhang R, Shortell CK, Rhodes JM, Davies MG, et al. Hemodynamic benefits of regional anesthesia for carotid endarterectomy. *J Vasc Surg* 2002; 35: 333-9.
- Yun SH, Park SH. Hyperacute hyperperfusion intracerebral hemorrhage complicating carotid endarterectomy. *Anesth Pain Med* 2011; 6: 357-61.
- Pandit JJ, Satya-Krishna R, Gratton P. Superficial or deep cervical plexus block for carotid endarterectomy: a systematic review of complications. *Br J Anaesth* 2007; 99: 159-69.
- List F, Kessler P, Volk T. Regional anesthesia in patients with pre-existing infections or immunosuppression. *Anaesthesist* 2013; 62: 175-82.