

The double retro-aortic left renal vein

Dong-Soo Kyung¹, Jae-Ho Lee¹, Deuk-Yong Shin², Dae-Kwang Kim^{1,3}, In-Jang Choi¹

¹Department of Anatomy, Keimyung University School of Medicine, ²Department of Occupational and Environmental Medicine, Yeungnam University Hospital, Yeungnam University College of Medicine, ³Institute for Medical Genetics, Keimyung University School of Medicine, Daegu, Korea

Abstract: The renal veins drain the kidney into the inferior vena cava and unite in a variable fashion to form the renal vein. The left renal vein is normally located in front of the aorta. However, the retro-aortic renal vein may course posterior to the aorta due to embryological developmental anomalies. During educational dissection, a rare variation of the left renal vein was found in a 66-year old male cadaver. The double retro-aortic renal veins coursed behind the aorta to drain into the inferior vena cava. The superior retro-aortic renal vein drained into the inferior vena cava at the lower border of the L2 vertebra, and the inferior retro-aortic renal vein drained into the inferior vena cava at the upper border of the L4 vertebra. Such a variant is rare, and is a clinically important observation which should be noted by vascular surgeons, oncologists, and traumatologists.

Key words: Renal veins, Variation, Retro-aortic

Received August 23, 2012; Revised September 28, 2012; Accepted October 25, 2012

Introduction

The renal veins connect the kidney to the inferior vena cava (IVC). They are usually singular to each kidney and located anterior to the aorta. However, because of its embryological development, the anatomy of the renal veins is variable. Various positioning of renal vein have been reported and the retro-aortic renal vein, located posterior to aorta, was also studied by many authors [1-6]. According to previous studies, the incidence of retro-aortic renal vein was reported to be 0.6-3.7% [1-6]. Even though, retro-aortic vein is the common venous variation, it is usually clinically silent. Therefore, it usually remains unnoticed unless discovered accidentally during operation or diagnosis.

Many diagnostic and therapeutic procedures have been carried out in the renal vein and kidney, including venography

and renal transplantation [7]. In addition, retro-aortic renal vein variation has a deep association with renovascular aneurysm, varicocele, inguinal or flank pain, and hematuria [1, 3, 8, 9]. Therefore, retro-aortic renal vein has been the focus of clinicians as well as anatomists.

In the present report, the case of a double retro-aortic left renal vein is described. This variation is rare and has not been reported by dissection. The embryological and clinical significance of this variation are also discussed.

Case Report

Variation in the left renal vein was observed in the 66-year-old Korean male cadaver during educational dissection. The abdominal cavity was opened and abdominal viscera were systemically removed. The renal veins were identified and were traced from the hilum of the kidney to the IVC.

Two left renal veins, instead of coursing anterior to the aorta, passed behind it to drain into the IVC, therefore, these veins were defined as retro-aortic left renal veins (RA-LRV). The two RA-LRVs were defined as superior retro-aortic left renal vein (SRA-LRV) and an inferior retro-aortic left renal vein (IRA-LRV) according to their anatomical position (Fig. 1). The small SRA-LRV drained into the IVC horizontally at

Corresponding author:

In-Jang Choi
Department of Anatomy, Keimyung University School of Medicine,
1095 Dalgubeol-daero, Dalseo-gu, Daegu 704-701, Korea
Tel: +82-53-580-3831, Fax: +82-53-580-3835, E-mail: ijchoi@dsmc.or.kr
*Dong-Soo Kyung and Jae-Ho Lee contributed equally to this work.

the lower border of the L2 vertebra, and IRA-LRV was passed obliquely downwards and drained into the IVC at the upper border of the L4 vertebra. The diameters of the SRA-LRV and IRA-LRV were 1 cm and 2.3 cm, respectively. The left testicular vein was accompanied by the left testicular artery and drained into the bifurcation of the left main renal vein. The left suprarenal vein passed obliquely downwards and drained into left renal vein. Other arteries and veins showed a normal course.

Discussion

We have described the case of two RA-LRV which drained into the IVC at the L2 vertebra and L4 vertebra, respectively. The retro-aortic left renal vein has been studied by many authors [1-6], and its prevalence is presented in Table 1. Among various authors, Hoeltl et al. [2] classified retro-aortic renal veins as two main types, according to the obliteration type of embryonic renal venous collar. Retro-aortic left renal vein type I was developed by the persistence of the left sub-supracardinal anastomosis, the intersupracardinal anastomosis, and the left dorsal renal vein. Type II was developed by the persistence of the left subsupracardinal anastomosis and the supracardinal vein. Hoeltl et al. [2] reported that the frequency of type 1 and type 2 was 0.56% (2/354) on autopsy. On computed tomography (CT), type 1 and type 2 were found in 0.26% (12/4,520) and 0.38% (17/4,520), respectively [2]. The present case showed type 1 and type 2 retro-aortic renal veins together and its frequency was extremely rare.

Two occurrences of retro-aortic renal veins are rare, however, similar cases have been observed by many authors. Koc et al. [9] observed this anomaly, not on cadaver, but on CT, and it was suggested that this condition may be associated with left-sided pelvic congestion syndrome. In the case observed by Anjamrooz et al. [10], the patterns of the two retro-aortic renal veins were similar, however the left testicular vein joined the main renal vein. The left testicular vein in the present case drained into the bifurcation of the left main renal vein. Senecail et al. [7] also reported a similar case with a partially bifid and retro-aortic left renal vein by dissection. However, this variation was a bifid form of the renal vein only, which appearance was not considered as the persistence of circumaortic venous ring, as the embryogenesis of renal vein system. Therefore, this is the first report with double retro-aortic renal vein connected to the testicular vein.

To understand the development of this variation, the

Table 1. Frequency of retro-aortic renal vein anomalies according to various authors

Reference	Type	Material	No. (%)
Reed et al. [5]	RA-LRV	CT	8/433 (1.8)
Hoeltl et al. [2]	RARV	CT	29/4,520 (0.6)
	RARV	Operation	6/215 (2.8)
	RARV	Dissection	4/354 (1.1)
Martinez-Almagro et al. [4]	RA-LRV	CT	4/170 (2.4)
	RA-LRV	Dissection	2/116 (1.7)
Trigaux et al. [6]	RARV	CT	38/1014 (3.7)
Arslan et al. [1]	RA-LRV	CT	19/1125 (1.7)
Karazincir et al. [3]	RA-LRV	US	3/137 (2.2)

RA-LRV, retroaortic left renal vein; CT, computed tomography; RARV, retro-aortic renal vein; US, ultrasonography.

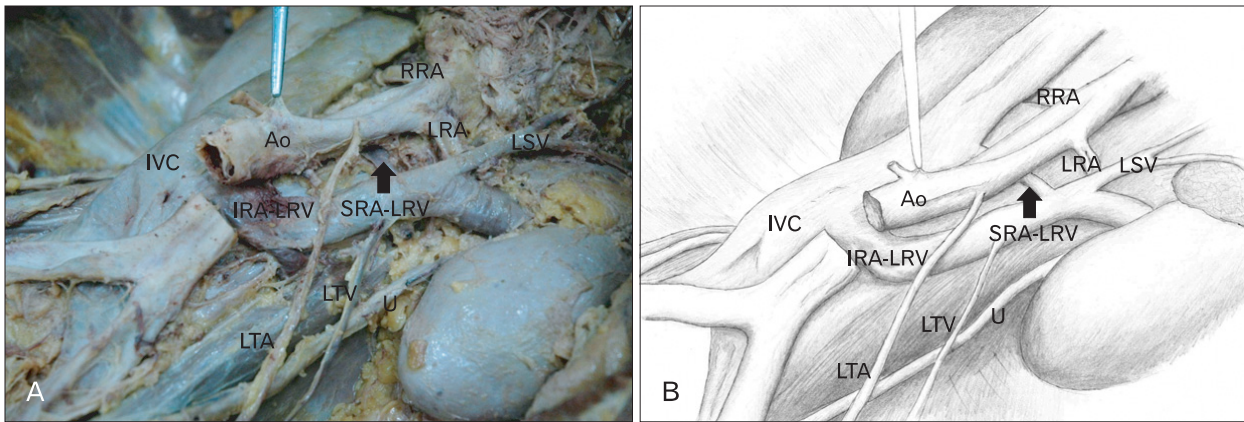


Fig. 1. Photograph (A) and schematic drawing (B) showing double retro-aortic left renal vein. Two retro-aortic left renal veins (SRA-LRV and IRA-LRV) were drained into inferior vena cava. Ao, aorta; IRA-LRV, inferior retro-aortic left renal vein; IVC, inferior vena cava; LRA, left renal artery; LSV, left suprarenal vein; LTA, left testicular artery; LTV, left testicular vein; RRA, right renal artery; SRA-LRV, superior retro-aortic left renal vein; U, ureter.

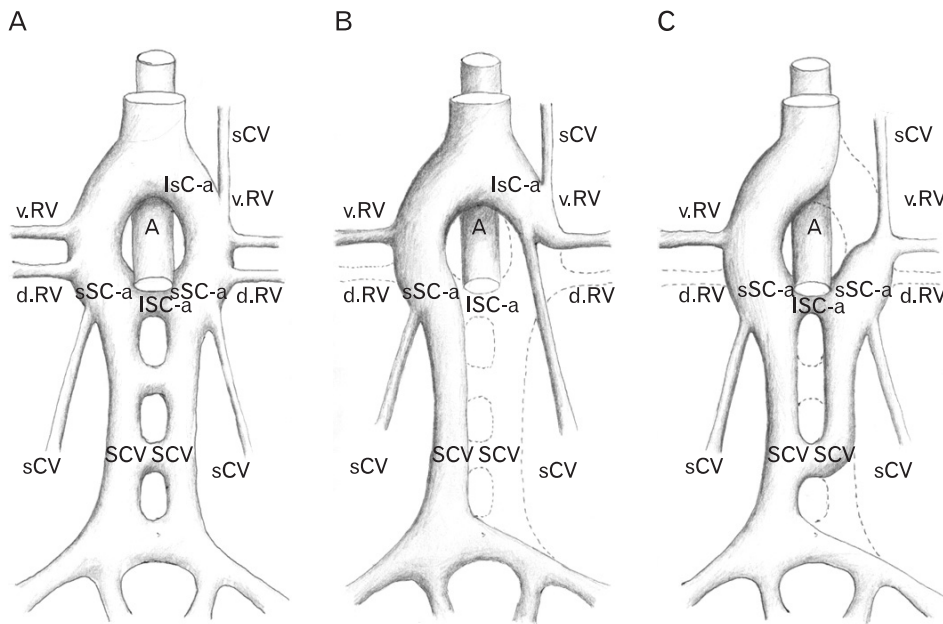


Fig. 2. Drawing of the development of the renal vein. (A) Renal venous collar at 8 week of embryogenesis. (B) Normal development of renal veins in adult. (C) Abnormal development of renal vein in present report. A, aorta; d.RV, dorsal renal vein; IsC-a, intersubcardinal anastomosis; ISC-a, intersupracardinal anastomosis; sCV, subcardinal vein; SCV, supracardinal vein; sSC-a, subsupracardinal anastomosis; v.RV, ventral renal vein.

embryogenesis of the renal vein system should be considered. At 8 weeks of embryogenesis, a circum-aortic venous ring (so-called 'renal collar') is developed completely (Fig. 2A). As development proceeds, certain predestined parts of this primitive venous drainage obliterate, and normal development of renal vein in adult is completed (Fig. 2B). In the present case, the left sub-supracardinal anastomosis, the inter-supracardinal anastomosis, the left ventral renal vein, and left supracardinal vein persisted. The left dorsal renal vein and the inter-subcardinal anastomosis were obliterated. This embryological approach can clearly explain the development of SRA-LRV and IRA-LRV in the present case. Persistence of the left sub-supracardinal anastomosis and the inter-supracardinal anastomosis became SRA-LRV. Persistence of the sub-supracardinal anastomosis on the left side and the left supracardinal vein became IRA-LRV (Fig. 2C).

In the present report, a rare case with double retro-aortic left renal vein was described. Our report may contribute to the expansion of anatomic knowledge in reno-vascular structure because of its rarity. Awareness of venous variations in kidney may be useful because its variation could enhance iatrogenic injuries or complications during several invasive procedures and influence hemodynamic problems with unexplained symptoms [1, 3, 8].

References

1. Arslan H, Etlik O, Ceylan K, Temizoz O, Harman M, Kavan M. Incidence of retro-aortic left renal vein and its relationship with varicocele. *Eur Radiol* 2005;15:1717-20.
2. Hoeltl W, Hruby W, Aharinejad S. Renal vein anatomy and its implications for retroperitoneal surgery. *J Urol* 1990;143:1108-14.
3. Karazincir S, Balci A, Görür S, Sumbas H, Kiper AN. Incidence of the retroaortic left renal vein in patients with varicocele. *J Ultrasound Med* 2007;26:601-4.
4. Martinez-Almagro A, Almenar Garcia V, Martinez Sanjuan V, Hernandez Gil de Tejada T, Lorente Montalvo P. Retroaortic left renal vein: a report of six cases. *Surg Radiol Anat* 1992;14:361-6.
5. Reed MD, Friedman AC, Nealey P. Anomalies of the left renal vein: analysis of 433 CT scans. *J Comput Assist Tomogr* 1982;6:1124-6.
6. Trigaux JP, Vandroogenbroek S, De Wispelaere JF, Lacrosse M, Jamart J. Congenital anomalies of the inferior vena cava and left renal vein: evaluation with spiral CT. *J Vasc Interv Radiol* 1998;9:339-45.
7. Senecail B, Bobeuf J, Forlodou P, Nonent M. Two rare anomalies of the left renal vein. *Surg Radiol Anat* 2003;25:465-7.
8. Nam JK, Park SW, Lee SD, Chung MK. The clinical significance of a retroaortic left renal vein. *Korean J Urol* 2010;51:276-80.
9. Koc Z, Ulsan S, Tokmak N, Oguzkurt L, Yildirim T. Double retroaortic left renal veins as a possible cause of pelvic congestion syndrome: imaging findings in two patients. *Br J Radiol* 2006;79:e152-5.
10. Anjamrooz SH, Azari H, Abedinzadeh M. Abnormal patterns of the renal veins. *Anat Cell Biol* 2012;45:57-61.