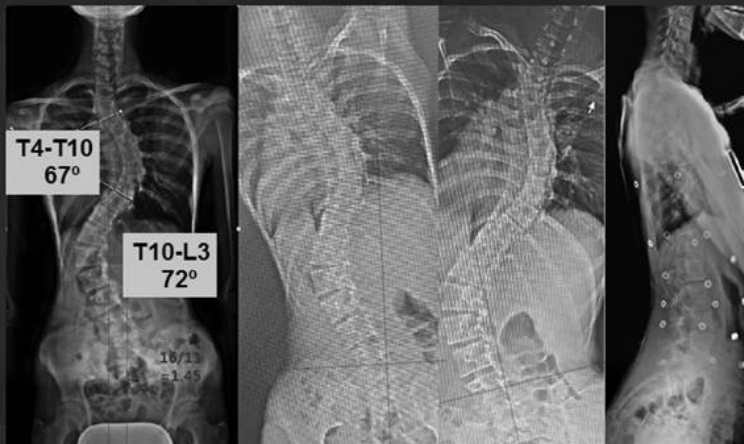
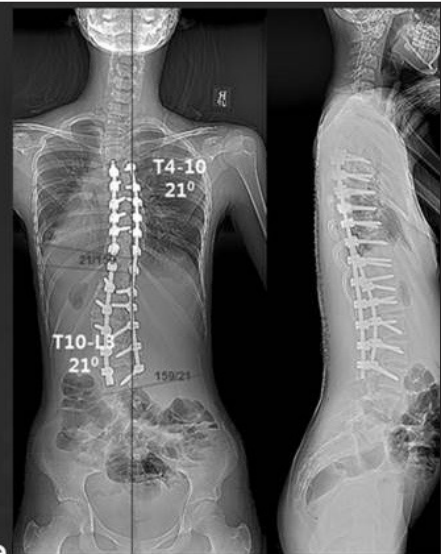


Group 3NS: CLns / Lenke 6C-



F/15, UIV=T4 with right shoulder higher and T4 is the upper end vertebra at major thoracic curve



PSSIF T4- L3

Case 5. 15 year-old-girl with Group 3NS.