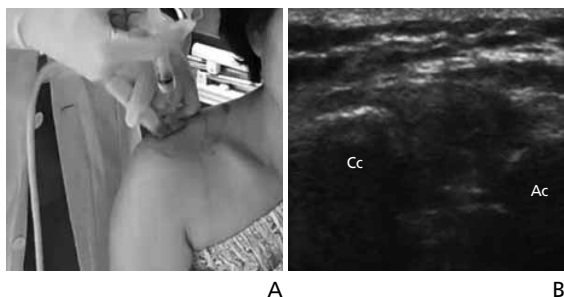


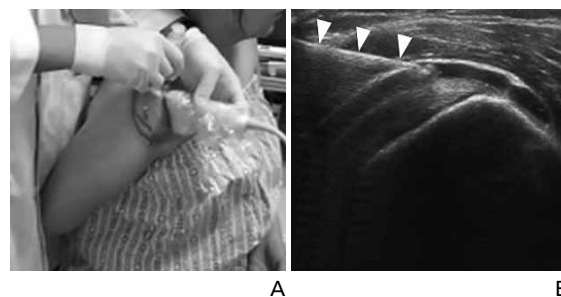
## Erratum

This erratum is being published to correct the printing error on page 210 of the article entitled “Usefulness of musculoskeletal ultrasonography for treatment of shoulder pain” by Jeong WK in J Korean Med Assoc 2016;59(3):205-212. DOI: 10.5124/jkma.2016.59.3.205. ‘Cl’ which is in the Figure 10 was misprinted as ‘Cc’ and Figure 10 and Figure 11 was misprinted as switched each other, and it should be corrected.

### Before correction

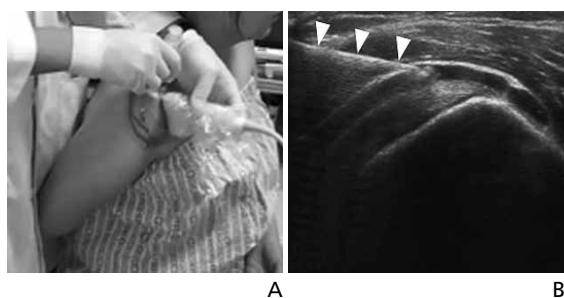


**Figure 10.** Technique (A) and image (B) of ultrasonography guided subacromial bursal injection. Cl, clavicle; Ac, acromion.

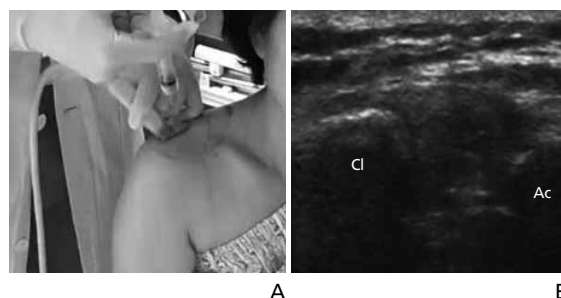


**Figure 11.** Technique (A) and image (B) of ultrasonography guided acromioclavicular joint injection (arrow heads, needle).

### After correction



**Figure 10.** Technique (A) and image (B) of ultrasonography guided acromioclavicular joint injection (arrow heads, needle).



**Figure 11.** Technique (A) and image (B) of ultrasonography guided subacromial bursal injection. Cl, clavicle; Ac, acromion.

대한의사협회지 2016년 3월호에 “견관절 통증의 치료에서 근골격 초음파의 유용성” 논문에서 Figure 10의 Cl이 Cc로 잘못 기재되었고, Figure 10과 Figure 11이 서로 바뀌어서 게재되어 이를 정정합니다.