

Recovery from Acute Respiratory Distress Syndrome with Long-Run Extracorporeal Membrane Oxygenation

Jin Jeon, M.D., Jin Won Huh, M.D., Ph.D.^{*}, Chae-Man Lim, M.D., Ph.D.^{*}, Younsuck Koh, M.D., Ph.D.^{*},
and Sang-Bum Hong, M.D., Ph.D.^{*}

Department of Critical Care Medicine and ^{*}Department of Pulmonary and Critical Care Medicine, Asan Medical Center,
University of Ulsan College of Medicine, Seoul, Korea

Acute respiratory distress syndrome (ARDS) is a severe lung disease associated with high mortality despite recent advances in management. Significant advances in extracorporeal membrane oxygenation (ECMO) devices and management allow short-term support for patients with acute reversible respiratory failure and can serve as a bridge to transplantation in patients with irreversible respiratory failure. When ARDS does not respond to conventional treatment, ECMO and the interventional lung assist membrane (iLA) are the most widely used complementary treatment options. Here, we report a clinical case of an adult patient who required prolonged duration venovenous (VV)-ECMO for severe ARDS resulting in improvement while waiting for lung transplantation.

Key Words: acute respiratory distress syndrome; extracorporeal membrane oxygenation.

The acute respiratory distress syndrome (ARDS) is a severe lung disease associated mortality rate despite recent advances in the management of patients.[1-3] In CESAR trial, ECMO treatment in severe ARDS patient showed a significant improvement in survival at 6 month.[4] Significant advances in ECMO device and management allow short-term support for patients with acute reversible respiratory failure, and bridge to transplantation in patients with irreversible respiratory failure.[5] When ARDS does not respond to conventional treatment, ECMO and the interventional lung assist membrane (iLA) are the devices most widely developed as complementary treatment options. However, there are no established national guideline when to consider futility or

lung transplantation in adult patients requiring ECMO for acute respiratory failure.[6] We report the clinical case of an adult patient who required prolonged duration veno-venous (VV)-ECMO for severe ARDS resulted in improvement during waiting lung transplantation eventually.

Case Report

A 27-year-old healthy man presented with abdominal pain for 5 days. He had a treatment history of pulmonary tuberculosis many years ago. He complained headache, myalgia, and fever up to 38.5°C. Initially, he was admitted to general ward of a tertiary other hospital and performed the abdominal computed tomography (CT). The intestinal tuberculosis or Crohn's disease were suspected in radiologic finding. (His final diagnosis was Crohn's disease) So the patient took the medicine for intestinal tuberculosis (isoniazid, rifampin, etambutol, pyrazinamide). But, his symptom was not improved at all. To find the cause of fever, the attending physicians performed various test including blood culture, cerebrospinal fluid tapping, autoimmune marker. But there

Received on May 15, 2014 Revised on June 26, 2014

Accepted on June 26, 2014

Correspondence to: Sang-Bum Hong, Department of Pulmonary and Critical Care Medicine, Asan Medical Center, University of Ulsan College of Medicine, 88 Olympic-ro 43-gil, Songpa-gu, Seoul 138-736, Korea

Tel: +82-2-3010-4700, Fax: +82-2-3010-4709

E-mail: sbhong@amc.seoul.kr

* No potential conflict of interest relevant to this article was reported.

Table 1. Changes in oxygenation and ventilation and ECMO setting at specific timepoints in patient's recovery course

Week	11	12	13	14	15	16	17	18	19
P/F ratio	19	23	26	25	36	38	27	25	33
Oxygenation index	73	60	77	44	31	29	40	48	36
Tidal volume, ml	167	164	210	132	237	179	205	298	434
Minute ventilation, L/min	2.38	2.3	8.5	4.1	5.4	3.5	4.1	6.8	14.3
Mean airway pressure, mmHg	14	14	20	11	11	11	11	12	12
ECMO									
CI	2.0	2.1	2.2	2.1	2.1	2.3	2.2	2.1	
Flow, L/min	3.39	3.37	3.6	3.42	3.4	3.76	3.7	3.6	

ECMO: extracorporeal membrane oxygenation; CI: cardiac index.

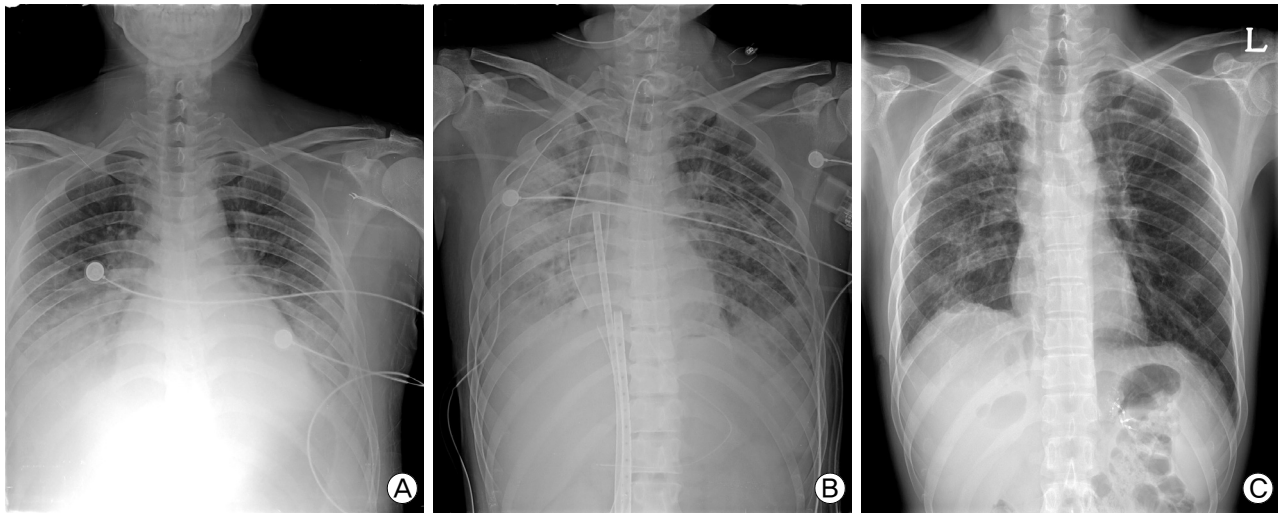


Fig. 1. Chest radiographs initial, extracorporeal membrane oxygenation (ECMO) cannulation, discharge. (A) Initial chest X-ray with dyspnea, patient not intubated with high FiO_2 by facial mask. (B) chest X-ray after ECMO cannulation. (C) chest X-ray at discharge.

were not meaningful results. After 6 days in the hospital, pleural effusion was seen in the chest X-ray (Fig. 1A), and progressive hypoxemia requiring 70% to 100% high-flow oxygen (FiO_2 0.7 with arterial blood gas [ABG] pH 7.31, pCO_2 50 mmHg, PaO_2 77 mmHg) was developed. Empirical broad-spectrum intravenous antibiotics were initiated for presumed hospital acquired pneumonia. Echocardiogram revealed diastolic heart failure due to volume overloading with normal ejection fraction. Chest CT revealed multifocal consolidation indicative of inflammatory lung disease. He developed acute respiratory failure requiring intubation and mechanical ventilation and transferring to intensive care unit (ICU). However, hypoxemia was worsening and hypercarbia was developed, despite advanced mechanical ventilation with increasing PEEP and mean airway pressures (FiO_2 0.7 with ABG pH 7.29, pCO_2 62 mmHg, PaO_2 65 mmHg). After 26 days in the hospital, tension pneumothorax was developed and inserted chest tube. But hypoxemia and hypercarbia became worse (FiO_2 0.7 with ABG pH 6.95, pCO_2 123 mmHg, PaO_2 55 mmHg). So, he was placed on extracorporeal lung assistance (Novalung[®],

GMBH, Germany). However, hypoxemia had not been improved, the patient was placed on veno-venous (VV) ECMO (Fig. 1B). The patient demonstrated no functional lung recovery for 4 weeks of ECMO. He was weaned to pressure support ventilation with minimal tidal volumes. The attending physician suggested lung transplantation, and the patient was transferred to our hospital that lung transplantation surgery is possible. Day by day, the patient's SpO_2 and spontaneous tidal volumes increased, suggesting some recovery of lung function (Table 1). He was successfully weaned from VV-ECMO and was decannulated (total VV-ECMO duration: 85 days). His clinical course is summarized in Fig. 2. His ECMO course was complicated by multiple episodes of *Acinetobacter baumannii* and *Pseudomonas aeruginosa* pneumonia in endotracheal aspiration and blood culture, which were treated by antibiotics for a long time (Fig. 3), and overt bleeding requiring hemoclip and fibrin glue at percutaneous endoscopic gastrostomy site. While maintain the ECMO, the patient did not use the anti-coagulation agent because of consistently thrombocytopenia (platelet < 50,000/ul). The patient's lung function continued to

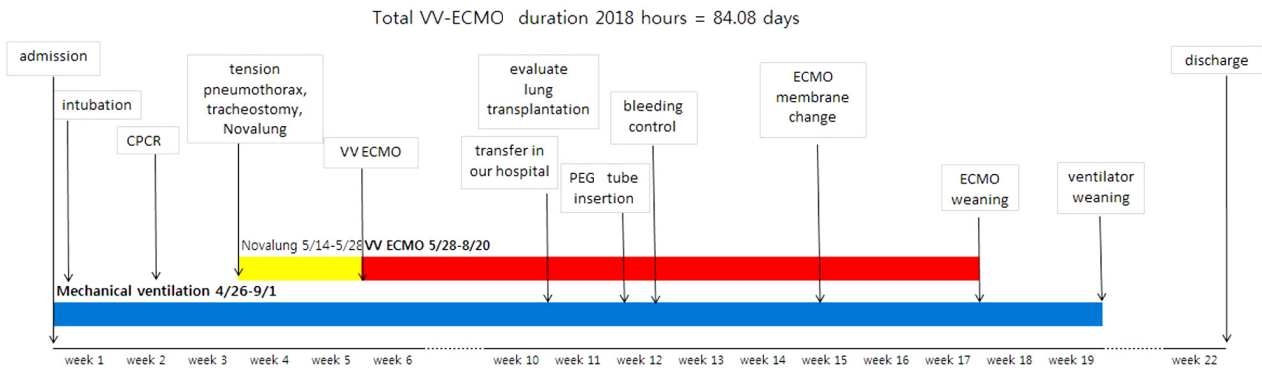


Fig. 2. Patient clinical course. VV: venovenous; ECMO: extracorporeal membrane oxygenation; CPR: cardiopulmonary; cerebral resuscitation; PEG: percutaneous endoscopic gastrostomy.

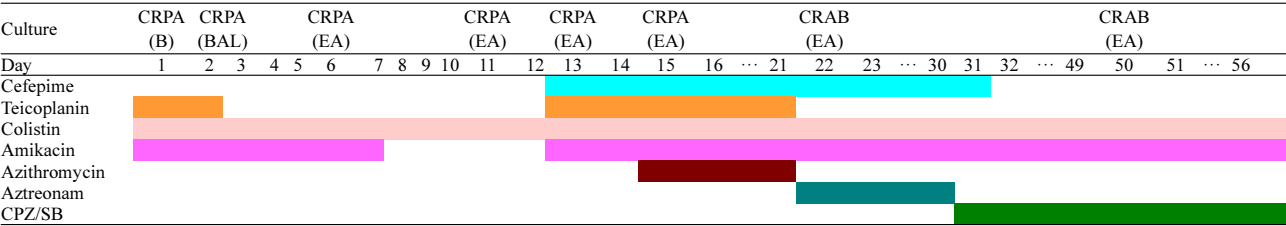


Fig. 3. Timetable of antibiotics and culture. CRPA: carbapenem-resistant *Pseudomonas aeruginosa*; B: blood; BAL: bronchoalveolar lavage; EA: endotracheal aspiration; CRAB: carbapenem-resistant *Acinetobacter baumannii*; CPZ/SB: cefoperazone/sulbactam.

improve, and he was successfully weaned from mechanical ventilation (cumulative ventilator duration: 129 days). He was transferred to the general ward for inpatient rehabilitation. 34 days after discharge from ICU, the patient was discharged home without supplemental oxygen. On follow-up, chest X-ray showed low lung volumes with diffuse interstitial and patchy parenchymal opacities, suggesting sequelae of ARDS (Fig. 1C).

Discussion

In many randomized trial, lung protective strategy including ventilation of lower tidal volume[1] and prone position[7] showed survival benefit in the treatment of ARDS. Recently, ECMO has been widely used for patients with respiratory failure to assist adequate gas exchange in severely damaged lungs, thus allowing the decrease of adjusted tidal volume and preventing the ventilator-induced lung injury. And some papers in support of this were also published. Lewandowski et al.[8], in the non-randomized study, the survival rates of patients treated with ECMO is to demonstrate that it was significantly higher than the control (55% versus 89%, $p < 0.0001$). Hemmila et al.[9] announced the experiments with adult patients with ARDS of 255 treated with ECMO. This study showed the survival rate of 52% of sub-group of patients very serious, patients with ARDS very

strict included. The recently published CESAR study, for the treatment of severe respiratory failure, compares ECMO with the conventional method of ventilation in adults.[10] In the study, 180 patients were randomized to two groups of interventional group (ECMO support) and control group (conventional treatment). The interventional group presented higher survival rate (63% versus 47%) to improving the quality of life in the follow-up of 6 months.[4] However, the above studies were conducted by medical staff with highly experienced ECMO. So, it is necessary to pay attention to interpretation. It is the strongest argument for ECMO is not well established increase in survival associated with this technology. In spite of various studies showing the capacity of ECMO as a gas exchange support system[8,11-13] it is difficult to extend ECMO as a conventional treatment in adults with ARDS for various reasons:[14] the lack of scientific evidence supporting the use of ECMO in adult ARDS patients, bleeding risk by the anticoagulation with heparin,[8,11,13,15,16] and the elevated economic costs along with the need for highly qualified staff. The use of iLA (Novalung®, Germany) in patients previously accepted as candidates for lung transplants, and who during their time on the waiting list suffered an acute worsening of their clinical situation, especially COPD (chronic obstructive pulmonary disease) patients. However, iLA use is reduced recently, the proportion of the use of ECMO has increased. Although both iLA and ECMO can be used in patients with respi-

ratory distress, iLA is less invasive and shows less complications. However, iLA is not suitable for patients with hypoxemia, such a case consider ECMO. The indication for ECMO must be carefully evaluated on a case-by-case basis and be considered as a salvage treatment or complementary treatment option in refractory ARDS. The current paradigm of consideration of lung transplantation because of irreversible lung failure at 2-4 weeks' duration of VV-ECMO and questions the specific time at which /we should consider that there is no likelihood of lung recovery.[6] In spite of various treatments, the patient of ARDS becomes worsening, we can consider lung transplantation. Nowadays, ECMO is not only as a gas exchanger, as well as a bridge to lung transplantation. Many physicians will focus on ECMO. There has been increasing use of ECMO as a bridge to lung transplantation; however, chronic lung disease, particularly pulmonary fibrosis, is the most common indication not ARDS. The role of ECMO as a bridge to lung transplantation has recently been suggested due to advancements in ECMO systems.[17] Recent studies have reported ECMO support for 107 and 110 days.[18-20] In the other case, they report the clinical course of an adult patient who had been evaluated for bridge to lung transplantation and required long-term period VV-ECMO for severe ARDS with the recovery of lung eventually. It demonstrates unexpected lung recovery as the patient was undergoing preparation for possible lung transplantation. The lung may have unexpected regenerative capacity with native lung recovery after prolonged mechanical support, similar to acute kidney injury and renal recovery.[6] In our case, in consideration of lung transplantation, the patients were transferred to our hospital. Although tidal volume was low, chest X-ray was improved day by day. Because the patient was young and no chronic lung disease, we were waiting for natural recovery.

Lung transplantation in the refractory ARDS patients may be considered as treatment option if the patient was young and previous healthy. If the patient does not have chronic lung disease and can expect reversibility, we recommend that the patient can expect the recovery of lung function applying lung protective strategy and long-run ECMO.

References

- 1) Meade MO, Cook DJ, Guyatt GH, Slutsky AS, Arabi YM, Cooper DJ, et al: Ventilation strategy using low tidal volumes, recruitment maneuvers, and high positive end-expiratory pressure for acute lung injury and acute respiratory distress syndrome: a randomized controlled trial. *JAMA* 2008; 299: 637-45.
- 2) Mercat A, Richard JC, Vielle B, Jaber S, Osman D, Diehl JL, et al: Positive end-expiratory pressure setting in adults with acute lung injury and acute respiratory distress syndrome: a randomized controlled trial. *JAMA* 2008; 299: 646-55.
- 3) Rubenfeld GD, Herridge MS: Epidemiology and outcomes of acute lung injury. *Chest* 2007; 131: 554-62.
- 4) Peek GJ, Mugford M, Tiruvoipati R, Wilson A, Allen E, Thalanany MM, et al: Efficacy and economic assessment of conventional ventilatory support versus extracorporeal membrane oxygenation for severe adult respiratory failure (CESAR): a multicentre randomised controlled trial. *Lancet* 2009; 374: 1351-63.
- 5) MacLaren G, Combes A, Bartlett RH: Contemporary extracorporeal membrane oxygenation for adult respiratory failure: life support in the new era. *Intensive Care Med* 2012; 38: 210-20.
- 6) Rosenberg AA, Haft JW, Bartlett R, Iwashyna TJ, Huang SK, Lynch WR, et al: Prolonged duration ECMO for ARDS: futility, native lung recovery, or transplantation? *ASAIO J* 2013; 59: 642-50.
- 7) Guérin C, Reignier J, Richard JC, Beuret P, Gacouin A, Boulain T, et al: Prone positioning in severe acute respiratory distress syndrome. *N Engl J Med* 2013; 368: 2159-68.
- 8) Lewandowski K, Rossaint R, Pappert D, Gerlach H, Slama KJ, Weidemann H, et al: High survival rate in 122 ARDS patients managed according to a clinical algorithm including extracorporeal membrane oxygenation. *Intensive Care Med* 1997; 23: 819-35.
- 9) Hemmila MR, Rowe SA, Boules TN, Miskulin J, McGillicuddy JW, Schuerer DJ, et al: Extracorporeal life support for severe acute respiratory distress syndrome in adults. *Ann Surg* 2004; 240: 595-605; discussion 605-7.
- 10) Peek GJ, Clemens F, Elbourne D, Firmin R, Hardy P, Hibbert C, et al: CESAR: conventional ventilatory support vs extracorporeal membrane oxygenation for severe adult respiratory failure. *BMC Health Serv Res* 2006; 6: 163.
- 11) Conrad SA, Rycus PT, Dalton H: Extracorporeal Life Support Registry Report 2004. *ASAIO J* 2005; 51: 4-10.
- 12) Frenckner B, Palmér P, Lindén V: Extracorporeal respiratory support and minimally invasive ventilation in severe ARDS. *Minerva Anesthesiol* 2002; 68: 381-6.
- 13) Michaels AJ, Schriener RJ, Kolla S, Awad SS, Rich PB, Reickert C, et al: Extracorporeal life support in pulmonary failure after trauma. *J Trauma* 1999; 46: 638-45.
- 14) Cardenas VJ Jr, Lynch JE: Mechanical ventilation and acute

- respiratory distress syndrome. *Semin Thorac Cardiovasc Surg* 2006; 18: 8-12.
- 15) Lynch JE, Cheek JM, Chan EY, Zwischenberger JB: Adjuncts to mechanical ventilation in ARDS. *Semin Thorac Cardiovasc Surg* 2006; 18: 20-7.
- 16) Morris AH, Wallace CJ, Menlove RL, Clemmer TP, Orme JF Jr, Weaver LK, et al: Randomized clinical trial of pressure-controlled inverse ratio ventilation and extracorporeal CO₂ removal for adult respiratory distress syndrome. *Am J Respir Crit Care Med* 1994; 149(2 Pt 1): 295-305.
- 17) Jackson A, Cropper J, Pye R, Junius F, Malouf M, Glanville A: Use of extracorporeal membrane oxygenation as a bridge to primary lung transplant: 3 consecutive, successful cases and a review of the literature. *J Heart Lung Transplant* 2008; 27: 348-52.
- 18) Strecker T, Münch F, Weyand M: One hundred ten days of extracorporeal membrane oxygenation in a young woman with postpartum cerebral venous thrombosis and acute respiratory distress syndrome. *Heart Surg Forum* 2012; 15: 180-E181.
- 19) Iacono A, Groves S, Garcia J, Griffith B: Lung transplantation following 107 days of extracorporeal membrane oxygenation. *Eur J Cardiothorac Surg* 2010; 37: 969-71.
- 20) Kim EJ, Paik HC, Park MS, Kim MH, Koh SO, Lee YJ, et al: One hundred seven days of ECMO as a bridge to lung transplantation: the longest duration among elderly patients. *Korean J Crit Care Med* 2014; 29: 48-51.