

Zeynep Canan Özdemir¹, Ayşe Bozkurt Turhan¹,
Makbule Eren², Özcan Bor¹

¹*Division of Pediatric Hematology/Oncology,*

²*Division of Pediatric Gastroenterology,
Hepatology and Nutrition, Faculty of Medicine,
Eskişehir Osmangazi University, Eskişehir, Turkey*

Correspondence to: Zeynep Canan Özdemir

*Division of Pediatric Hematology/Oncology, Eskişehir
Osmangazi University Faculty of Medicine, Meşelik
Kampüs, Osmangazi, 26480 Merkez/Eskişehir, Turkey
E-mail: efecanan@yahoo.com*

Received on Apr. 26, 2016; Revised on Apr. 30, 2016; Accepted on May 31, 2016

<https://doi.org/10.5045/br.2017.52.1.69>

Authors' Disclosures of Potential Conflicts of Interest

No potential conflicts of interest relevant to this article were reported.

REFERENCES

1. Clavell LA, Gelber RD, Cohen HJ, et al. Four-agent induction and intensive asparaginase therapy for treatment of childhood acute lymphoblastic leukemia. *N Engl J Med* 1986;315:657-63.
2. Roesmann A, Afify M, Panse J, Eisert A, Steitz J, Tolba RH. L-carnitine ameliorates L-asparaginase-induced acute liver toxicity in steatotic rat livers. *Chemotherapy* 2013;59:167-75.
3. Alshiekh-Nasany R, Douer D. L-Carnitine for treatment of pegasparaginase-induced hepatotoxicity. *Acta Haematol* 2016; 135:208-10.
4. Al-Nawakil C, Willems L, Mauprivez C, et al. Successful treatment of L-asparaginase-induced severe acute hepatotoxicity using mitochondrial cofactors. *Leuk Lymphoma* 2014;55:1670-4.
5. Pratt CB, Johnson WW. Duration and severity of fatty metamorphosis of the liver following L-asparaginase therapy. *Cancer* 1971;28:361-4.
6. Durden DL, Salazar AM, Distasio JA. Kinetic analysis of hepatotoxicity associated with antineoplastic asparaginases. *Cancer Res* 1983;43:1602-5.
7. Tsuji F, Miyake Y, Aono H, Kawashima Y, Mita S. Effects of buccamine and N-acetyl-L-cysteine on cytokine production and collagen-induced arthritis (CIA). *Clin Exp Immunol* 1999;115: 26-31.
8. Firpi RJ, Nelson DR. Viral hepatitis: manifestations and management strategy. *Hematology Am Soc Hematol Educ Program* 2006:375-80.
9. Nazer LH, Nazer HM. Drug-induced liver injury. In: Elzouki AY, Harfi HA, Nazer H, Oh W, Stapleton FB, Whitley RJ, eds. *Textbook of clinical pediatrics*. 2nd ed. New York, NY: Springer, 2012:2113-7.
10. Zimmerman HJ. *Hepatotoxicity: the adverse effects of drugs and other chemicals on the liver*. 2nd ed. Philadelphia, PA: Lippincott Williams & Wilkins, 1999:673-709.
11. Jaeschke H, Gores GJ, Cederbaum AI, Hinson JA, Pessayre D, Lemasters JJ. Mechanisms of hepatotoxicity. *Toxicol Sci* 2002;65:166-76.
12. Marí M, Morales A, Colell A, García-Ruiz C, Kaplowitz N, Fernandez-Checa JC. Mitochondrial glutathione: features, regulation and role in disease. *Biochim Biophys Acta* 2013;1830: 3317-28.
13. Baumgardner JN, Shankar K, Hennings L, Albano E, Badger TM, Ronis MJ. N-acetylcysteine attenuates progression of liver pathology in a rat model of nonalcoholic steatohepatitis. *J Nutr* 2008;138:1872-9.
14. Samuhasaneeto S, Thong-Ngam D, Kulaputana O, Patumraj S, Klaikeaw N. Effects of N-acetylcysteine on oxidative stress in rats with non-alcoholic steatohepatitis. *J Med Assoc Thai* 2007; 90:788-97.
15. Kaya I, Citil M, Sozmen M, Karapehlivan M, Cigsar G. Investigation of protective effect of L-carnitine on L-asparaginase-induced acute pancreatic injury in male Balb/c mice. *Dig Dis Sci* 2015;60:1290-6.

A case of lymphocytic variant hypereosinophilic syndrome with sub-diagnostic systemic mastocytosis

TO THE EDITOR: A 26-year-old man presented with a 3-year history of progressive arthralgia and joint stiffness. One year ago, he was examined by a chiropractor for intermittent generalized joint pain and a maculopapular rash on his chest. He was referred to a physician because his complete blood cell count (CBC) showed a high eosinophil count. After undergoing a standard workup he was diagnosed with rheumatoid arthritis and given low-dose methotrexate, which was switched to leflunomide as his symptoms did not improve. He was referred to our clinic because of eosinophilia. On admission, he complained of fatigue, night sweats, and arthralgia. His physical examination showed unremarkable results except for a few skin nodules on his left leg. His hemoglobin was 13.9 g/dL and white blood cell (WBC) count was $38.2 \times 10^9/L$, with an absolute eosinophil count of $23.3 \times 10^9/L$ and a platelet count of $330 \times 10^9/L$. The peripheral blood smear differential count showed 61% eosinophils, 15% lymphocytes, and 22% neutrophils. Serum lactate dehydrogenase (LDH) was 1,130 IU/L (range, 313–618 IU/L) and serum interleukin (IL)-5 levels were high while tryptase and IgE levels were normal. The autoimmune, cardiac, and infectious disease work up showed negative results. A bone marrow (BM) aspiration and biopsy revealed hypercellular BM (80%) with trilineage hematopoiesis and a marked increase in eosinophils (66%) (Fig. 1A, B). Eosinophil morphology was largely unremarkable except for mild uneven granulations. There were no mast cell aggregates or lymphocytosis. Multicolor flow cytometry (MFC) analysis detected a small population of aberrant T cells (0.5% of total cells, 4% of lymphocytes) expressing CD2, CD4, and bright CD5, but a complete lack

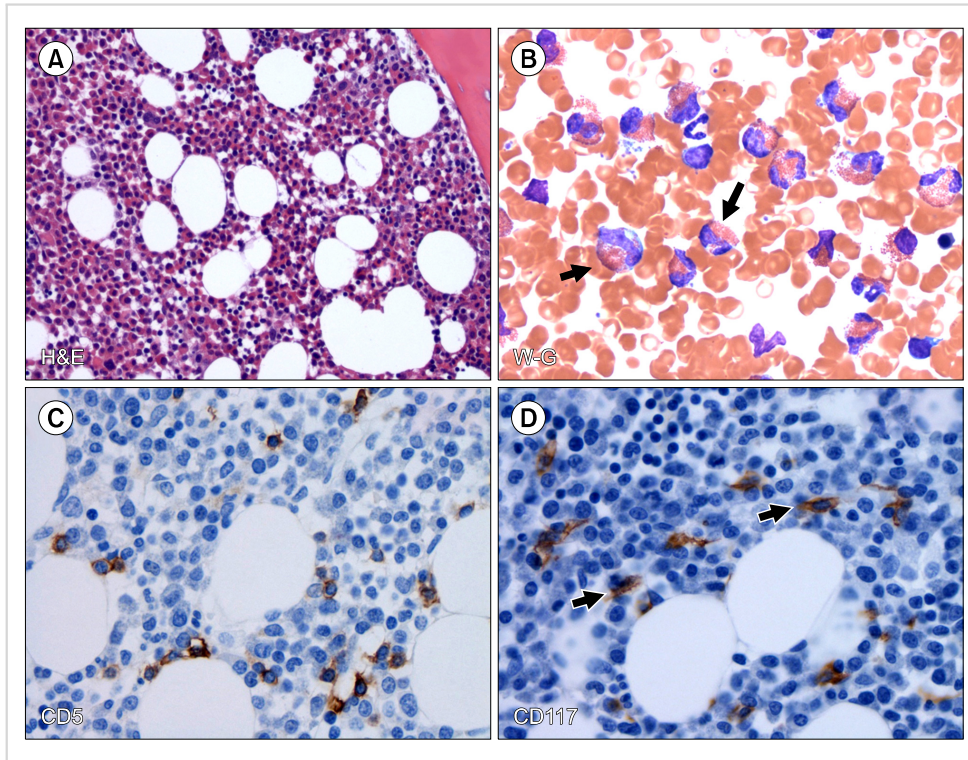


Fig. 1. Morphologic and immunophenotypic features of the bone marrow biopsy and aspirate. **(A)** Bone marrow core biopsy shows hypercellular bone marrow with trilineage hematopoiesis and markedly increased eosinophils (H&E, $\times 200$). **(B)** Bone marrow aspirate smear shows increased eosinophils, black arrows (Wright- Giemsa, $\times 500$). **(C)** Immunohistochemical stain for CD5 shows a few scattered T cells (CD5, $\times 500$). **(D)** Immunohistochemical stain for CD117 shows slightly increased atypical spindle-shaped mast cells (black arrows) with interstitial distribution (500) representing sub-diagnostic mastocytosis.

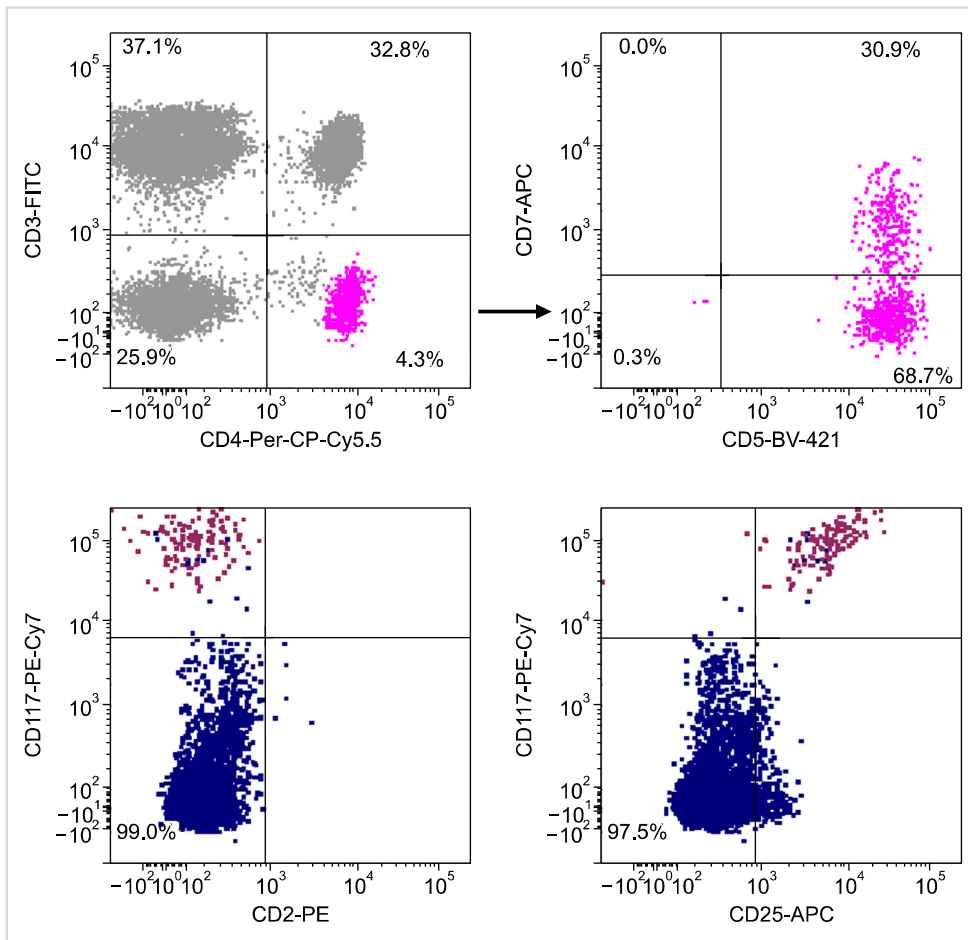


Fig. 2. Flow cytometry analysis of bone marrow aspirate detected a minor population of aberrant T cells (about 0.52% of total cells) co-expressing CD4, CD5 with partial loss of CD7 (upper panel) and CD2 expression (not shown), and an aberrant population of cells co-expressing CD25 and CD117 mast cells (0.04%) (lower panel).

of surface CD3 expression. This population of T cells also showed significant loss of CD7 expression (Fig. 2). In addition, MFC also detected a small population of aberrant mast cells (0.04%) co-expressing CD117 and CD25 (Fig. 2) but negative for CD2 and CD30. Immunohistochemistry on BM biopsy revealed small T cells with normal expression of CD5 (Fig. 1C). Furthermore, CD117 staining highlighted scattered spindle-shaped mast cells (1–2% of total bone marrow cellular elements) (Fig. 1D) and CD25 staining was negative in these cells. There were focally mild increases in reticulin but not in collagen fibrosis. Cytogenetic analysis showed a normal karyotype. Fluorescent in-situ hybridization (FISH) analyses did not detect *PDGFRA* (*CHIC2*), *PDGFRB*, or *FGFR1* gene rearrangements. We could not detect the *FIP1L1-PDGFR* gene fusion transcript by molecular methods. The V- γ 4 T cells with monoclonal T cell receptor gamma chain gene (*TCRG*) rearrangement were detected by PCR. Next generation sequencing (NGS)-based analysis of the BM for 28 specific genes commonly mutated in patients with myeloid malignancies detected a variant with uncertain origin on exon 27 of the *MLL* gene (NM_005933) but no mutation in the *KIT* gene. Real-time PCR did not detect D816V *KIT* gene mutation. Overall, these findings were compatible with a diagnosis of lymphocytic variant hypereosinophilic syndrome (LV-HES). The patient is under observation without curative therapies for LV-HES but only treated with leflunomide for rheumatoid arthritis with adequate symptom control.

Since the aberrant mast cells did not meet the conventional diagnostic criteria of systemic mastocytosis (the presence of compact BM mast cell infiltrates), we concluded that the patient has LV-HES with a sub-diagnostic systemic mastocytosis as described by Pardanani *et al.* [1]. Patients with LV-HES commonly present with cutaneous and rheumatologic manifestations. In addition, the presence of monoclonal T cells with an abnormal immunophenotype and increased levels of Th2 cytokines is common in LV-HES patients [2]. Although these patients generally respond to steroids, some patients respond to imatinib even in the absence of *FIP1L1-PDGFR* rearrangement [3]. Occasionally, LV-HES may transform into an aggressive T cell lymphoma [4]. To the best of our knowledge, LV-HES with co-existing sub-diagnostic mastocytosis has never been described, although clonal mast cells in HES have previously been reported [5]. It is unclear whether these two processes indicate a coincidental finding or have a pathogenic relationship. It is possible that IL-3 secretion by the Th2 cells in LV-HES patients can promote mast cell activation via STAT3 [6]; the STAT3 mutation (Y640F) may co-exist in aberrant T cells and mast cells in LV-HES patients [7].

Preetesh Jain¹, Sa A. Wang², C. Cameron Yin²,
Yasmin Abaza¹, Srdan Verstovsek¹, Zeev Estrov¹

¹Department of Leukemia, ²Department of Hematopathology, The University of Texas, M.D. Anderson Cancer Center, Houston, Texas, USA

Correspondence to: Zeev Estrov

Department of Leukemia, The University of Texas, M.D. Anderson Cancer Center, Unit 428, 1515 Holcombe Boulevard, Houston, Texas 77030, USA
E-mail: zestrov@mdanderson.org

Received on Mar. 2, 2016; Revised on Apr. 11, 2016; Accepted on May 25, 2016

<https://doi.org/10.5045/br.2017.52.1.71>

Acknowledgments

This study was supported in part by the MD Anderson Cancer Center Support Grant CA016672 and Award Number P01 CA049639 from the National Cancer Institute.

Authors' Disclosures of Potential Conflicts of Interest

No potential conflicts of interest relevant to this article were reported.

REFERENCES

1. Pardanani A, Chen D, Abdelrahman RA, et al. Clonal mast cell disease not meeting WHO criteria for diagnosis of mastocytosis: clinicopathologic features and comparison with indolent mastocytosis. *Leukemia* 2013;27:2091–4.
2. Helbig G, Wiczorkiewicz A, Dziaczkowska-Suszek J, Majewski M, Kyrz-Krzemien S. T-cell abnormalities are present at high frequencies in patients with hypereosinophilic syndrome. *Haematologica* 2009;94:1236–41.
3. Christoforidou A, Kotsianidis I, Margaritis D, Anastasiadis A, Douvali E, Tsatalas C. Long-term remission of lymphocytic hypereosinophilic syndrome with imatinib mesylate. *Am J Hematol* 2012;87:131–2.
4. Roufosse F. Peripheral T-cell lymphoma developing after diagnosis of lymphocytic variant hypereosinophilic syndrome: misdiagnosed lymphoma or natural disease progression? *Oral Surg Oral Med Oral Pathol Oral Radiol* 2014;118:506–10.
5. Wiednig M, Beham-Schmid C, Kranzelbinder B, Aberer E. Clonal mast cell proliferation in pruriginous skin in hypereosinophilic syndrome. *Dermatology* 2013;227:67–71.
6. Lantz CS, Boesiger J, Song CH, et al. Role for interleukin-3 in mast-cell and basophil development and in immunity to parasites. *Nature* 1998;392:90–3.
7. Walker S, Wang C, Walradt T, et al. Identification of a gain-of-function STAT3 mutation (p.Y640F) in lymphocytic variant hypereosinophilic syndrome. *Blood* 2016;127:948–51.