



pISSN 2586-3290 · eISSN 2586-3533  
Arch Hand Microsurg 2022;27(3):265-269  
<https://doi.org/10.12790/ahm.22.0002>

**Received:** January 7, 2022

**Revised:** June 30, 2022

**Accepted:** July 13, 2022

### Corresponding author:

Hea Kyeong Shin

Department of Plastic and  
Reconstructive Surgery, Dongguk  
University College of Medicine, 87  
Dongdae-ro, Gyeongju 38067, Korea  
Tel: +82-54-770-1460

Fax: +82-54-770-1469

E-mail: [shinhk@med.dongguk.ac.kr](mailto:shinhk@med.dongguk.ac.kr)

ORCID:

<https://orcid.org/0000-0002-6248-7104>

# Thumb reconstruction with a double flap after thumb replantation failure using a reverse homodigital dorsoulnar flap and a cross-finger flap: a case report

Min Jun Yong<sup>1</sup>, Young Woong Mo<sup>2</sup>, Hea Kyeong Shin<sup>1</sup>

<sup>1</sup>Department of Plastic and Reconstructive Surgery, Dongguk University College of Medicine, Gyeongju, Korea

<sup>2</sup>Department of Plastic and Reconstructive Surgery, Institute for Human Tissue Restoration, Severance Hospital, Yonsei University College of Medicine, Seoul, Korea

After replantation and salvage procedures have failed in a heavy smoker, surgeons are hesitant to consider future strategies. We introduce a case in which the length and function of the right thumb were preserved as much as possible by double flap surgery after replantation failure. The thumb of a 55-year-old man without underlying disease was amputated by an electrical chainsaw at work. He presented at the emergency room of our hospital, and emergency surgery was performed for exploration and stump replantation. Unfortunately, the replantation surgery failed, and the distal stump was necrotized. Thus, double flap surgery was planned after replantation failure, and thumb reconstruction was performed using a reverse homodigital dorsoulnar flap and a cross-finger flap. A portion of the flap later had to be revised, but the functional and aesthetic results obtained were far better than expected for a simple stump revision procedure.

**Keywords:** Amputation, Replantation, Surgical flaps, Thumb

## Introduction

Many industrial hand injuries occurred in the past, but due to the development of safety devices, the number of severe injuries has reduced considerably. Nonetheless, crush injuries or amputations accompanied by soft-tissue defects in the distal digits are not uncommonly encountered. Advances in microsurgical techniques can achieve good results for distal digit injuries of this type, but when soft tissue is severed or a nail is cut distally rather than proximally, the success of microsurgery is doubted.

Multiple reconstructive options, such as metacarpal lengthening, first web space deepening, and locoregional flap (e.g., dorsal hand, reverse radial forearm, or groin flap), may be considered for thumb reconstruction after subtotal amputation of borderline length, as described by an adaptation of Lister's classification. [1]. Abdominal or forearm skin is used as donor material for the distal flap procedure, but since the colors and characteristics of skin tissue differ, it is better to use skin from a similar region for reasons of function, aesthetics, and patient convenience.

If there is a distal stump, replantation should be performed as soon as possible to reduce ischemic time and maximally restore the original state, but if microsurgery fails, the surgeon is faced with a challenge. We introduce a case in which the

length and function of the thumb were preserved as much as possible using a reverse homodigital dorsoulnar [2,3] and a cross-finger [4] flap after amputation of his right thumb.

## Case report

The right thumb of a 55-year-old man without underlying disease was amputated by an electrical chainsaw at work. On visiting the emergency room of our hospital, emergency surgery was performed immediately for exploration and stump replantation. A radiological examination revealed a fracture line at the interphalangeal joint level and complete amputation in extensor zone 1 of his right thumb.

Unfortunately, distal skin necrosis from stump distal pulp occurred 2 days after the operation, and flap compromise of the stump was detected (Fig. 1). A reverse homodigital dorsoulnar flap and a cross-finger double flap were planned to preserve length as much as possible and enable pinch function. With the aid of Doppler ultrasound, the origin and course of the dorsoulnar digital artery were identified, and the pivot point and arterial course were marked.

Necrotic soft tissue of the stump was removed, and arthrodesis of the distal interphalangeal (DIP) joint was performed using Kirschner wires after removing remaining cartilage and osteophytes. Sufficiently redundant soft tissue was used to preserve the length of the thumb as much as possible. The protruding dorsum of defect bone was covered with a reverse homodigital dorsoulnar flap, which was marked out on the dorsoulnar surface of the middle of the snuff box and metacarpophalangeal joints. The pivot point of the flap was marked at

least 0.5 cm away from the DIP joint of the thumb. Skin was incised, and the proximal end of the thumb dorsoulnar artery was ligated. The flap, which contained the dorsoulnar artery, was raised from adductor muscle fascia and extensor tendon, and an adipocutaneous pedicle was dissected from the paratenon; dissection was stopped near the pivot point to prevent anastomosis with perforating vessels. After the flap had been transposed to the dorsal surface of the distal phalanx, it was sutured without tension. The donor defect was covered with a hatchet local flap, and the volar side was covered with a cross-finger flap. This adipofascial flap was raised from the paratenon of the dorsal surface (the zone 4 level) of the index finger. The donor defect of the index finger (zone 4) was covered with a full-thickness skin graft from the right groin, and a bolster dressing was applied. In this manner, a reverse homodigital dorsoulnar flap, a cross-finger flap, hatchet flap, and thumb reconstruction with a full-thickness skin graft were completed (Fig. 2).

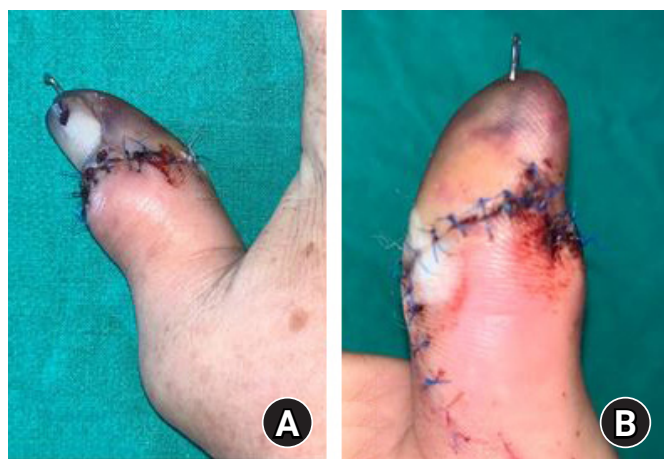Three weeks after flap surgery, flap division and additional flap revision surgery were performed (Fig. 3). Subsequently, the patient was able to perform normal daily activities and returned to work.

Written informed consent was obtained for publication of this report and accompanying images.

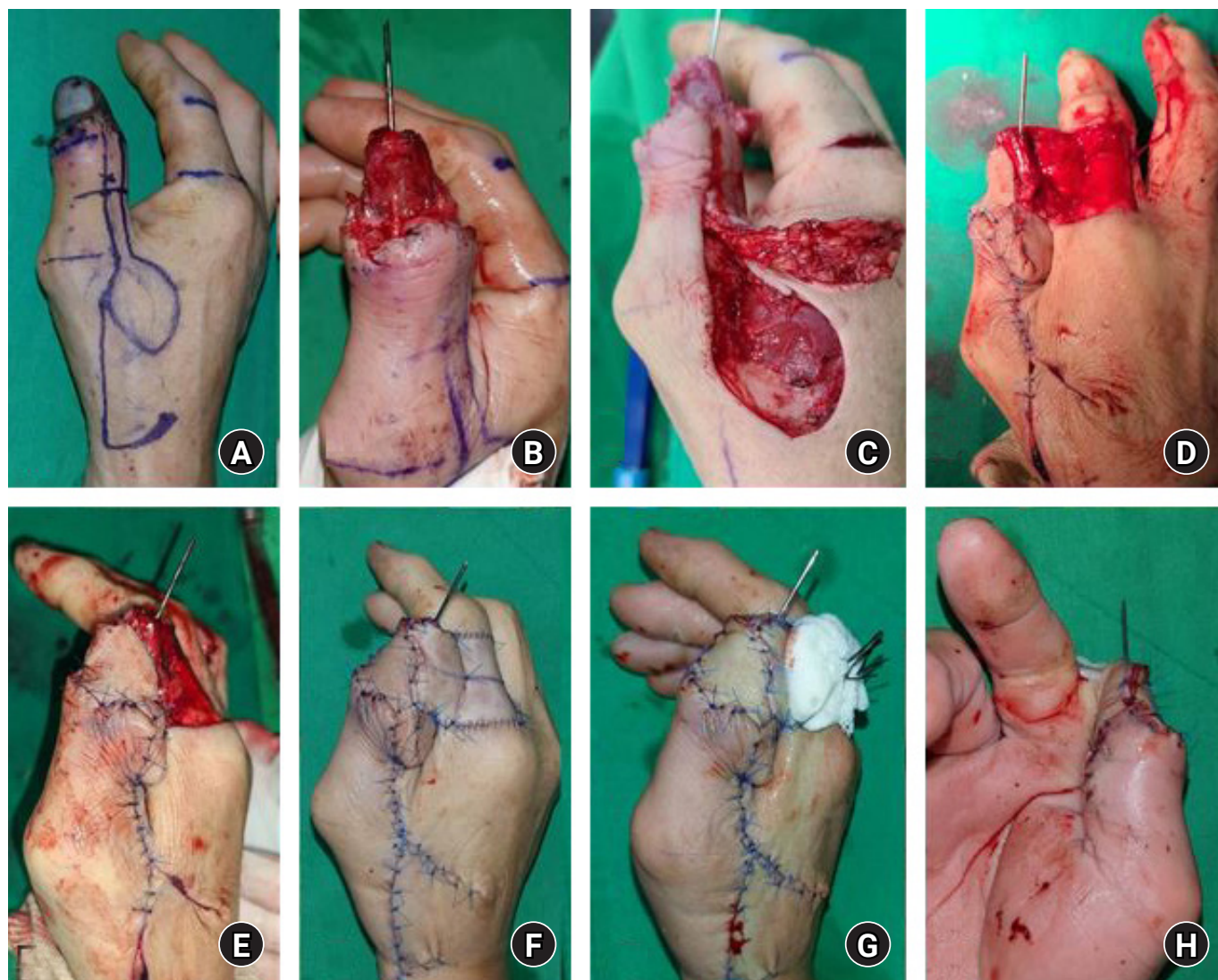
## Discussion

Opposition is the most important difference between the hands of humans and apes. The human hand has three types of grip, that is, pad to side, three-jawed chuck, and five-jawed cradle-chuck grips, and the absence of these functions dramatically restricts daily activities. Opposition is the hallmark of the thumb, and thus, reconstruction necessitates painless stable skin coverage and an acceptable length to enable circumduction [5]. Therefore, operations on injured thumbs are performed such that flexion, opposition, and adduction are made possible by maintaining interphalangeal joint function. Furthermore, when operations are successful, care is taken during rehabilitation to preserve this function, which is the most important goal of treatment.

In clinical practice, when a patient presents with an amputated thumb, the procedure should be performed to preserve length and function of the traumatized hand regardless of a high probability of failure based on considerations of ischemic time, patient age, diabetes mellitus, smoking status, or other contraindications for replantation. However, if surgery fails, decisions regarding the subsequent procedures are problematic.



**Fig. 1.** (A, B) Postoperative photographs showing distal skin necrosis from stump distal pulp 2 days after surgery. Flap compromise at the stump was also detected.



**Fig. 2.** Stump revision surgery after replantation failure showing completed reverse homodigital dorsolateral flap, cross-finger flap, and hatchet flap placement and thumb reconstruction. (A) Homodigital reverse island flap and cross-finger flap were designed for thumb coverage. (B) Necrotic soft tissue of the stump was removed, and arthrodesis of the distal interphalangeal joint was performed using Kirschner wires. (C) A reverse homodigital dorsolateral flap was elevated and transposed to the dorsal surface of distal phalanx. (D, E) Cross-finger flap for volar surface of distal phalanx. (F, G, H) The donor site of the reverse homodigital island flap was covered with hatchet flap. The donor defect of the index finger was covered with full-thickness skin graft and tie-over dressing was applied.

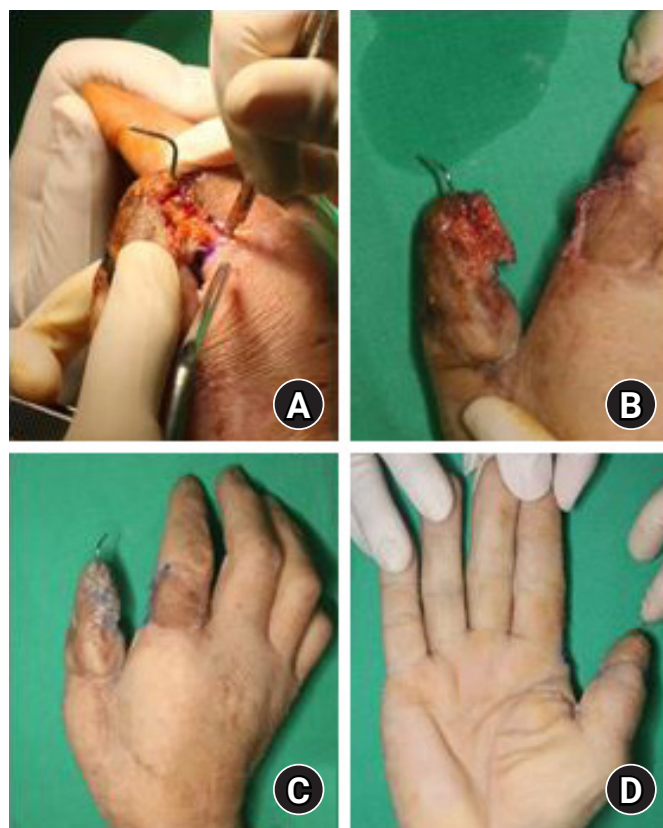
According to Lister's classification, thumb amputations are divided into four functional categories: soft-tissue deficit with acceptable length, subtotal amputation with borderline length, total amputation with preservation of the carpometacarpal joint, and total amputation with destruction of the carpometacarpal joint [6], and this classification facilitates decision-making regarding reconstruction options. The described case would fall into the subtotal amputation with borderline length classification, and multiple reconstructive options are available for such cases, such as metacarpal lengthening, first web space deepening, and locoregional flap placement (e.g., dorsal hand

or reverse radial forearm flap or groin flap) [1].

The most important thing to consider in thumb reconstruction is to ensure that the finger regain normal or nearly-normal motion. This requires thin and pliable skin that allows digital flexion and gliding of the underlying tendons. A bulky flap (eg, Groin flap, distant free flap) may impair finger flexion if used for reconstruction of hand. And that, a drawback to these bulky flaps is that the skin tends to be thick, and staged liposuction and/or debulking may be necessary.

Another consideration for thumb reconstruction is that it has the same features and textures as lost tissue. Soft-tissue defects



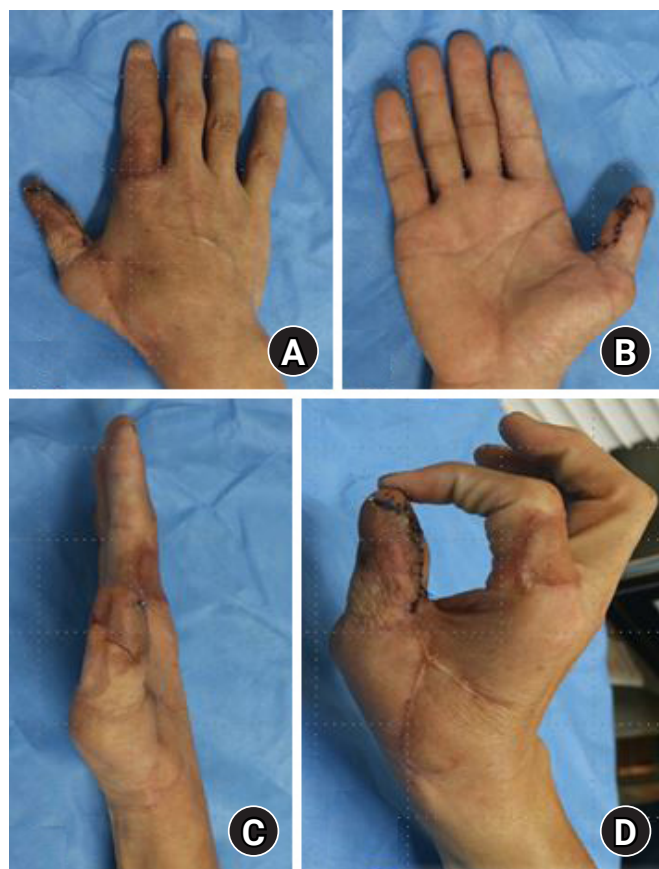


**Fig. 3.** (A, B) Three weeks after the flap surgery, flap division was performed, and at this time, additional debridement and osteotomy were performed. (C, D) The thumb length was nearly conserved as seen in the figures.

of the fingers need a stable skin cover. Although, reconstruction options vary from groin flap to distant free flaps, cross-finger flap and reverse homodigital dorsoulnar flap share the same features of lost tissue and appear to be safer and more reliable.

Therefore, we salvaged the bone of the amputated stump to maintain thumb length, and considered similarity between flap skin and normal skin and thumb function when deciding which flap to use. Accordingly, we chose the reverse homodigital dorsoulnar flap and the cross-finger flap for the reconstruction. We used double flap because it was not possible to reconstruct all of the patient's thumb defect using one flap, and thus, we combined the strengths of these flaps for the reconstruction.

As regards the versatility of the reverse homodigital dorsoulnar flap, previous studies have shown that the ulnar dorsal digital artery of the thumb, which originates from the palmar arteries at the head of the first metacarpal bone, continues distally via the proximal nail fold arcade and anastomoses with the ulnar palmar digital artery at the level of the neck of the proximal phalanx [2]. Our initial experiences with this flap indicated it was prone to vascular compromise, and thus, we



**Fig. 4.** (A, B, C) After flap division surgery, patient's thumb results in the formation with a finger-like skin texture and maintains a length. (D) Patient's thumb is performed such that flexion, opposition and adduction are made possible by maintaining interphalangeal joint function. The patient was able to perform normal daily activities and returned to work.

used the adipocutaneous pedicle instead of the pedicle in the subcutaneous tunnel.

The cross-finger flap is predominantly based on dorsal digital vessels. Although classically, they are raised based on the lateral border of the finger (index finger in our case), they may be raised as proximally or distally based flaps or on a single vascular pedicle, which allows greater flap mobilization. The donor finger to the thumb is classically described as the index finger, wherein the first web space is closed to facilitate inset of the flap [4].

Although we failed to replant at Tamai zone 2 level in a heavy smoker with a long ischemic time and poor coordination, we persevered and performed double flap surgery using a reverse homodigital dorsoulnar flap and a cross-finger flap simultaneously to preserve hand pulp sensation, pinch function, and opposition (Fig. 4).

We recommend that the described double flap be considered

as it enables recycling of bone in the amputated stump, maintains thumb length, and results in the formation of a thumb with a finger-like skin texture. If replantation is difficult or a replanted distal stump fails to revascularize, the reverse homodigital dorsoulnar flap and cross-finger flap provides a feasible alternative treatment option.

## ORCID

Min Jun Yong, <https://orcid.org/0000-0003-2881-5386>

Young Woong Mo, <https://orcid.org/0000-0002-4180-3139>

HeaKyeong Shin, <https://orcid.org/0000-0002-6248-7104>

## Conflicts of interest

The authors have nothing to disclose.

## Funding

None.

## References

1. Lister G. The choice of procedure following thumb amputation. *Clin Orthop Relat Res.* 1985;195:45-51.
2. Brunelli F, Vigasio A, Valenti P, Brunelli G. Arterial anatomy and clinical application of the dorsoulnar flap of the thumb. *J Hand Surg Am.* 1999;24A:803-11.
3. Terán P, Carnero S, Miranda R, Trillo E, Estefanía M. Refinements in dorsoulnar flap of the thumb: 15 cases. *J Hand Surg Am.* 2010;35:1356-9.
4. Chitta M, Malathi L, Joseph A. Cross-finger flap to the thumb: quest for an alternate donor. *Indian J Plast Surg.* 2020;53:287-92.
5. Wolfe SW. Green's operative hand surgery. 6th ed. Philadelphia: Elsevier; 2011.
6. Mitchell A, Jason H, Nicholas B. Reconstruction of the traumatized thumb. *Plast Reconstr Surg.* 2014;134:1235-45.