KJCCM
Korean J Crit Care Med
2016 August 31(3):263 / http://dx.doi.org/10.4266/kjccm.2016.31.2.129.e01
ISSN 2383-4870 (Print) · ISSN 2383-4889 (Online)

■ Erratum ■

Primary Invasive Intestinal Aspergillosis in a Non-Severely Immunocompromised Patient

Eunmi Gil, M.D.[1], Tae Sun Ha, M.D.[1], Gee Young Suh, M.D., Ph.D.[1,2], Chi Ryang Chung, M.D.[1], and Chi-Min Park, M.D., Ph.D.[1,3]

[1]Department of Critical Care Medicine, [2]Division of Pulmonary and Critical Care Medicine, Department of Medicine, [3]Department of Surgery, Samsung Medical Center, Sungkyunkwan University School of Medicine, Seoul, Korea

2016 May 31(2):129-133 / http://dx.doi.org/10.4266/kjccm.2016.31.2.129

We found an error in this article. The Fig. 1A should be corrected as following:

In this article, on page 130, Fig. 1A has an error. Fig. 1A was upside down.
We present the correct figure as below:

Before correction

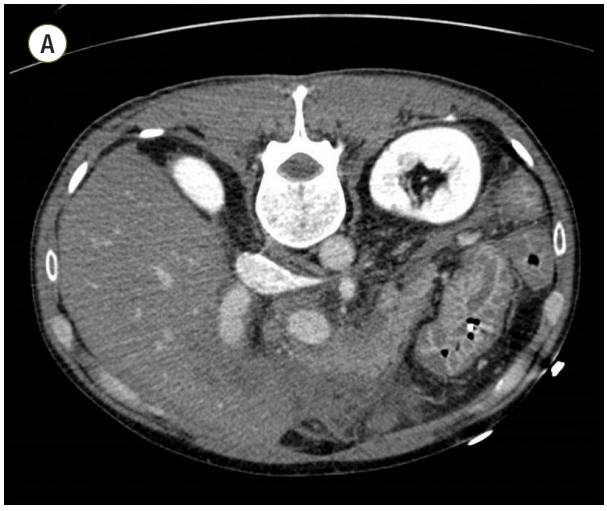

After correction

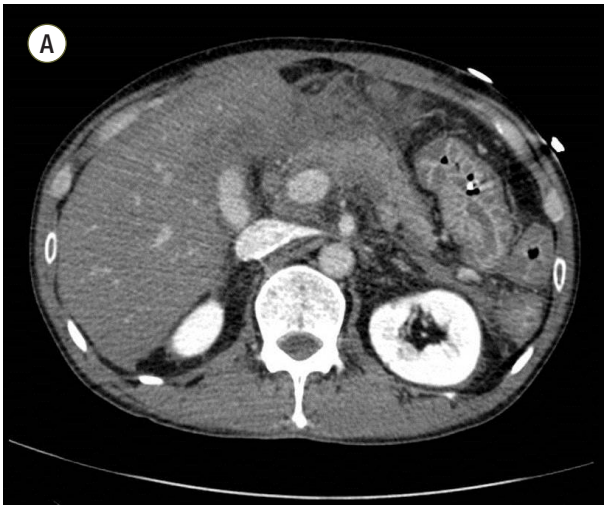

We apologize for any inconvenience that may have caused.