

Amusia After Right Temporoparietal Lobe Infarction: A Case Report

Hyun-Joon Yoo, MD¹, Hyun Im Moon, MD¹, Sung-Bom Pyun, MD, PhD^{1,2}

¹Department of Physical Medicine and Rehabilitation, Korea University Anam Hospital, Korea University College of Medicine, Seoul; ²Brain Convergence Research Center, Korea University Anam Hospital, Seoul, Korea

Which brain regions participate in musical processing remains controversial. During singing and listening a familiar song, it is necessary to retrieve information from the long-term memory. However, the precise mechanism involved in musical processing is unclear. Amusia is impaired perception, understanding, or production of music not attributable to disease of the peripheral auditory pathways or motor system. We report a case of a 36-year-old right-handed man who lost the ability to discriminate or reproduce rhythms after a right temporoparietal lobe infarction. We diagnosed him as an amusic patient using the online version of Montreal Battery of Evaluation of Amusia (MBEA). This case report suggests that amusia could appear after right temporoparietal lobe infarction. Further research is needed to elucidate the dynamic musical processing mechanism and its associated neural structures.

Keywords Cerebral infarction, Auditory perception, Music

INTRODUCTION

Music requires complex brain processing mechanisms. It is first encoded in the ascending auditory pathways to primary auditory cortex. The associated brain areas will link the perception with meaning and memory and then mediate behavioral responses to music [1]. Deficits in musical processing are grouped under the term amusia first introduced by a German doctor, August Knoblauch, in 1888. He defined amusia as a condition in which there was a loss of a musical ability such as the comprehension

of music, the production of music, or the ability to read or write musical notation without peripheral auditory pathways or motor system disorders [2]. Amusia can be classified as acquired or congenital depending on its etiology. Congenital amusia is more common than acquired amusia. Vascular brain injury is the most common cause of acquired amusia [3]. However, which brain regions participate in musical processing remains controversial.

This report describes an unusual case of acquired amusia after right temporoparietal lobe infarction. In this case, we used the online version of Montreal Battery of

Received December 11, 2015; Accepted February 16, 2016

Corresponding author: Sung-Bom Pyun

Department of Physical Medicine and Rehabilitation, Korea University Anam Hospital, Korea University College of Medicine, 73 Incheon-ro, Seongbuk-gu, Seoul 02841, Korea. Tel: +82-2-920-6483, Fax: +82-2-929-9951, E-mail: rmpyun@korea.ac.kr

ORCID: Hyun-Joon Yoo (<http://orcid.org/0000-0002-3610-1765>); Hyun Im Moon (<http://orcid.org/0000-0003-3430-1824>); Sung-Bom Pyun (<http://orcid.org/0000-0002-3471-9692>).

© This is an open-access article distributed under the terms of the Creative Commons Attribution Non-Commercial License (<http://creativecommons.org/licenses/by-nc/4.0>) which permits unrestricted noncommercial use, distribution, and reproduction in any medium, provided the original work is properly cited.

Copyright © 2016 by Korean Academy of Rehabilitation Medicine

Evaluation of Amusia (MBEA) to diagnose the patient as an amusic patient.

CASE REPORT

A 36-year-old man complained of sudden development of dizziness and dysarthria on October 4, 2013. He visited Korea University Medical Center after 3 weeks of symptom onset. He was diagnosed as subacute right temporoparietal lobe infarction (Fig. 1). He received conservative treatment for 8 days at the Department of Neurology followed by discharge. He visited the outpatient Department of Rehabilitation Medicine 5 weeks after the onset of a stroke for evaluation of word retrieval difficulty and strange feeling to familiar music after stroke.

He was right handed. He was a well-educated business man. He was bilingual (Korean and English). He migrated to the United States when he was an elementary school student. He had lived there until he graduated from university. He has been playing piano and trumpet since middle school. He also had learned to play ukulele and clarinet for a year. He was a music enthusiast. He used to listen any kinds of music for 4 to 5 hours a day. However, he became unfamiliar with songs that he used to listen before the onset of a stroke. He had difficulty in singing along to melodies that he had already known.

We performed comprehensive cognitive function evaluation using Computerized Neurocognitive Function Test (CNT; Maxmedica, Seoul, Korea) and Korean version of Mini-Mental State Examination (K-MMSE). Language function was evaluated using Korean version of Western

Aphasia Battery (K-WAB) and Boston Naming Test (K-BNT). In cognitive function tests, he acquired 29/30 on the K-MMSE. CNT results are summarized in Fig. 2. He showed abnormal score in digit span test (forward), immediate recall of verbal learning test, and Stroop test. Digit span represents auditory attention and short-term retention capacity. Immediate recall of verbal learning test means immediate word span under overload condition. Stroop test represents selective attention and inhibitory control of executive function. In language evaluation, his aphasia quotients (AQ) and language quotients (LQ) were 99.4 and 97.5 points, respectively. On K-BNT, he had anomia. His score was 44 points out of 60.

In order to evaluate his musical ability, we additionally tested him with MBEA online test version (<http://www.brams.umontreal.ca/amusia>). The original MBEA test can distinguish amusia and the normal population by assessing the following six musical components: contour, interval, scale, rhythm, meter, and memory. It takes about 2 hours to complete. However, the online test consists of three different blocks. It only takes 15 minutes to complete all questions. The block 1 is for 'mistuned' condition (30 items), followed by block 2 for 'off-beat' condition (24 items), and block 3 for 'out-of key' condition (24 items). The task is to detect an incongruity in each melody by clicking a 'yes' or 'no' buttons [4]. On the test, his global score of correct response was 82% (87% on block 1, 75% on block 2, 83% on block 3) (Table 1). According to the reference value of the online test, his test results were less than average on block 2 and block 3. On block 2, his score was below 2 standard deviations (SD). Considering

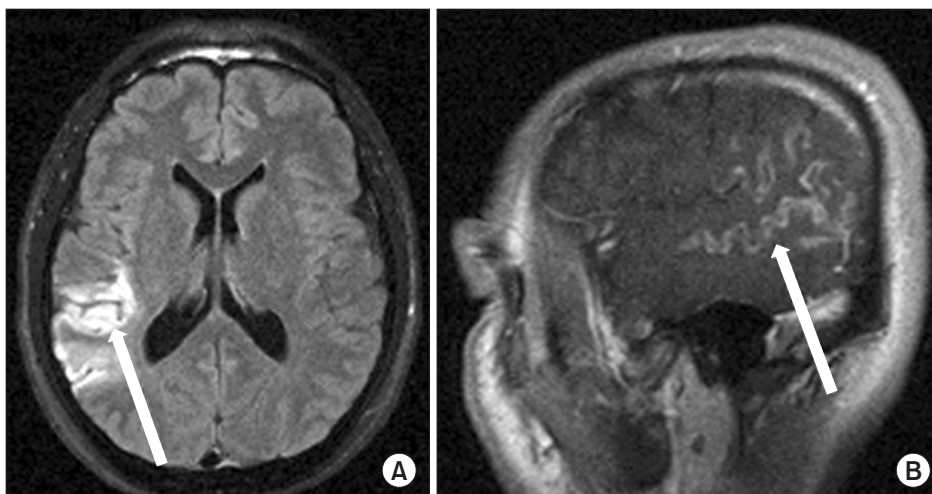


Fig. 1. Brain magnetic resonance imaging in T2 FLAIR image (axial view, A) and T1-weighted image (sagittal view, B) showing gyral edema and high signal intensity on right temporoparietal lobe, including superior temporal gyrus, sulcus, and inferior parietal lobule.

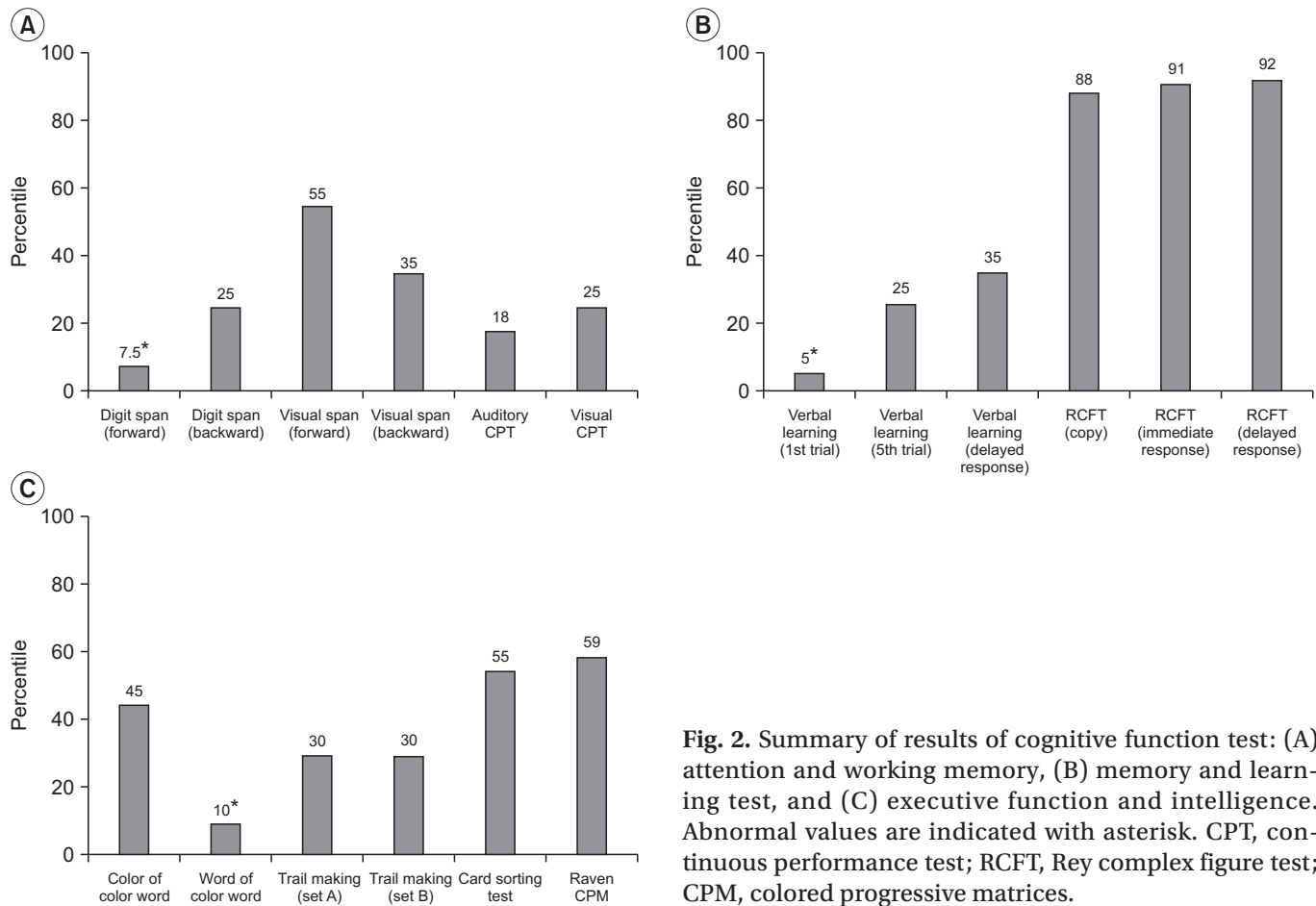


Fig. 2. Summary of results of cognitive function test: (A) attention and working memory, (B) memory and learning test, and (C) executive function and intelligence. Abnormal values are indicated with asterisk. CPT, continuous performance test; RCFT, Rey complex figure test; CPM, colored progressive matrices.

Table 1. Results of MBEA of the patient and reference values

Generation	Block 1 (mistuned)	Block 2 (off-beat)	Block 3 (out-of-key)	Global score	Cut-off score
Case					
Initial	87	75 ^{a)}	83	82	-
Follow-up	100	83	83	90	-
Reference group					
Young (<40 yr)	84 (8.8)	94 (7.5)	86 (11.2)	88.1 (7.2)	73.7
Old (≥40 yr)	77 (9.2)	90 (8.3)	85 (12.9)	84.1 (7.0)	70.1

Values are presented percentage of correct responses, and numbers in parenthesis are standard deviations.

MBEA, Montreal Battery of Evaluation of Amusia.

^{a)}represents score below 2 standard deviations.

his musical experience and relatively well-preserved cognitive function, we diagnosed him as an amusic patient.

We followed up his amusic symptoms at 28 months after stroke. He said that his word retrieval and music perception difficulties were somewhat improved. However, he confessed that he still had trouble with singing and playing to the rhythm. We retested him with the online

MBEA test. Although he showed significant improvement on block 1, the scores of block 2 and block 3 were still less than the average scores of reference value. Especially on block 2, his score was below 1.5 SD (Table 1).

DISCUSSION

In our case report, a 36-year-old man was diagnosed as amusia following right temporoparietal lobe infarction. His diagnosis was based on the online version of MBEA.

There are several diagnostic tools for detecting amusia, including Musical Aptitude Profile, MBEA, and the online test of MBEA [4]. On MBEA, amusia is diagnosed if an individual performs 2 SD below the mean performance of musically intact controls. We tested him with the online test of MBEA due to its convenience. Although the online test has less diagnostic power than the MBEA, the value of the online test for distinguishing amusic has been proven to be useful when using the same criterion of 2 SD below the mean [4]. Even if global score of our case was above the cut-off value, considering his premorbid musical ability, we concluded him as an amusic patient. Especially, he had severe rhythm perception problem as shown in block 2 which was below 2 SD. To seek expert advice, we personally communicated with Isabelle Peretz, the developer of MBEA. She agreed with us on the diagnosis. Currently, neither effective treatment nor clinical course have been investigated. We contact the patient to evaluate the clinical course of amusia at 28 months after stroke. As described in Table 1, his ability to differentiate mistuned melodies was significantly recovered. However, he still had rhythm perception problem as shown in block 2. Acquired amusia is known to be associated with cognitive deficits, especially on working memory, verbal learning, and executive functions. In addition, the recovery of music perception correlates with the recovery of verbal learning and focused attention [5]. Considering his CNT results, attention and learning problems might be associated with the initial MBEA results and amusic symptoms.

Despite many efforts, localization of music-specific neural networks remains elusive due to several difficulties. First, many previous reports of amusia did not have precise descriptions of the lesion sites as they were carried out before the advent of neuroimaging techniques such as computed tomography and magnetic resonance imaging. Second, there have been few reports of ‘pure’ amusia because most amusic patients are accompanied by neuropsychological deficits such as cognitive impairment, aphasia, or apraxia. In a recent systematic review on the etiology of auditory dysfunction in amusia, the

study was inconclusive due to poor quality, considerable heterogeneity, and small case numbers of previous studies [3]. Despite these difficulties, right hemisphere has been traditionally viewed as the ‘musical hemisphere’ based on clinical observations [2]. However, another report has described a right hemisphere dominant amusic case that had left temporal lobe angioma [6]. Therefore, non-dominant hemisphere may play a role in musical processing rather than just right hemisphere. In addition, music and language share a number of common properties, including the fact that they take advantage of modulations of acoustic parameters [7]. In brain lesion case, spoken words might activate the superior temporal gyrus and cross-modal conversions between written and spoken words, thus activating the heteromodal cortices of the supramarginal and angular gyri [8]. However, speech processing critically depends on dominant auditory cortical regions while musical perception depends on non-dominant auditory cortical regions [7]. Such a relative hemispheric asymmetry is supported by our case in that his AQ and LQ scores were within normal ranges.

Human primary auditory cortex is located in the Heschl’s gyrus (HG) in the superior temporal lobe. The lateral portion of HG is known to be responsible for the perception of pitch. Planum temporale located in posterior to HG and superior temporal gyrus located in anterior to HG are auditory association areas that analyze complex sound sources such as pitch interval, melody, and rhythm [1]. Especially, the anterior portions of the superior temporal gyrus are critically involved in temporal perception including distinguishing meter [9].

In our case, his brain lesion sites were mainly right superior temporal gyrus and sulcus. Therefore, our case supports that non-dominant hemisphere and its temporal lobe, especially superior temporal gyrus, are important neural structures for the development of amusia, especially rhythm perception.

There is increasing evidence showing that musical functions recruit neural mechanisms in bilateral cerebral hemispheres rather than by particular brain regions that have responses to them [10]. Thus, further research is needed to elucidate the dynamic musical processing mechanism and its associated neural structures.

CONFLICT OF INTEREST

No potential conflict of interest relevant to this article was reported.

ACKNOWLEDGMENTS

This work was supported by a grant of the National Research Foundation of Korea funded by the Korean government (No. NRF-2016R1A2B4009206).

REFERENCES

1. Warren J. How does the brain process music? *Clin Med (Lond)* 2008;8:32-6.
2. Pearce JM. Selected observations on amusia. *Eur Neurol* 2005;54:145-8.
3. Casey DA. Aetiology of auditory dysfunction in amusia: a systematic review. *Int Arch Med* 2013;6:16.
4. Peretz I, Gosselin N, Tillmann B, Cuddy LL, Gagnon B, Trimmer CG, et al. On-line identification of congenital amusia. *Music Percept* 2008;25:331-43.
5. Sarkamo T, Tervaniemi M, Soinila S, Autti T, Silvennoinen HM, Laine M, et al. Cognitive deficits associated with acquired amusia after stroke: a neuropsychological follow-up study. *Neuropsychologia* 2009;47:2642-51.
6. Piccirilli M, Sciarma T, Luzzi S. Modularity of music: evidence from a case of pure amusia. *J Neurol Neurosurg Psychiatry* 2000;69:541-5.
7. Zatorre RJ, Belin P, Penhune VB. Structure and function of auditory cortex: music and speech. *Trends Cogn Sci* 2002;6:37-46.
8. Booth JR, Burman DD, Meyer JR, Gitelman DR, Parrish TB, Mesulam MM. Relation between brain activation and lexical performance. *Hum Brain Mapp* 2003;19:155-69.
9. Satoh M, Takeda K, Murakami Y, Onouchi K, Inoue K, Kuzuhara S. A case of amusia caused by the infarction of anterior portion of bilateral temporal lobes. *Cortex* 2005;41:77-83.
10. Patel AD, Balaban E. Temporal patterns of human cortical activity reflect tone sequence structure. *Nature* 2000;404:80-4.