

# A Ruptured Blood Blister-Like Aneurysm that Experienced Regrowth with Coil Compaction Twice in a Month : Case Report

Jung Hyun Park

*Department of Neurosurgery, Kosin University Gospel Hospital, Kosin University College of Medicine, Busan, Republic of Korea*

Unlike other aneurysms, blood blister-like aneurysms(BBA) occur at non-branching sites, are commonly located at the dorsal wall of the supraclinoid internal carotid artery (ICA), and are suspected to arise from dissecting aneurysms. They are typically diagnosed after a bleed because of their small size and unusual site. Therefore, lesions exist after brain computed tomography or magnetic resonance imaging, but they are often not found. In the case of BBA, which have a high risk of recurrence, the treatment is difficult, and selecting the treatment method is also challenging. This paper describes the treatment of a BBA with internal trapping of the ICA that eventually recurred despite performing coil embolization twice.

**Key Words:** Blister, False aneurysm, Endovascular procedures

Blood blister-like aneurysms(BBAs)are found on the dorsal wall of the internal carotid artery (ICA) and occur uniquely where there are no branches.<sup>1,2</sup> Although explanations for BBA located at different sites within intracranial circulation have been proposed, the initial and most classical definitions of BBA are limited to the ICA.<sup>3,4</sup> They are particularly rare, comprising about 0.9 –6.5% of all ICA aneurysms, 1% of all intracranial aneurysms, and 0.5 – 2% of ruptured aneurysms.<sup>5-7</sup> They are usually diagnosed after bleeding because the first computed tomography (CT) angiography may miss them due to their small size. Since BBA assuming a saccular shape can be seen up to a few days

after bleeding, special attention should be paid to radiological evaluation at different times, such as after rupture.<sup>8</sup>

Nevertheless, the important point is the difficulty of diagnosis as well as the complexity of treatment. This is always challenging regardless of the treatment method. The extremely fragile wall of BBA makes management complex and dangerous. Here, we present a case of a BBA that had two recurrences despite endovascular coiling.

## CASE

A 57-year-old female with a history of hy-

**Corresponding Author:** Jung Hyun Park, Department of Neurosurgery, Kosin University Gospel Hospital, Kosin University College of Medicine, 262 Gamcheon-ro, Seo-gu, Busan, 49267, Republic of Korea  
Tel: +82-51-990-6124 Fax: +82-51-990-3042 E-mail: baessyl2@naver.com



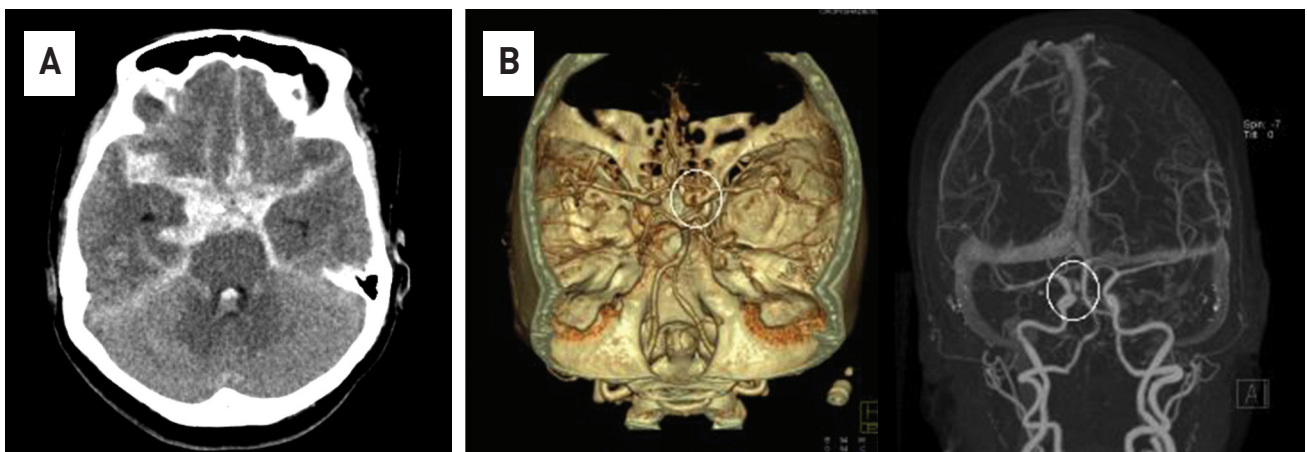
**Received:** Nov. 16, 2021  
**Revised:** Dec. 11, 2021  
**Accepted:** Dec. 11, 2021

Articles published in Kosin Medical Journal are open-access, distributed under the terms of the Creative Commons Attribution Non-Commercial License (<http://creativecommons.org/licenses/by-nc/4.0/>) which permits unrestricted non-commercial use, distribution, and reproduction in any medium, provided the original work is properly cited.

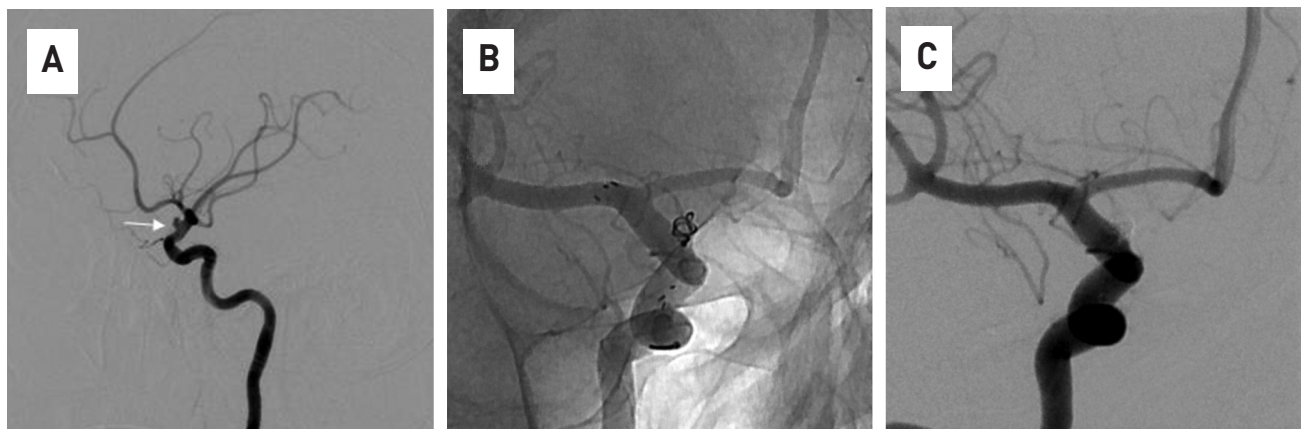
pertension presented to the hospital emergency room with loss of consciousness. Upon arrival, the patient underwent a neurological examination, and the level of consciousness was stupor. As a result of brain CT, a distributed subarachnoid hemorrhage (SAH) was found in the basal cistern and sylvian fissure on both sides (Fig. 1A). Upon taking cerebrovascular CT, a lesion showing outpouching in the right distal ICA was identified (Fig. 1B).

Immediately after diagnosis, transfemoral angiography was performed in the angiography room, and a BBA was identified from the right distal ICA toward the superior direction (Fig. 2A). After checking the location and shape of the cerebral aneurysm, it was determined that endovascular coiling was possible, and the procedure was performed (Fig. 2B, C). Coiling was performed with single open cell stent (Target® 360 detachable coils was used for coil, and a total of 5 coils were packed.) because no stenosis or dilation was found in other parts

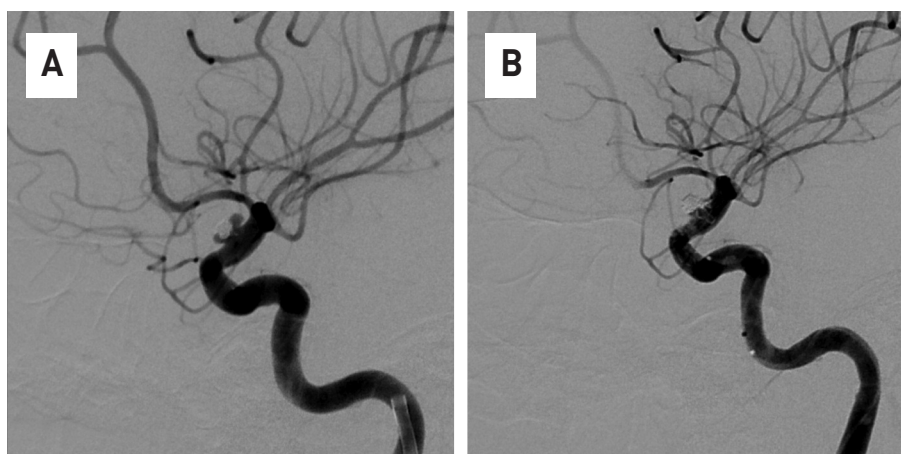
other than the dorsal wall of the right distal ICA. For the safety of vessel wall, the multiple stent technique was also considered, but it was not performed due to the high possibility of the thrombo-embolic complications during the procedure. Dual antiplatelet agents were used immediately after the procedure. In the case of BBA, the possibility of recurrence is very high, so a follow-up examination of the patient was performed 2 weeks later, and aneurysm re-growth was observed along with coil compaction (Fig. 3A). It was determined that additional endovascular treatment was necessary, and the recurrence of the aneurysm sac was treated in the same way as before (Fig. 3B). Additional Target® 360 detachable coils were packaged in the recurrent aneurysm sac, and additional open stents were deployed to prevent coil herniation. Then, 2 weeks later, an additional transfemoral angiography procedure was performed, and it was found that the aneurysm had recurred again (Fig. 4A). It was



**Fig. 1.** Brain computed tomography(CT) scans show diffuse and thick subarachnoid hemorrhage in the basal cistern and both sylvian fissure (A). Contrast-enhanced CT angiography shows a cerebral aneurysm in the right distal ICA(white circle) (B).



**Fig. 2.** In the 4-vessel angiography, a ruptured cerebral aneurysm of a saccular type is observed on the dorsal wall of distal Internal cerebral artery(ICA)(white arrow)(A). The stent was deployed from the proximal ICA to the proximal middle cerebral artery, and the microcatheter was placed in the sac of aneurysm, and then coiling was performed (B). Endovascular coiling was densely packed into the aneurysm sac, and the procedure was terminated after confirming that there was no contrast filling with an aneurysm sac anymore (C).



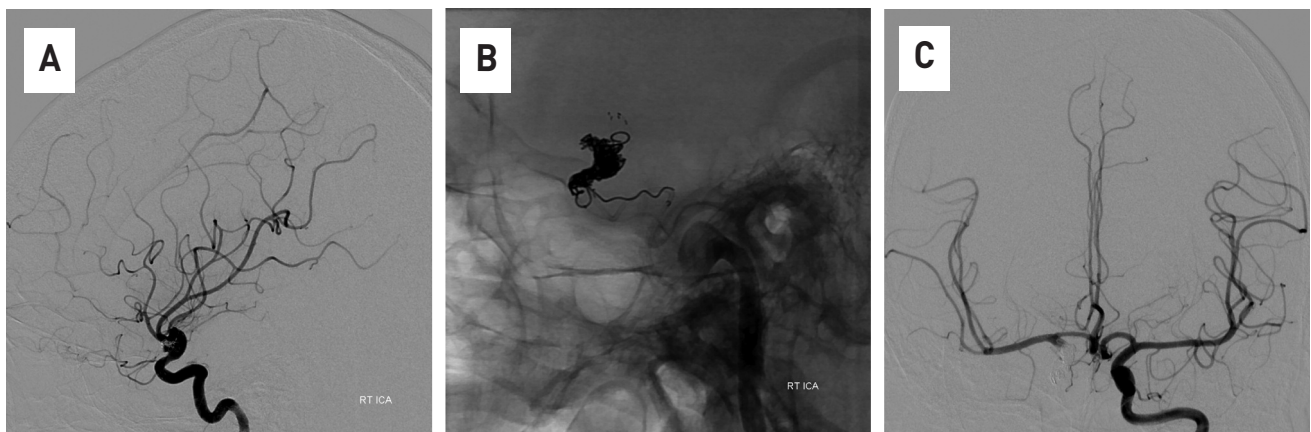
**Fig. 3.** The regrowth and coil compaction of aneurysm were observed in 4-vessel angiography two weeks after the first coil embolization (A). It was determined that additional treatment was necessary, endovascular coiling was performed on the recurrent aneurysm sac, and the procedure was terminated after checking the complete occlusion of the sac (B).

determined that stent-assisted coiling was no longer effective, and other treatment methods were considered. Considering the endovascular trapping treatment method, the lesion-side ICA was blocked through balloon dilatation using a balloon catheter, and as a result of angiography of the opposite ICA, it was con-

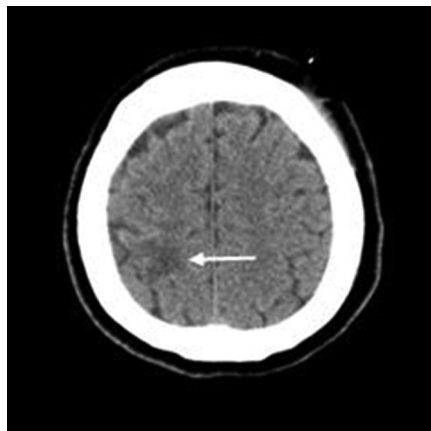
firmed that the blood flow of the right side of the brain was sufficiently supplied through the anterior communicating artery, and the ICA on the lesion side was trapped. After the ICA was completely trapped with multiple Target® 360 detachable coils, follow-up angiography was performed on the ICA on the opposite side,

and the procedure was terminated after confirming that sufficient blood flow was supplied to the brain on the side of the trapped ICA (Fig. 4B, 4C). After the balloon test, the patient's neurological symptoms should be checked, but the patient was unconscious at the time of this test. Therefore, inevitably, the procedure decision was determined only by 4-vessel imaging. And from this point on, the dual antiplatelet agent was stopped. The patient

was discharged from the hospital about 2 months after visiting the emergency room, and there were no other neurological symptoms other than a slight decrease in muscle strength in the left upper limb at the time of discharge. Suspected cerebral infarction near the right motor cortex was observed on Brain CT taken 2 weeks after the second procedure, and the result of thrombo-embolic complications that occurred during three procedures is suspected (Fig. 5).



**Fig. 4.** The regrowth of cerebral aneurysm is observed again in 4-vesselangiography, which was performed two weeks after the additional procedure (A). Internal trapping treatment of distal internal cerebral artery was performed using coils (B). In the 4-vessel angiography conducted by the opposite internal cerebral artery, the flow of blood toward the lesion could be confirmed through anterior communicating artery (C).



**Fig. 5.** After the second procedure, low density near the right motor cortex is observed and is thought to be a suspected cerebral infarction (white arrow).



## DISCUSSION

An aneurysm located on the non-branched area on the dorsal wall of the supraclinoid portion of the ICA was first reported by Sundt et al.<sup>9</sup> in 1969. The extremely fragile wall of BBA makes the management complicated and risky. Various surgeries and endovascular treatments have been proposed for the treatment of BBA. As in this case, there is coil embolization using a stent, and a way to coil using several stents for the stability of the blood vessel wall. Surgical approach include a method of directly identifying a lesion and then clipping, and a method of bypass surgery after trapping the parent artery.<sup>1,2,4</sup> However, despite these various treatment efforts, BBA are very difficult to treat both surgically and endovascularly.<sup>10</sup> Pathological tests were performed on BBA, and a focal wall defect covered by thin layers of fibrous tissue and adventitia and a lack of collagenous layers were reported.<sup>9</sup> These unique characteristics of BBA lead to remarkable weaknesses in the walls and a high risk of premature rupture during surgery and intravascular procedures.<sup>11</sup> Moreover, the rapid increase in size at short intervals is probably related to the hemodynamic stress from the fragile walls and non-branching site of BBA. These remarkable characteristics of BBA are associated with differences in treatment and prognosis from usual saccular aneurysms. These characteristics were likely the cause of the repeated recurrence in our case. The reason why we chose stent assisted coiling as the treatment of this patient was because of the low mobility and mortality of the procedure.

Difficulty in surgery increases the mortality rate of BBA. The mortality rate of SAH with a ruptured BBA is 57%.<sup>1</sup> As a result, in this case, the endovascular method of internal trapping was considered an effective choice of treatment, but in the case of internal trapping, the risk is higher than that of general endovascular techniques.<sup>3-6</sup> It is difficult to choose the method of BBA treatment because none of the predictors of prognosis have been accurately identified. Stent assistance is generally recommended for the treatment of BBA with coil embolization.<sup>3-8</sup> However, if recurrence occurs repeatedly as in this case, internal trapping is also considered a good treatment method.

Various endovascular treatments for aneurysms such as BBA have been documented. However, coil compaction with regrowth is very common after endovascular coiling of blister aneurysms. Therefore, it is thought that transfemoral angiography is necessary as a follow-up within a short period of time.

## REFERENCES

1. Ahn JY, Cho JH, Jung JY, Lee BH, Yoon PH. Blister-like aneurysms of the supraclinoid internal carotid artery: challenging endovascular treatment with stent-assisted coiling. *J Clin Neurosci* 2008;15:1058-61.
2. Ahn JY, Kwon SO, Joo JY. Dorsal internal carotid artery aneurysm treated by coil embolization--case report. *Neurol Med Chir (Tokyo)* 2001;41:603-5; discussion 606.

3. Morris TC, Brophy BP. Blister-like aneurysm of the anterior communicating artery. *J Clin-Neurosci* 2009;16:1098–100.
4. Piotin M, Pistocchi S, Bartolini B, Blanc R. Intracranial aneurysm coiling with PGLA-coated coils versus bare platinum coils: long-term anatomic follow-up. *Neuroradiology* 2012;54:345-8.
5. Satoh A, Nakamura H, Odaki M, Kobayashi S, Kageyama Y, Fukuda K, et al. High risk aneurysms of the internal carotid artery: dorsal IC aneurysms. *SurgCereb Stroke* 1993;1 21:467–72.
6. Kim BM, Kim DI, Chung EC, Kim SY, Shin YS, Park SI, et al. Endovascular coil embolization for anterior choroidal artery aneurysms. *Neuroradiology* 2008;50:251–7.
7. Lee BH, Kim BM, Park MS, Park SI, Chung EC, Suh SH, et al. Reconstructive endovascular treatment of ruptured blood blister-like aneurysms of the internal carotid artery. *J Neurosurgery* 2009;110:431–6.
8. Abe M, Tabuchi K, Yokoyama H, Uchino A. Blood blister like aneurysms of the internal carotid artery. *J Neurosurgery* 1998;89:419–24.
9. Korja M, Rautio R, Valtonen S, Haapanen A. Primary treatment of ruptured blood blister-like aneurysms with stent-assisted coil embolization: report of two cases. *ActaRadiol* 2008;49:180–3.
10. Molyneux A, Kerr R, Stratton I, Sandercock P, Clarke M, Shrimpton J, et al. International Subarachnoid Aneurysm Trial (ISAT) of neurosurgical clipping versus endovascular coiling in 2143 patients with ruptured intracranial aneurysms: a randomised trial. *Lancet* 2002;360:1267–74.
11. Andaluz N, Zuccarello M. Blister-like aneurysms of the anterior communicating artery. a retrospective review of diagnosis and treatment in five patients. *Neurosurgery* 2008;62:807–1. discussion 811.
12. Meckel S, Singh TP, Undrén P, Ramgren B, Nilsson OG, Phatouros C, et al. Endovascular treatment using predominantly stent-assisted coil embolization and antiplatelet and anticoagulation management of ruptured blood blister-like aneurysms. *Am J Neuroradiol* 2011;32:764–71.