

Tongue Reduction Surgery Improves Mandibular Prognathism in Beckwith-Wiedemann Syndrome Without Compromising Tongue Function

Do Won Kim¹ · Jeong Kyou Kim¹ · Gene Huh¹ · Doh Young Lee^{2,3} · Seong Keun Kwon^{1,3,4,5,6}

¹Department of Otorhinolaryngology-Head and Neck Surgery, Seoul National University Hospital, Seoul, Korea

²Department of Otorhinolaryngology-Head and Neck Surgery, Seoul National University Boramae Medical Center, Seoul, Korea

³Department of Otorhinolaryngology-Head and Neck Surgery, Seoul National University College of Medicine, Seoul, Korea

⁴Department of Otorhinolaryngology-Head and Neck Surgery, Biomedical Research Institute, Seoul National University Hospital, Seoul, Korea

⁵Interdisciplinary Program in Stem Cell Biology, Seoul National University, Seoul, Korea

⁶Cancer Research Institute, Seoul National University, Seoul, Korea

Objectives. This study evaluated the surgical outcomes of patients with Beckwith-Wiedemann syndrome who underwent tongue-reduction surgery and analyzed whether the malocclusion and mandibular prognathism caused by macroglossia could be improved.

Methods. A retrospective medical record review was performed for 11 patients with Beckwith-Wiedemann syndrome whose macroglossia was surgically treated. Demographic data, symptoms and signs, and intraoperative and postoperative surgical outcomes were evaluated. Surgery was performed by a single surgeon using the “keyhole” technique, involving midline elliptical excision and anterior wedge resection. Preoperative and postoperative plain skull lateral X-rays were evaluated to assess prognathism improvement.

Results. The median age at the time of surgery was 35.09 months, and the ratio of males to females was 4:7. The median surgical time was 98±31.45 minutes, and the median duration of the postoperative intensive care unit stay was 3.81±2.4 days. There were no airway complications. Two patients (18.2%) had postoperative wound dehiscence; however, there was no nerve damage, recurrence, or other complications. Among the five patients who underwent postoperative speech evaluation, all showed normal speech development, except one patient who had brain dysfunction and developmental delay. Measurements of the A point-nasion-B point (ANB) angles and sella-nasion-B point (SNB) angles (point A is the most concave point of the anterior maxilla; point B is the most concave point on the mandibular symphysis) on plain X-rays showed a significant decrease in the postoperative SNB angle ($P<0.001$) and a significant increase in the ANB angle ($P<0.011$).

Conclusion. Tongue-reduction surgery is an effective and safe technique for severe forms of macroglossia associated with Beckwith-Wiedemann syndrome. In addition, it improves mandibular prognathism in young Beckwith-Wiedemann syndrome patients with macroglossia.

Keywords. Beckwith-Wiedemann Syndrome; Macroglossia; Prognathism

• Received July 13, 2022
Revised September 27, 2022
Accepted October 16, 2022

• Corresponding author: **Seong Keun Kwon**
Department of Otorhinolaryngology-Head and Neck Surgery, Seoul National University Hospital, Seoul National University College of Medicine, 101 Daehak-ro, Jongno-gu, Seoul 03080, Korea
Tel: +82-2-2072-2286, Fax: +82-2-745-2387
Email: kwon.seongkeun@gmail.com

INTRODUCTION

Beckwith-Wiedemann syndrome (BWS) is an overgrowth disorder discovered by J. Bruce Beckwith in the United States in 1963 and H.R. Wiedemann in Germany in 1964 [1,2]. BWS has a spectrum of clinical symptoms and signs that can vary from mild to severe. Because mild cases tend to go unnoticed by patients' care-

Copyright © 2023 by Korean Society of Otorhinolaryngology-Head and Neck Surgery.

This is an open-access article distributed under the terms of the Creative Commons Attribution Non-Commercial License (<https://creativecommons.org/licenses/by-nc/4.0>) which permits unrestricted non-commercial use, distribution, and reproduction in any medium, provided the original work is properly cited.

givers and medical staff, the incidence of BWS is underestimated. However, it is currently believed to occur every 0.07 per 1,000 births [3,4]. BWS is a genetically heterogeneous disorder that is not fully understood. In 75%–80% of cases, chromosomal changes in the imprinted 11p15.5 region have been identified, with approximately 15% of cases being familial, while 85% are sporadic [5]. Autosomal dominant transmission of BWS has been reported, including uniparental paternal disomy of chromosome 11p15.5, and altered expression of the imprinted gene insulin-like growth factor 2 (IGF2) from the normally repressed maternal allele [6].

The clinical symptoms of BWS include neonatal hypoglycemia, macroglossia, visceromegaly, hemihypertrophy, omphalocele, and inguinal hernia. In the head and neck, BWS can manifest as a distinctive ear shape and a high risk for childhood neoplasms. Macroglossia refers to a large tongue that protrudes beyond the teeth or alveolar ridge while in a resting position. It can lead to airway and feeding difficulties, problems with speech, persistent drooling, and cosmetic concerns. In addition, macroglossia can cause malocclusion due to the abnormal position of the tongue, misalignment of the dental arch, and jaw malformation. Malocclusion can make speech difficult and cause the mouth to hang open. For these reasons, tongue-reduction surgery is indicated for BWS patients with symptomatic macroglossia.

Various surgical techniques for tongue reduction have been utilized. In patients with mild macroglossia, conservative therapy is recommended, which includes orofacial regulation therapy using oral stimulation plates and speech therapy [7]. Various tongue reduction techniques have been conducted in craniofacial centers, each with distinct incision patterns and methods, including keyhole, stellate, anterior wedge, and modified W-shaped patterns. For example, Ainuz et al. [8] reported that patients who underwent surgery using the anterior “W” tongue reduction technique had low rates of perioperative complications and showed significant improvements in oral competence.

In this study, we performed a retrospective review of midline elliptical excision and anterior wedge resection performed in BWS patients with macroglossia to evaluate surgical outcomes and complications. We also evaluated whether the malocclusion and mandibular prognathism caused by macroglossia could be surgically improved.

MATERIALS AND METHODS

Study design and ethical consideration

A retrospective review of the medical charts of 68 patients diagnosed with BWS from June 2000 to February 2022 was performed. Among those, 15 patients who underwent tongue-reduction surgery were analyzed. Four patients who underwent surgery at other hospitals or departments were excluded; 11 patients were finally included in this study. We identified two genetically mutated subtypes: one patient (9.1%) had chromosome 11p15.5 ICR1 hypermethylation, and the other nine patients (90.9%) had 11p15.5 ICR2 hypomethylation. Demographic data, perioperative data (including operation time, duration of intensive care unit (ICU) stay, and postoperative complications), diet, speech evaluation, improvements in symptoms, and the need for revision surgery were all analyzed.

A retrospective review of electronic medical records was conducted for each patient after obtaining approval from the Institutional Review Board (No. 2207-028-1337). The study was conducted in accordance with the Declaration of Helsinki (as revised in 2013). Individual consent for this retrospective analysis was waived. The informed consent for the publication of the photograph of pre- and postoperative status of prognathism was obtained separately.

Tongue-reduction surgery: keyhole technique

Tongue-reduction surgery was performed using a keyhole technique known as midline elliptical excision and anterior wedge resection. The operation was performed on BWS patients with macroglossia who had concerns about trauma to the tongue, cosmetic concerns due to tongue protrusion, speech problems, persistent drooling, difficulty eating, dentoskeletal problems, airway obstruction, and failure to thrive. The goal of surgical treatment is to restore the size and shape of the tongue while preserving its functionality, including taste and sensory function, swallowing, and articulation; and to correct and prevent dentoskeletal problems such as mandibular prognathism caused by tongue protrusion.

Surgery started with the patient in the supine position and nasotracheally intubated. We began by mobilizing the tongue to evaluate its size, and three stay sutures were placed at the midline, right and left anterolateral aspects of the tongue; then the keyhole was drawn on its dorsal and inferior surfaces. The width of the anterior wedge was chosen to correct for the degree of

HIGHLIGHTS

- Macroglossia is a frequent symptom in Beckwith-Wiedemann syndrome patients, but it does not always require tongue-reduction surgery.
- The tongue position substantially improved in all patients who received tongue-reduction surgery with the keyhole technique.
- Tongue reduction surgery had no severe complications.
- Speech evaluation and cephalometric analysis revealed that tongue-reduction surgery resulted in functional and morphological improvement.
- Proper tongue-reduction surgery is an effective and safe technique for severe macroglossia in Beckwith-Wiedemann syndrome, and is an effective method to improve mandibular prognathism due to macroglossia.

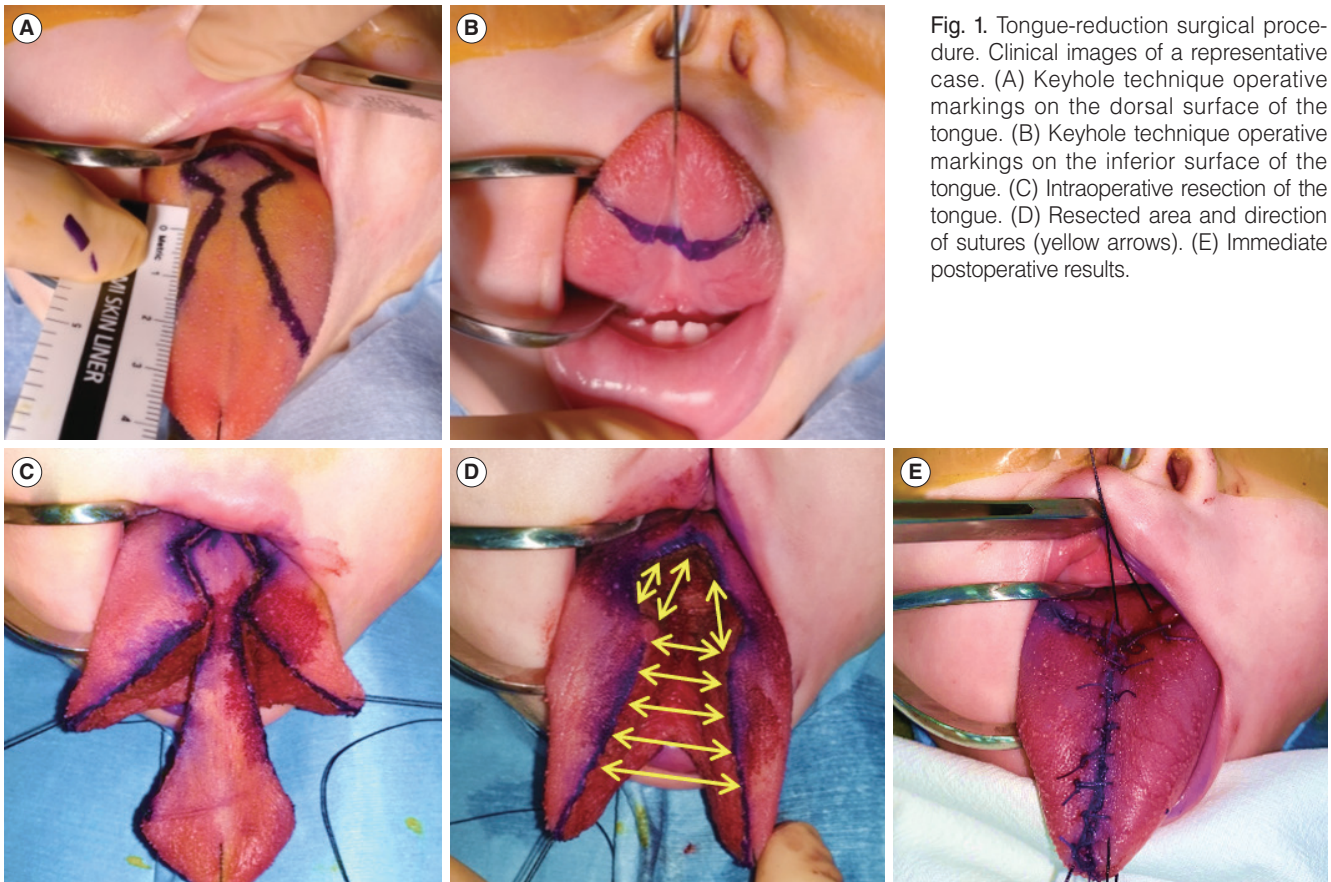


Fig. 1. Tongue-reduction surgical procedure. Clinical images of a representative case. (A) Keyhole technique operative markings on the dorsal surface of the tongue. (B) Keyhole technique operative markings on the inferior surface of the tongue. (C) Intraoperative resection of the tongue. (D) Resected area and direction of sutures (yellow arrows). (E) Immediate postoperative results.

tongue protrusion (Fig. 1A and B). Using the cut mode on a Bovie needle, the mucosal edge and approximately 1 cm of submucosal tissue were incised. We used a Harmonic scalpel (Ethicon Endo Surgery) to cut through the bulk of the muscle, and to reduce bleeding while protecting the lateral neurovascular bundles (Fig. 1C and D). Upon removal of the specimen, hemostasis was performed, and closure was started. Closure was performed with 3-0 and 4-0 Vicryl interrupted sutures (Fig. 1E). Multiple rows of sutures were placed through the bulk of the musculature. Then we used 4-0 Vicryl sutures in a simple interrupted fashion to evert the mucosal edges of the tongue. Routine postoperative pediatric intensive care was performed with the patient intubated and under sedation to reduce postoperative pain and prevent wound dehiscence.

Cephalometric analysis

In the six patients who underwent pre- and postoperative lateral skull X-rays, the sella-nasion-A point (SNA) angle, sella-nasion-B point (SNB) angle, A point-nasion-B point (ANB) angle, sella-nasion-pogonion (SNPg) angle, angle between sella-nasion and gonion-gnathion (SN/GoGn) and angle between gonion-gnathion and anterior nasal spine-posterior nasal spine (GoGn/ANS-PNS) were evaluated to assess improvements in mandibular prognathism (Fig. 2) [9]. Non-parametric unpaired *t*-tests were used

to compare pre- and postoperative differences. Variables are presented as mean \pm standard deviation and statistical analyses were performed using the IBM SPSS ver. 20.0 (IBM Corp.); *P*-values < 0.05 were considered statistically significant.

RESULTS

Among 68 patients diagnosed with BWS from June 2000 to February 2022, 15 patients underwent tongue-reduction surgery. Of these, three patients underwent surgery at other hospitals, and one patient received surgery at a different department; these patients were excluded due to insufficient medical data. Finally, 11 patients treated between December 2017 and February 2022 were analyzed.

There were four male and seven female patients with a median age of 35.09 months (range, 12–96 months). The average follow-up duration was 7.44 ± 11.64 months. All patients had significant tongue protrusion with dentoskeletal problems, and three patients (27.3%) had persistent drooling. One patient (9.1%) had difficulty eating and swallowing. No patients had airway problems, lingual nerve dysfunction, or failure to thrive (Table 1). The mean surgical time was 98 ± 31.45 minutes, and the mean duration of the postoperative ICU stay was 3.81 ± 2.4 days.

Hypoglossal palsy and tongue atrophy were not observed in any patients after surgery. Decreased taste could not be evaluated because the patients were too young, but parental feedback indicated no signs that taste was decreased. A postoperative subjective analysis by the main surgeon revealed that all patients had better tongue positioning in the oral cavity (Fig. 3).

Two patients (18.2%) had postoperative wound dehiscence,

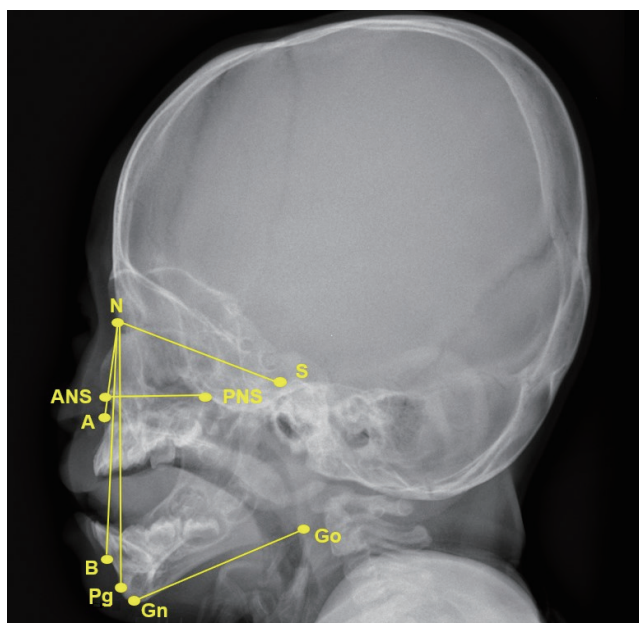


Fig. 2. Cephalometric parameters. The sella-nasion-B point angle measures the anterior limit of the mandibular basal arch in relation to the anterior cranial base. The A point-nasion-B point angle measures the anteroposterior relationship of the mandible to the maxilla. The sella-nasion-pogonion angle measures the mandibular prominence. The sella-nasion (SN) and gonion-gnathion (SN/GoGn) angle measures the craniomandibular angle; the GoGn/anterior nasal spine-posterior nasal spine (ANS-PNS) angle measures the intermaxillary angle. Point A is the most concave point of the anterior maxilla; point B is the most concave point on the mandibular symphysis. N, nasion; S, sella; A, point A; B, point B; Pg, pogonion.

which was managed and resolved with conservative treatment. One patient with wound dehiscence underwent revision surgery (Table 2). Four patients (36.4%) started their diet on postoperative day 1 *via* a Levine tube. The mean oral diet initiation day was 6.0 ± 2.0 days, except for one patient who was kept on a gastrostomy tube due to brain dysfunction. Among five patients who underwent postoperative speech evaluations, all patients showed normal speech development except one patient who had brain dysfunction and delayed development.

The postoperative cephalometric analysis showed that the SNB angle significantly decreased (preoperative 80.86° vs. postoperative 76.27° , $P < 0.001$) and the ANB angle significantly increased (preoperative 5.6° vs. postoperative 8.71° , $P < 0.011$) (Fig. 4). However, there were no significant differences in the SNA angle, SNPg angle, SN/GoGn angle, or GoGn/ANS-PNS angle.

DISCUSSION

Our results show that in BWS patients, performing tongue-reduction surgery effectively ameliorates problems that arise due to enlargement of the tongue. Tongue-reduction surgery in young patients also improves cosmetic outcomes. In addition, our cephalometric analysis showed improvements in objective positioning of the mandible. Although minor complications such as wound dehiscence can occur, there were no critical complications, such as lingual and hypoglossal neuropathy.

BWS is a disease with a wide variety of signs and symptoms. For this reason, it requires a multi-dimensional team of experts. Mild BWS presents as macroglossia that can be managed with conservative treatment, but surgical intervention is required in patients with symptoms related to BWS.

The indications for tongue reduction in BWS patients are multiple. An early operation is necessary in selected patients, such as patients who have difficulties in breathing or feeding, which can lead to failure to thrive. It may also be indicated if the size of the tongue causes drooling, speech or articulation disorders,

Table 1. Demographic and clinical data

Case	Sex	Age at operation (mo)	Body weight (kg)	Tongue protrusion	Feeding problem	Persistent drooling	Dentoskeletal problem	Airway obstruction	Failure to thrive
1	F	68	29.2	+	-	-	+	-	-
2	M	34	16.1	+	-	-	+	-	-
3	F	27	15.7	+	-	-	+	-	-
4	F	34	16.9	+	-	-	+	-	-
5	M	49	19.0	+	-	-	+	-	-
6	F	12	10.8	+	+	-	+	-	-
7	F	13	9.1	+	-	+	+	-	-
8	M	96	45.9	+	-	-	+	-	-
9	F	13	11.3	+	-	-	+	-	-
10	M	14	13.2	+	-	+	+	-	-
11	F	26	14.5	+	+	+	+	-	-

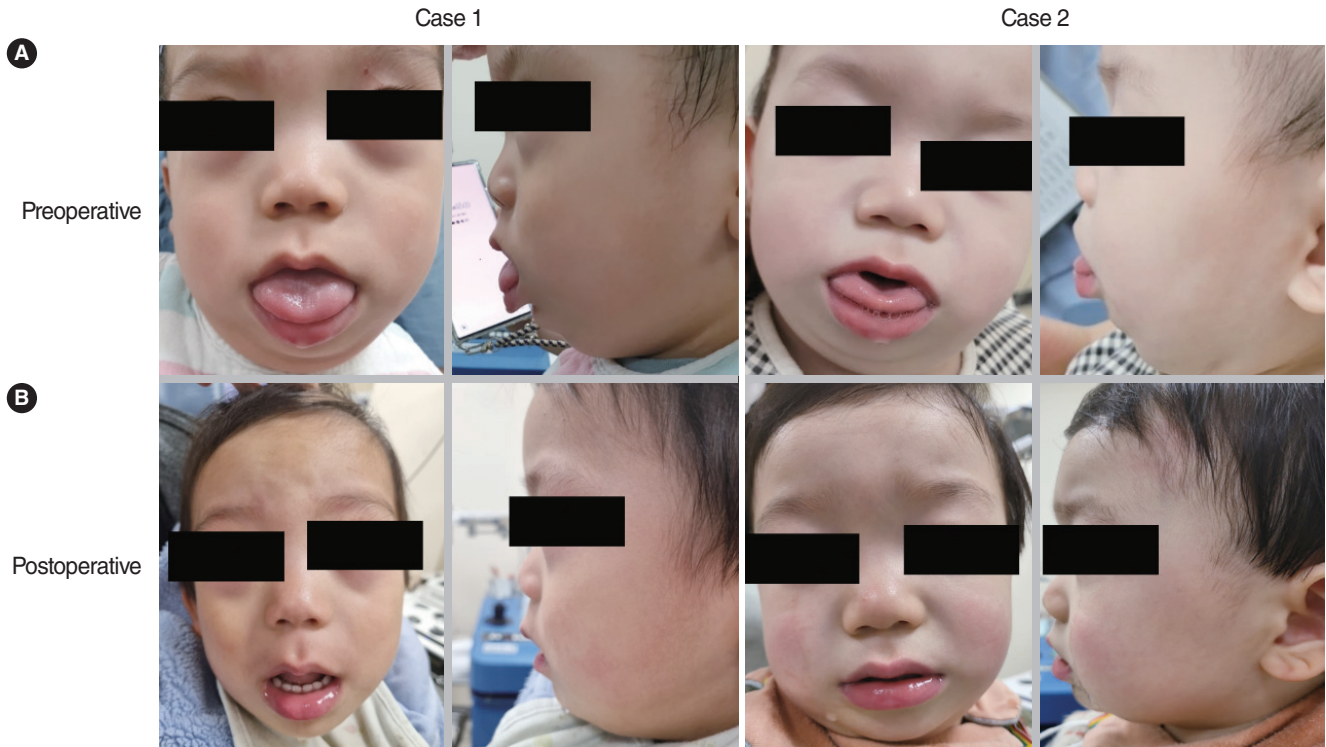

Fig. 3. Preoperative (A) and postoperative (B) external photographs of two patients who underwent tongue-reduction surgery. Subjective analysis revealed that tongue protrusion significantly improved postoperatively.

Table 2. Perioperative data

Case	Operation time (min)	ICU stay (day)	Postoperative complication	Revision surgery	Start of L-tube feeding (postoperative day)	Start of oral diet (postoperative day)
1	174	1	+ ^{a)}	-	NA	4
2	82	1	-	-	1	3
3	60	3	+ ^{a)}	+	NA	4
4	90	1	-	-	1	6
5	84	2	-	-	1	5
6	97	5	-	-	6	8
7	73	6	-	-	2	9
8	121	4	-	-	1	8
9	76	5	-	-	6	8
10	95	6	-	-	4	5
11	100	8	-	-	NA	NA

ICU, intensive care unit; NA, not applicable.

^{a)}Wound dehiscence.

abnormal cosmetic appearance with tongue protrusion and an impression of cognitive delay. A large tongue can also cause unfavorable mandibular growth. There is no absolute contraindication of tongue-reduction surgery [10,11].

In this study, all BWS patients presented with macroglossia accompanied by tongue protrusion. Feeding problems, including difficulty swallowing, were observed in one patient, and drooling was observed in two patients. In the remaining eight patients, there were no physical complications; however, surgery was per-

formed to solve cosmetic concerns and malocclusion due to tongue protrusion.

Postoperatively, two patients suffered from wound dehiscence, and one required revision surgery. Within 4 days, these two patients began an oral diet immediately without the use of a nasogastric feeding tube. The remaining eight patients, except one patient who had a gastrostomy tube, started feeding using a nasogastric tube, and an oral diet began after 5–6 days. To address immediate postoperative complications such as irritability due

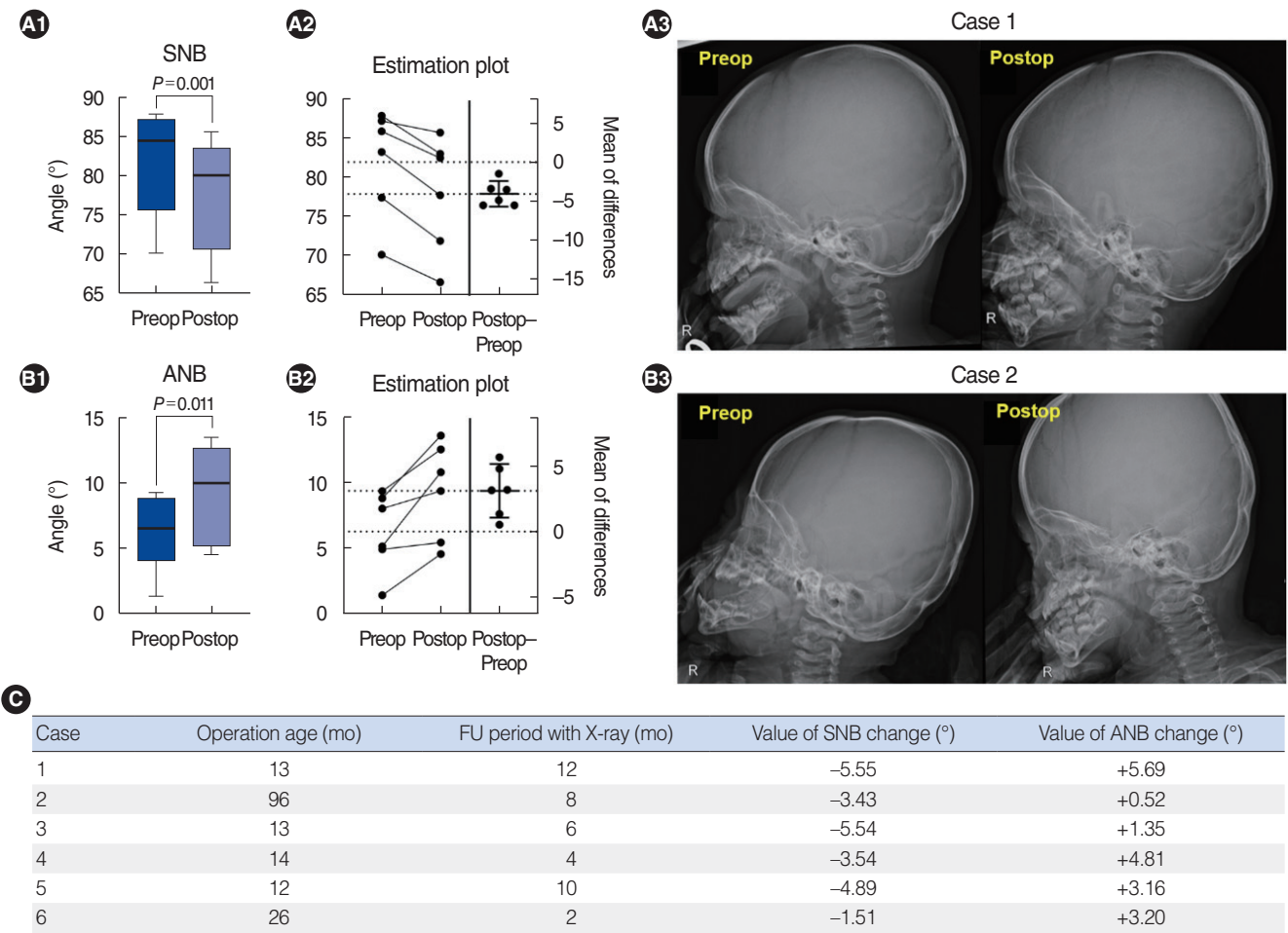


Fig. 4. Cephalometric analysis. Cephalometric analysis revealed that prognathism improved postoperatively. The sella-nasion-B point (SNB) angle significantly decreased (A), and the A point-nasion-B point (ANB) angle was significantly increased (B). The results of the sella-nasion-A point angle, sella-nasion-pogonion angle, Sella-nasion and gonion-gnathion (GoGn), and GoGn/anterior nasal spine-posterior nasal spine angle were not significant, so they were not included in the figure. (C) The table shows the changes of SNB and ANB angle between before and after the operation. We could find the changes in all 6 Beckwith-Wiedemann syndrome patients show the improvement of mandibular prognathism. Preop, preoperative; Postop, postoperative; FU, follow-up.

to postoperative pain and wound dehiscence, all patients stayed in the ICU under deep sedation for the first few days.

No acute airway obstruction due to macroglossia was observed in our patient population; therefore, perioperative tracheostomy was not performed in any case. However, in several previous studies on macroglossia, the patients had compromised airways at birth, at rest in relation to positioning, or during feeding. In addition, one study reported cases of severe airway obstruction that required preoperative tracheostomy [12].

Previous studies have reported that the visual appearance of speech improved following tongue-reduction surgery, as the tongue was no longer visible during articulation. In addition, functional oral motor skills improved, and distinct articulatory errors were eliminated. This finding suggests that good speech results can be obtained following tongue-reduction surgery. In another study, most of the children had normal speech patterns at their post-

surgical follow-up visits [13]. In our study, five patients with preoperative and postoperative speech evaluations showed normal speech development after surgery, except for one patient with developmental delay.

The best age for surgery to prevent or correct prognathism due to macroglossia remains a matter of debate. According to a retrospective review on surgical tongue reduction in BWS patients conducted by Alonso-Rodriguez et al. [14] between 2000 and 2015, tongue regrowth can cause the recurrence of prognathism when surgery is performed too young, which can lead to revision surgery; this may be due to relatively high levels of IGF2. The authors concluded that surgery should be delayed until a minimum age of 6 months. In our study, although there were no significant differences in speech outcomes according to the patients' age at the time of surgery, mandibular prognathism showed greater improvements in younger patients. However, because

our sample size is small, the longest cephalometric follow-up period was 1 year, and we could not check the longitudinal follow-up of each patient, this finding may not be generalizable to other patients with BWS. In addition, we believe that an osteotomy is not necessary for the correction of prognathism in younger patients. However, in a previous paper by Kole [15], tongue-reduction surgery combined with mandibular osteotomy was performed in children 7 to 12 years of age for the management of mandibular prognathism. According to a paper by Meazzini et al. [16], the mandibular growth rate did not decrease in the long term in operated BWS patients compared to non-operated BWS patients. Their data indicated that despite early glossectomy, the mandible continued to grow in height and in length, with a similar growth curve in both operated and non-operated BWS patients [16]. However, their findings were also limited by a small sample size, and other papers demonstrated that tongue reduction, when done prior to 2 years of age, was efficacious at preventing the development and/or worsening of dentoskeletal malocclusion. Therefore, further longitudinal evaluations are needed to elucidate this point, as will be reflected in future research. We believe that before skeletal bony growth is completed and the correction of mandibular prognathism becomes difficult due to the loss of flexibility, tongue-reduction surgery alone can effectively correct prognathism.

Surgical approaches for managing macroglossia were first reported in the 17th century [17]. Since then, several techniques that can reduce tongue size have been utilized, including anterior wedge reduction, tip amputation, central reduction, marginal resection, and dorsal flap excision. Combinations of these can be tailored to specific patients. In this study, we chose midline elliptical excision and anterior wedge resection, also known as the keyhole technique, to correct the aforementioned shape and dysfunctionality of the enlarged tongue. There is no consensus on the surgical extent of tongue reduction, but there are some important considerations that we should pay attention to during surgery to correct the tongue to an ideal size. To avoid aggravating the hypoglossal nerve bundle and artery located in the ventral inferolateral region of the tongue, the midline of the dorsal tongue was elliptically cut, and damage to the glossopharyngeal nerve was minimized by wedge resection of the anterior circumvallate papillae. With these considerations, the operator should carefully correct the tongue size to achieve a normal volume and shape [18].

The keyhole technique can more effectively reduce the tongue size in all dimensions, including the length, thickness, and width, than other techniques, and it has been reported that speech function improves after surgery because this technique rarely affects the mobility of the tongue [10]. In addition to the keyhole technique, there are several different techniques of tongue-reduction surgery, each with its own advantages and complications. Marginal resection can reduce the tongue's width and length, but it is difficult to reduce the thickness using this method. It can cause

the tongue to become ankylosed and globular with limited mobility, potentially leading to speech alteration, paresthesia, and taste alteration [19]. Anterior wedge reduction and tongue tip amputation can reduce the tongue length, but have a poor impact on the width. The perception of taste can be altered after surgery, and this technique can lead to a shortened and ankylosed tongue with limited protraction [15,20]. Central reduction can reduce the thickness of the tongue. The central reduction technique consists of an ellipsoid excision technique and a W-shaped posterior excision technique. These different techniques have yielded good results with minimal complications, but may be insufficient for true macroglossia [21,22]. However, macroglossia varies from patient to patient, making it necessary to tailor surgery according to each patient's unique circumstances.

The patients in this study were too young to evaluate postoperative taste sensation. However, the parents of the patients reported that although the anterior part of the tongue (which senses sweetness) was mostly removed during the operation, the patients' ability to taste sweetness was not affected. A previous study reported that although no patients completely lost taste sensation, their ability to detect salty and bitter tastes declined after surgery [23]. However, research on postoperative taste function in BWS patients is lacking, and further studies are needed. Despite the positive outcomes of tongue-reduction surgery, it should be kept in mind that individually tailored surgery is necessary to reflect each patient's tongue size.

In conclusion, symptomatic macroglossia requiring surgical tongue reduction is relatively rare; therefore, tongue-reduction surgery is not commonly performed in patients with BWS. When indicated, tongue-reduction surgery must be tailored to the unique needs of BWS patients, and the keyhole technique can successfully narrow and shorten the tongue. In our study, we showed that tongue-reduction surgery is a simple, effective, and safe technique for treating severe macroglossia while preserving the functional part of the tongue in BWS patients. In addition, an advantage of the keyhole technique is that it does not completely remove the tip of the tongue, and therefore it does not affect the sensation and positioning required for normal speech. Above all, we found that tongue-reduction surgery is an effective method to improve mandibular prognathism caused by macroglossia in young BWS patients.

CONFLICT OF INTEREST

No potential conflict of interest relevant to this article was reported.

ACKNOWLEDGMENTS

This work was supported by the National Research Foundation

of Korea (NRF) grant funded by the Korea government (MSIT) (2020R1A4A4079931) and by the Bio & Medical Technology Development Program of NRF funded by the MSIT (No. 2019 M3A9H1103617). Also, this research was supported by Korean Fund for Regenerative Medicine funded by Ministry of Science and ICT, and Ministry of Health and Welfare (RS-2022-00070684, Republic of Korea). Also, this work was supported by the Technology Innovation Program (or Industrial Strategic Technology Development Program-Bio-industrial technology development-customized diagnostic treatment products) (20014955, Development of Intelligent Automation System for mass production of cell therapy products) funded By the Ministry of Trade, Industry & Energy (MOTIE, Korea).

ORCID

Do Won Kim <https://orcid.org/0000-0002-6431-7889>
 Jeong Kyou Kim <https://orcid.org/0000-0003-3562-1678>
 Gene Huh <https://orcid.org/0000-0003-4487-1361>
 Doh Young Lee <https://orcid.org/0000-0003-1590-8559>
 Seong Keun Kwon <https://orcid.org/0000-0001-9218-7666>

AUTHOR CONTRIBUTIONS

Conceptualization: SKK. Data curation: DWK, JKK. Formal analysis: DWK, JKK, GH. Methodology: DWK, GH, DYL. Project administration: SKK. Visualization: DWK, DYL. Writing—original draft: DWK, DYL, SKK. Writing—review & editing: DWK, DYL, SKK.

REFERENCES

- Beckwith JB. Extreme cytomegaly of the adrenal fetal cortex, omphalocele, hyperplasia of the kidneys and pancreas, and Leydig-cell hyperplasia: another syndrome? In: Proceedings of the annual meeting of the Western Society for Pediatric Research; 1963 Nov; Los Angeles, CA.
- Wiedemann HR. Familial malformation complex with umbilical hernia and macroglossia: a “new syndrome”? *J Genet Hum.* 1964 Sep; 13:223-32.
- Higurashi M, Iijima K, Sugimoto Y, Ishikawa N, Hoshina H, Watanabe N, et al. The birth prevalence of malformation syndromes in Tokyo infants: a survey of 14,430 newborn infants. *Am J Med Genet.* 1980; 6(3):189-94.
- Elliott M, Maher ER. Beckwith-Wiedemann syndrome. *J Med Genet.* 1994 Jul;31(7):560-4.
- Lodeiro JG, Byers JW 3rd, Chuipek S, Feinstein SJ. Prenatal diagnosis and perinatal management of the Beckwith-Wiedemann syndrome: a case and review. *Am J Perinatol.* 1989 Oct;6(4):446-9.
- Weksberg R, Squire JA. Molecular biology of Beckwith-Wiedemann syndrome. *Med Pediatr Oncol.* 1996 Nov;27(5):462-9.
- Limbrock GJ, Fischer-Brandies H, Avallé C, Castillo-Morales’ orofacial therapy: treatment of 67 children with Down syndrome. *Dev Med Child Neurol.* 1991 Apr;33(4):296-303.
- Ainuz BY, Geisler EL, Hallac RR, Perez JK, Seaward JR, Kane AA. Anterior “W” tongue reduction for macroglossia in Beckwith-Wiedemann syndrome. *Cleft Palate Craniofac J.* 2022 Sep;59(9):1145-54.
- Steiner CC. Cephalometrics in clinical practice. *Angle Orthod.* 1959 Jan;29(1):8-29.
- Wolford LM, Cottrell DA. Diagnosis of macroglossia and indications for reduction glossectomy. *Am J Orthod Dentofacial Orthop.* 1996 Aug;110(2):170-7.
- Balaji SM. Reduction glossectomy for large tongues. *Ann Maxillofac Surg.* 2013 Jul;3(2):167-72.
- Rimell FL, Shapiro AM, Shoemaker DL, Kenna MA. Head and neck manifestations of Beckwith-Wiedemann syndrome. *Otolaryngol Head Neck Surg.* 1995 Sep;113(3):262-5.
- Shipster C, Oliver B, Morgan A. Speech and oral motor skills in children with Beckwith Wiedemann Syndrome: pre-and post-tongue reduction surgery. *Adv Speech Lang Pathol.* 2006 Jan;8(1):45-55.
- Alonso-Rodriguez E, Gomez E, Martin M, Munoz JM, Hernandez-Godoy J, Burgueno M. Beckwith-Wiedemann syndrome: open bite evolution after tongue reduction. *Med Oral Patol Oral Cir Bucal.* 2018 Mar;23(2):e225-9.
- Kole H. Results, experience, and problems in the operative treatment of anomalies with reverse overbite (mandibular protrusion). *Oral Surg Oral Med Oral Pathol.* 1965 Apr;19(4):427-50.
- Meazzini MC, Besana M, Tortora C, Cohen N, Rezzonico A, Ferrari M, et al. Long-term longitudinal evaluation of mandibular growth in patients with Beckwith-Wiedemann syndrome treated and not treated with glossectomy. *J Craniomaxillofac Surg.* 2020 Dec;48(12): 1126-31.
- Massengill R, Pickrell K. Surgical correction of macroglossia. *Pediatrics.* 1978 Mar;61(3):485-8.
- Kaufman Y, Cole P, McKnight A, Hatef DA, Hollier L, Edmonds J. A modified keyhole technique for correction of macroglossia. *Plast Reconstr Surg.* 2008 Dec;122(6):1867-9.
- Gardon MA, Andre CV, Ernenwein D, Teissier N, Bennaceur S. New surgical method of tongue reduction for macroglossia: technical note. *Oral Surg Oral Med Oral Pathol Oral Radiol.* 2019 Jan;127(1):e1-7.
- Egyedi P. Reduction of tongue size in the surgical correction of jaw deformity. *Br J Oral Surg.* 1965 Jul;3(1):13-21.
- Davalbhakta A, Lamberty BG. Technique for uniform reduction of macroglossia. *Br J Plast Surg.* 2000 Jun;53(4):294-7.
- Heggie AA, Vujcich NJ, Portnof JE, Morgan AT. Tongue reduction for macroglossia in Beckwith Wiedemann syndrome: review and application of new technique. *Int J Oral Maxillofac Surg.* 2013 Feb;42(2): 185-91.
- Matsune K, Miyoshi K, Kosaki R, Ohashi H, Maeda T. Taste after reduction of the tongue in Beckwith-Wiedemann syndrome. *Br J Oral Maxillofac Surg.* 2006 Feb;44(1):49-51.