

Horizontal Dorsal Septal Incision for High Deviation Correction During Septoplasty

Cheol Hyo Ku^{*}, Eun Jung Lee^{*}, Sang Man Park,
Ha Neul Lee, Hyun Su Lee, and Dong-Joon Park

Department of Otorhinolaryngology, Yonsei University Wonju College of Medicine, Wonju, Korea

상부 비중격 만곡증 교정을 위한 비중격 배부 수평절개

구철효^{*} · 이은정^{*} · 박상만 · 이하늘 · 이현수 · 박동준

연세대학교 원주의과대학 이비인후과학교실

Received May 9, 2022

Revised June 22, 2022

Accepted June 22, 2022

Address for correspondence

Dong-Joon Park, MD, PhD
Department of Otorhinolaryngology,
Yonsei University
Wonju College of Medicine,
Wonju Severance Christian Hospital,
20 Ilsan-ro, Wonju 26426, Korea
Tel +82-33-741-0642
Fax +82-33-732-8287
E-mail rhico@yonsei.ac.kr

*These authors contributed equally
to this work.

When performing septoplasty in patients with a high deviation of the nasal septum, effective correction is difficult and postoperative complications such as a saddle nose may result if the bone or cartilage is removed inordinately. Although several surgical techniques have been introduced, some are difficult to apply easily. Furthermore, the deviation may persist despite the application of surgical techniques due to the rebound memory of the remaining cartilage. This study aimed to describe a simple and safe surgical technique for crooked nasal septa with a high deviation. This method using horizontal dorsal septal incision allows easy separation of the highly deviated portion from the upper lateral cartilage. Furthermore, it is less traumatic than other methods, and predictably preserves the keystone area.

Korean J Otorhinolaryngol-Head Neck Surg 2022;65(7):419-22

Keywords Crooked nasal septum; Dorsal incision; High deviation; Nasal septum; Septoplasty.

Introduction

A deviated nasal septum is problematic because it causes nasal symptoms including nasal obstruction and other issues such as obstructive sleep apnea and compromised aesthetics. Septoplasty is the most common method for correcting a deviated septum.^{1,2)} Conventionally, a curved septum is corrected by septoplasty. In principle, septoplasty aims to save a large portion of the cartilage, correct the curved cartilage, and remove the bony deviated portion.^{3,4)} Correcting the curvature of the dorsal region of the septal cartilage is challenging, as it may affect the stability of the structures supporting the sep-

tum. Although several surgical techniques are available, a few are difficult to apply easily. Additionally, the deviation may persist despite the application of the surgical techniques due to rebound memory of the remaining cartilage.⁵⁾ In this study, we proposed a horizontal dorsal septal incision of the deviated septum with a mucosal through-and-through suture technique that is performed to secure the corrected cartilage in the designated position in cases of high septal deviation.

Methods

Participants

From June 2019 to June 2020, 28 patients aged 18 years and older underwent septoplasty in our institution via horizontal dorsal septal incision with a mucosal through-and-

This is an Open Access article distributed under the terms of the Creative Commons Attribution Non-Commercial License (<https://creativecommons.org/licenses/by-nc/4.0>) which permits unrestricted non-commercial use, distribution, and reproduction in any medium, provided the original work is properly cited.

through suture technique using an endonasal approach under general anesthesia. Patients who had nasal obstruction due to a C- or S-shaped nasal septum with the high cartilaginous deviation were included in the study. Anterior rhinoscopy, nasal endoscopy, and CT scan of the paranasal sinuses were performed to confirm the type of septal deviation. Patients who required additional treatment to improve nasal obstruction, such as a severely narrowed internal nasal valve or external dorsal nasal deviation, were excluded.

The surgical procedure

Incision and exposure

The surgical procedure is as follows. Under general anesthesia, a modified Killian incision was made on one side of the nasal cavity using a no. 15 blade.

Separation of septal cartilage

After mucoperichondrial flap elevation on the unilateral side of the septum, the inferior cartilage was stripped from the maxillary crest with a knife to mobilize the lower portion of the cartilage. For mobilization of the posterior part of the cartilage, separation of the perpendicular plate of the ethmoid-cartilaginous junction was made with a blunt elevator, except for the posterior-superior attachment (at an approximate width of 1 cm from the dorsum, a posterior attachment of the L-strut) to preserve the keystone area (Fig. 1A, black dotted line).

Horizontal dorsal septal incision for the mobilization of the superior part of the septum

To ensure flexibility and mobilization of the upper attachment of the septal cartilage, an incision was made from the most posterior part of the cartilage to the most anterior end (Fig. 1A, red dotted line). After leaving an approximately 1 cm width in the posterior attachment to preserve the keystone area, the incision was directed upward along the upper end of the cartilage to separate the upper lateral cartilage. Importantly, the highly deviated portion was completely separated from the upper lateral cartilage to provide mobilization while preserving the keystone area (Fig. 1A).

The incision should be made at a cartilaginous depth, and care should be taken not to damage the mucosa opposite side of the flap. Since the only attached and anchored part of the cartilage is opposite side of the mucoperichondrium, considerable attention should be paid to avoid complete detachment. Anterior vertical resection is not routinely performed, but

through the horizontal incision itself, the deviated septal cartilage is medialized. Any remaining deviation of the bone or keystone area may be corrected by fracture. Moreover, if the septal cartilage remains deviated after the horizontal dorsal septal incision, it may be corrected through additional scoring, wedge resection, or selective removal.

Suture and finish

A through-and-through suture of the nasal septum, including the mucosal flap, was performed using chromic 5-0 (Fig. 1B). Importantly, this procedure supports the robust correction of any remaining cartilage deviations, by forcibly reducing the rebound memory of the septum. It is crucial to provide adequate suture tension to prevent the restriction of blood circulation. Subsequently, both nasal cavities were packed with a polyvinyl acetate sponge (Merocel[®]; Medtronic Xomed Inc., Jacksonville, FL, USA). All patients were provided with analgesics and third-generation cephalosporins and discharged after packing removal on the second day after surgery.

Outcome assessment

The objective outcomes were evaluated using endoscopy. The surgeon checked for postoperative complications, such as deviation recurrences or a saddle nose. The preoperative self-reported discomfort score for nasal obstruction using the visual analog scale (VAS) was checked one day before surgery. Subjective symptom improvement was also recorded using the same scale at the 1-year follow-up. Scores ranged from 0 (excellent) to 10 (poor).

Statistical analyses

All statistical analyses were performed using SPSS (version 25.0; IBM Corp., Armonk, NY, USA). A *p*-value less than 0.05 was considered statistically significant. Paired *t*-tests and Wilcoxon signed-rank tests were performed to analyze patient discomfort by age and sex according to the pre- and post-treatment symptoms.

Results

There were 28 adults (25 male, 3 female) enrolled in this study. The mean age was 43.7 years (range: 19–68 years). Of the 28 patients, 21 (75%) had a crooked septum and 7 (25%) also had a bony spur. A horizontal dorsal septal incision was performed in all patients. There was no change in the nasal dorsum or tip shape among the treated patients. There were

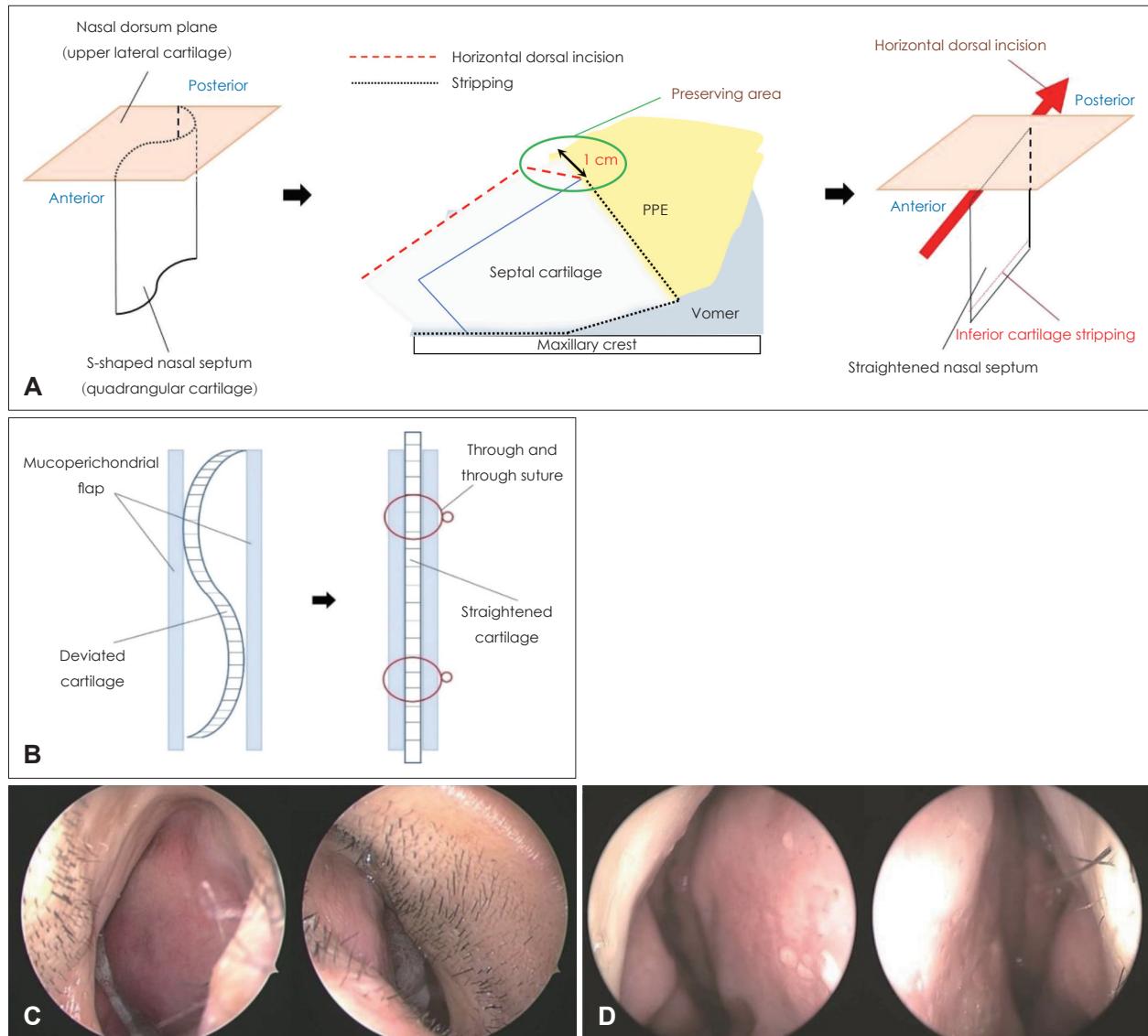


Fig. 1. Overall description and the effect of the horizontal dorsal septal incision procedure. A: Schematic image of the key steps of the horizontal dorsal septal incision technique. The green solid line represents the preserving area, and the red dotted lines represent the main procedure area of the horizontal dorsal septal incision. B: An area of approximately 1 cm width in the posterior attachment should not be incised to preserve the keystone area. C and D: Illustration of the through-and-through suture technique performed using chromic 5-0 for the entire nasal septum, including the mucosal flap. Pre- and post-operative endoscopic findings. The preoperative (C) endoscopy shows that the septum has severely deviated to the right side. The postoperative endoscopic view shows a relatively straightened septum and a corrected high deviation of the septum at 1-month post-surgery (D).

no significant complications such as saddle deformity, septal hematoma, septal perforation, or nasal tip support problem at the 1-year follow-up (Fig. 1C and D). The preoperative VAS score was 8.21 ± 1.18 , and the postoperative score was 2.13 ± 1.18 ($p < 0.05$), indicating reduced nasal obstruction and improved symptoms. The postoperative VAS scores decreased significantly in all genders and age groups ($p < 0.05$) (Fig. 2).

A deviated nasal septum is a common anatomical variation that causes nasal obstruction. The correction of C- or S-shaped deviated cartilage is difficult, especially in cases with a high

deviation.⁶⁾ Moreover, if a deviation near the keystone area is removed excessively, the surgeon faces issues due to lack of stability of structures supporting the septum. Therefore, the complete correction of cartilage with high deviation is sometimes difficult.⁷⁾ Kang, et al.⁸⁾ introduced a method of performing a mattress suture between the perpendicular plate area and the quadrangular cartilage, by causing a greenstick fracture to the upper part of the perpendicular plate. Most of the previous methods focused on the most deviated point, hence these techniques are difficult to apply when there is a

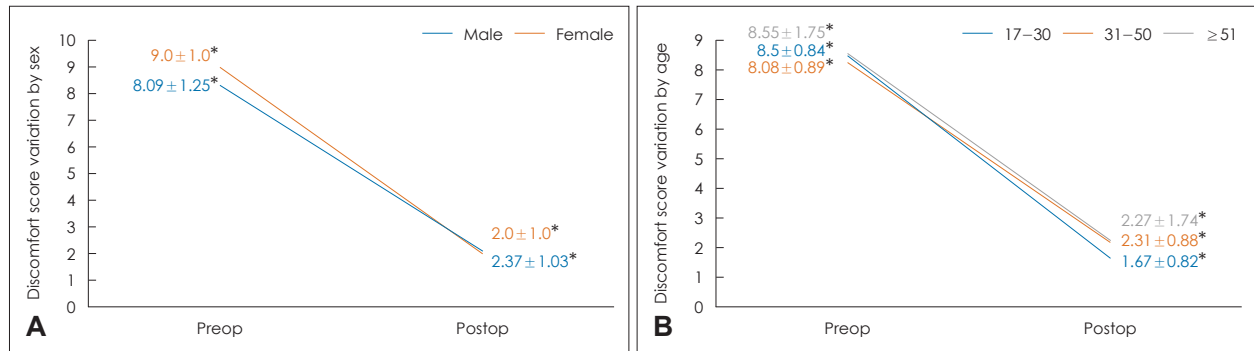


Fig. 2. Pre- and post-operative discomfort scores by (A) sex and (B) age. Values are presented as means±standard deviations. * $p < 0.05$.

diffuse C- or S-shaped high deviation. Here, we introduced a simple and safe surgical technique for patients with a crooked nasal septum with a high deviation.

There have been several methods for correcting deviated nasal septum such as extracorporeal septoplasty, septal batten graft, extension graft, L-strut reconstruction, suture technique, and the use of bioresorbable materials.⁹⁾ A problem with these techniques is that additional skills different from those of the traditional nasal septoplasty are required. This renders the techniques difficult for the surgeons to apply. Our proposed method may be a good choice for practitioners who are hesitant to attempt the correction of a high deviation owing to a lack of experience. By separating the highly deviated portion from the upper lateral cartilage, it is possible to distribute the bending vector from the upper part of the septum and correct the nasal septum. Corrections that may be somewhat insufficient in the caudal cartilaginous portion can be supplemented through additional techniques such as the through-and-through suture technique. A horizontal dorsal septal incision along the upper end of the cartilage during septoplasty did not result in postoperative stability problems including saddle nose, tip shape problems, or tip support problems. We found no structural problems to date after 1-year follow-up in patients who underwent the procedure. This suggests that a horizontal dorsal septal incision is a safe and effective method for correcting a high deviation due to a crooked dorsal septum. In the future, our findings should be verified through long-term follow-up studies.

Supplementary Video Legend

Video 1. Demonstration of high septal deviation correction through horizontal dorsal septal incision.

Supplementary Materials

The Data Supplement is available with this article at <https://doi.org/10.3342/kjorl-hns.2022.00367>.

Acknowledgments

The fee of English editing service was supported by a faculty research grant from Yonsei University Wonju College of Medicine (grant no. 2022-52-0054 to E.J.L.).

Author Contribution

Conceptualization: Cheol Hyo Ku, Dong-Joon Park. Data curation: Sang Man Park, Ha Neul Lee. Supervision: Eun Jung Lee, Dong-Joon Park. Visualization: Cheol Hyo Ku, Hyun Su Lee. Writing—original draft: Cheol Hyo Ku, Eun Jung Lee. Writing—review and editing: Dong-Joon Park.

ORCIDs

Dong-Joon Park <https://orcid.org/0000-0001-8319-1479>
 Cheol Hyo Ku <https://orcid.org/0000-0002-0841-6030>
 Eun Jung Lee <https://orcid.org/0000-0002-0454-4510>

REFERENCES

- 1) van Egmond MMHT, Rovers MM, Tillema AHJ, van Neerbeek N. Septoplasty for nasal obstruction due to a deviated nasal septum in adults: A systematic review. *Rhinology* 2018;56(3):195-208.
- 2) Teixeira J, Certal V, Chang ET, Camacho M. Nasal septal deviations: A systematic review of classification systems. *Plast Surg Int* 2016;2016:7089123.
- 3) Cerkas N. The crooked nose: Principles of treatment. *Aesthet Surg J* 2011;31(2):241-57.
- 4) Most SP, Rudy SF. Septoplasty: Basic and advanced techniques. *Facial Plast Surg Clin North Am* 2017;25(2):161-9.
- 5) Kim MJ, Jang YJ. Selection of surgical technique and treatment outcome of revision septoplasty. *Korean J Otorhinolaryngol-Head Neck Surg* 2017;60(12):640-5.
- 6) Şevik Eliçora S, Erdem D, Işık H, Damar M, Dinç AE. Difficult septal deviation cases: Open or closed technique? *Braz J Otorhinolaryngol* 2017;83(3):256-60.
- 7) Han SJ, Oh H, Park YK, Min SG, Shin JH, Lee WW, et al. Should the high septal deviation be corrected to improve nasal obstruction during septal surgery? *J Rhinol* 2016;23(2):85-90.
- 8) Kang JM, Nam ME, Dhong HJ, Kim HY, Chung SK, Kim JH. Modified mattress suturing technique for correcting the septal high dorsal deviation around the keystone area. *Am J Rhinol Allergy* 2012;26(3):227-32.
- 9) Özyazgan İ. Septal deviation treatment using bone or cartilage grafts fixed with cyanoacrylate tissue adhesive. *Aesthetic Plast Surg* 2017;41(3):618-27.