

Clinical Article

Anatomical Variant of Atlas : Arcuate Foramen, Occipitalization of Atlas, and Defect of Posterior Arch of Atlas

Myoung Soo Kim, M.D.

Pohang SM Christianity Hospital, Pohang, Korea

Objective : We sought to examine anatomic variations of the atlas and the clinical significance of these variations.

Methods : We retrospectively reviewed 1029 cervical 3-dimensional (3D) CT images. Cervical 3D CT was performed between November 2011 and August 2014. Arcuate foramina were classified as partial or complete and left and/or right. Occipitalization of the atlas was classified in accordance with criteria specified by Mudaliar et al. Posterior arch defects of the atlas were classified in accordance with criteria specified by Currarino et al.

Results : One hundred and eight vertebrae (108/1029, 10.5%) showed an arcuate foramen. Bilateral arcuate foramina were present in 41 of these vertebrae and the remaining 67 arcuate foramina were unilateral (right 31, left 36). Right-side arcuate foramina were partial on 18 sides and complete on 54 sides. Left-side arcuate foramina were partial on 24 sides and complete on 53 sides. One case of atlas assimilation was found. Twelve patients (12/1029, 1.17%) had a defect of the atlantal posterior arch. Nine of these patients (9/1029, 0.87%) had a type A posterior arch defect. We also identified one type B, one type D, and one type E defect.

Conclusion : Preoperative diagnosis of occipitalization of the atlas and arcuate foramina using 3D CT is of paramount importance in avoiding neurovascular injury during surgery. It is important to be aware of posterior arch defects of the atlas because they may be misdiagnosed as a fracture.

Key Words : Atlas · Arcuate foramen · Arch · Congenital defect · Occipitalization of atlas.

INTRODUCTION

Knowledge of craniocervical junction (CCJ) abnormalities and their morphology is essential for clinicoradiological studies. The ponticulus, a bony bar arising from the lateral mass of the atlas, when fully developed, transforms the groove of the vertebral artery (VA) into a canal (arcuate foramen). These dysmorphisms may be clinically silent⁷⁾. However, in asymptomatic individuals, they may become dangerous in the context of trauma⁶⁾, or provoke slight troubles during specific diagnostic or surgical procedures^{13,39)}. Occipitalization of the atlas (also known as atlanto-occipital assimilation) is thought to be a manifestation of so-called occipital vertebrae (i.e., incomplete segmentation between the atlantal and occipital bones)¹¹⁾. Occipitalization is the most common anomaly of the CCJ, with a prevalence of 0.08–3.63% of the population^{2,14,36)}. Because of the rare prevalence of occipitalization of the atlas, the anatomical changes associated with this condition have not yet been fully explored. Congenital de-

fects of the posterior arch of the atlas are uncommon, but their characteristics have been well described. In emergency departments, it is important to distinguish this variant anatomy from fracture and/or dislocation. Although X-ray imaging or computed tomography (CT) findings of congenital defects of the posterior arch of the atlas have been reported, 3-dimensional (3D) CT features of this anomaly have not been described in detail.

Understanding the anatomical basis of CCJ anomalies is important when performing CCJ region surgeries. In this report, we describe the incidence and anatomical features of arcuate foramina, occipitalization of the atlas, and congenital defects of the posterior arch of the atlas. We review and discuss these anomalies in the context of surgical treatment.

MATERIALS AND METHODS

We conducted a retrospective review of cervical 3D CT. We excluded 3D CT of patients from outside the catchment area of the

• Received : January 7, 2015 • Revised : July 16, 2015 • Accepted : August 31, 2015

• Address for reprints : Myoung Soo Kim, M.D.

Pohang SM Christianity Hospital, 351 Posco-daero, Nam-gu, Pohang 37816, Korea
Tel : +82-54-289-1983, Fax : +82-54-275-0003, E-mail : hanibalkms@hanmail.net

• This is an Open Access article distributed under the terms of the Creative Commons Attribution Non-Commercial License (<http://creativecommons.org/licenses/by-nc/3.0>) which permits unrestricted non-commercial use, distribution, and reproduction in any medium, provided the original work is properly cited.

hospital, including foreigners. These included patients who presented at our hospital due to cervical problem (cervical trauma, neck pain, degenerative cervical disease) between November 2011 and August 2014. An Aquilion Prime 160-slice CT scanner (Toshiba Medical Systems Corporation, Otawara, Japan) was used for 173 patients and an Aquilion CXL edition 128-slice CT scanner (Toshiba Medical Systems Corporation, Otawara, Japan) was used for 856 patients. In total, 1029 scans comprising those of 639 male patients and 390 female patients were reviewed. The age of the patients ranged from two years and two months to 88

years (49.03 ± 15.55).

Parameters for the 3D CT acquisition were as follows : 140 mm field of view, 120 kVp, 150 mA, 0.5 mm section thickness, and 0.3 mm interval. The scan range was from the mid-body of the T2 vertebra to the base of the occiput. Axial and sagittal images (window level 60/window width 320) with 2 mm or 3 mm section thickness and a bone axial and sagittal images setting (window level 350/window width 2700) with 2 mm or 3 mm section thickness were transferred to a picture archiving and communication system (PACS). A series of 12 3D surface rendering reconstruction images around the vertical rotational view at every 20° was generated using software provided with the Aquilion Prime or Aquilion CXL edition scanners.

Arcuate foramina were classified as either partial or complete and left and/or right. We did not include bony protrusion due to noticeable impression for VAs as partial type. Partial type was considered as partial arcuate foramen which was noted as a distinct bony spicule extending from the superior articular facet overhanging the dorsal arch. Assimilation of the atlas was classified in accordance with criteria specified by Mudaliar et al.²³. Zone 1 fusion involves the anterior arch of the atlas in front of the lateral masses. Zone 2 fusion primarily involves the lateral processes. Zone 3 fusion involves the posterior arch of the atlas behind the lateral masses. The final type involves a combination of zones. Posterior arch defects of the atlas were classified in accordance with the criteria specified by Currarino et al.⁵, who classified aplasia and cleft into five forms : A) a fissure or small gap because of failure of posterior midline fusion of the two hemiarches, B) cleft or absence of one or two arms of the posterior arch, C) bilateral defects with preservation of the most dorsal part of the arch, D) absence of the posterior arch with a persistent posterior tubercle, and E) absence of the entire arch, including the tubercle (Fig. 1).

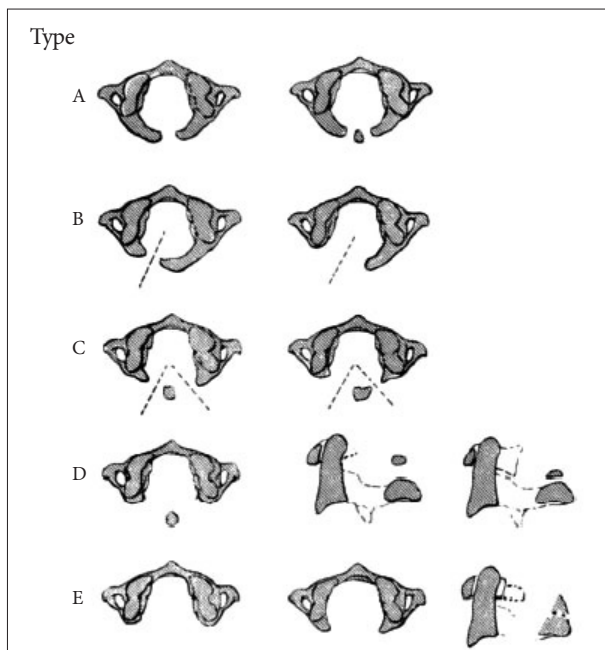


Fig. 1. Classification of posterior arch defects of the atlas. Type A : failure of posterior midline fusion of the two hemiarches. Sometimes a small separate ossicle is seen within the gap, Type B : unilateral cleft, ranging from a small gap to a complete absence of the hemiarch and posterior tubercle, Type C : bilateral clefts of the lateral aspects of the arches with preservation of the most dorsal part of the arch, Type D : complete absence of the posterior arch with a persistent isolated tubercle. This anomaly is conceivably a more extensive form of bilateral clefts. The lateral parts of the posterior arch are absent except for the posterior tubercle, Type E : absence of the entire posterior arch including the tubercle. Reproduced with permission from Currarino G, Rollins N, Diehl JT : Congenital defects of the posterior arch of the atlas : a report of seven cases including an affected mother and son. *AJNR Am J Neuroradiol* 15 : 249-254, 1994⁹.

RESULTS

Arcuate foramen

One hundred and eight vertebrae (108/1029, 10.5%, 78 males, 30 females, age 16–81 years, 48.28 ± 14.69 years) showed the presence of a bony exostosis from the posterior margin of the superior articular facet (Fig. 2). Bilateral arcuate foramina were found in 41 vertebrae, and in the remaining 67 vertebrae the occurrence

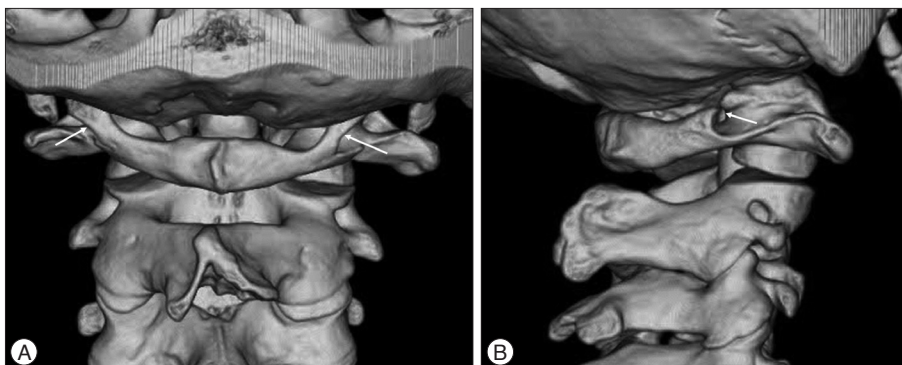


Fig. 2. Arcuate foramen. A : Three-dimensional computed tomography of a 21-year-old man showing complete arcuate foramina on both sides (arrows). B : Three-dimensional computed tomography of a 54-year-old woman demonstrating a partial arcuate foramen on her right side (arrow).

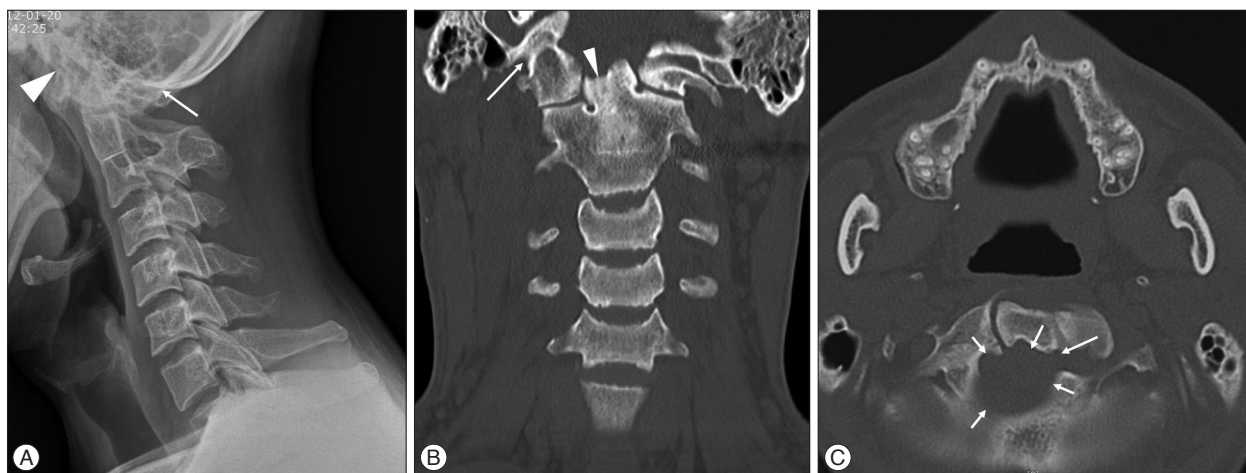

Fig. 3. Occipitalization of the atlas. A : Lateral cervical spine X-ray image of a 32-year-old man showing occipitalization of the atlas, C2–3 fusion (arrow : fusion between occiput and posterior arch of atlas, arrowhead : fusion between occiput and anterior arch of atlas). B : Coronal computed tomography demonstrating an abnormal odontoid process (arrowhead) and occipitalization of the atlas (arrow). C : Axial computed tomography showing an anomalous foramen magnum (arrows).

was unilateral (right 31, left 36). Right-side arcuate foramina were partial on 18 sides and complete on 54 sides. Left-side arcuate foramina were partial on 24 sides and complete on 53 sides.

Occipitalization of the atlas

There was one case of atlas assimilation. The type of this assimilation included a combination of zones. An anomalous odontoid process and foramen magnum were observed. C2 and C3 fusion was associated with this anomaly (Fig. 3).

Defect of posterior arch of the atlas

In our study, a defect of the atlantal posterior arch was found incidentally in 12 patients (1.17%, nine male patients and three female patients, range 14–69 years) (Fig. 4). Nine of these patients (9/1029, 0.87%) had a type A posterior arch defect. We also identified one type B, one type D, and one type E defect. One patient with a type A posterior arch defect had an anterior arch defect.

DISCUSSION

Arcuate foramen

The ponticulus posticus (arcuate foramen), or “little posterior bridge,” is an ossification of the oblique atlanto-occipital ligament superior to the VA groove of the atlas. An arcuate foramen has been reported with an incidence of from 1.14% to 37%^{20,22,24,35,36,38}. In this study, one hundred and eight vertebrae (108/1029, 10.5%) showed the presence of a bony exostosis from the posterior margin of the superior articular facet.

An arcuate foramen is usually regarded as a simple anatomical variant. However, compression of the nervous and vascular structures passing through the foramen may result in a combination of symptoms forming a picture of vertebrobasilar insufficiency¹⁷. This consists of cervical migraine³⁷, neurosensory-type hearing loss¹⁶, neck pain, vertigo, shoulder/arm pain and, in some

instances, even loss of postural muscle tone and consciousness^{4,32}. Surgical excision of such an arcuate foramen appears to alleviate these symptoms¹⁸. Penning²⁵ considers that there is more to the mechanism than pure arcuate foramen compression, identifying trauma as a trigger factor. However, whether such trauma leads to direct VA injury and musculoskeletal compromise, which in turn leads to VA compression, is unclear³⁷.

Cushing et al.⁶ found an arcuate foramen in 8 of 11 patients with VA dissection and occlusion. The site of arterial injury was at the level of this bony variation in all cases. Because more than 50% of head rotation occurs at the atlantoaxial joint, the VA is most vulnerable to compression and stretching at this level. Therefore, additional compression/tethering of this vessel by an arcuate foramen may increase its predisposition to injury. During flexion of the neck, the VA glides superiorly and anteriorly relative to the posterior arch, and this is more likely to occur on the posterior lateral masses of the atlas than at more caudal sites in the neck¹⁹.

When the VA courses above the posterior arch of the atlas, the placement of lateral mass screws is relatively safe¹⁰, however, the risk may increase significantly with any anomalous course of the VA. Indeed, the abovementioned arcuate foramen would place the VA in the path of any atlas lateral mass screw. Young et al.³⁹ have commented that the arcuate foramen may be mistaken for a widened posterolateral aspect of the posterior arch of the atlas, so that placement of lateral mass screws at C1 can be difficult. When an arcuate foramen is found, screw fixation through the lateral mass of the atlas is not feasible, and other modalities of internal fixation must be pursued¹³. For example, C1–2 transarticular screw fixation, the C1 dorsal arch as an entry point for C1 screw placement, and skip C1 screw fixation and to extend the level of fixation proximally or distally can be alternative method¹². Because arcuate foramina are not rare, the need for identification of this anomaly on preoperative radio-

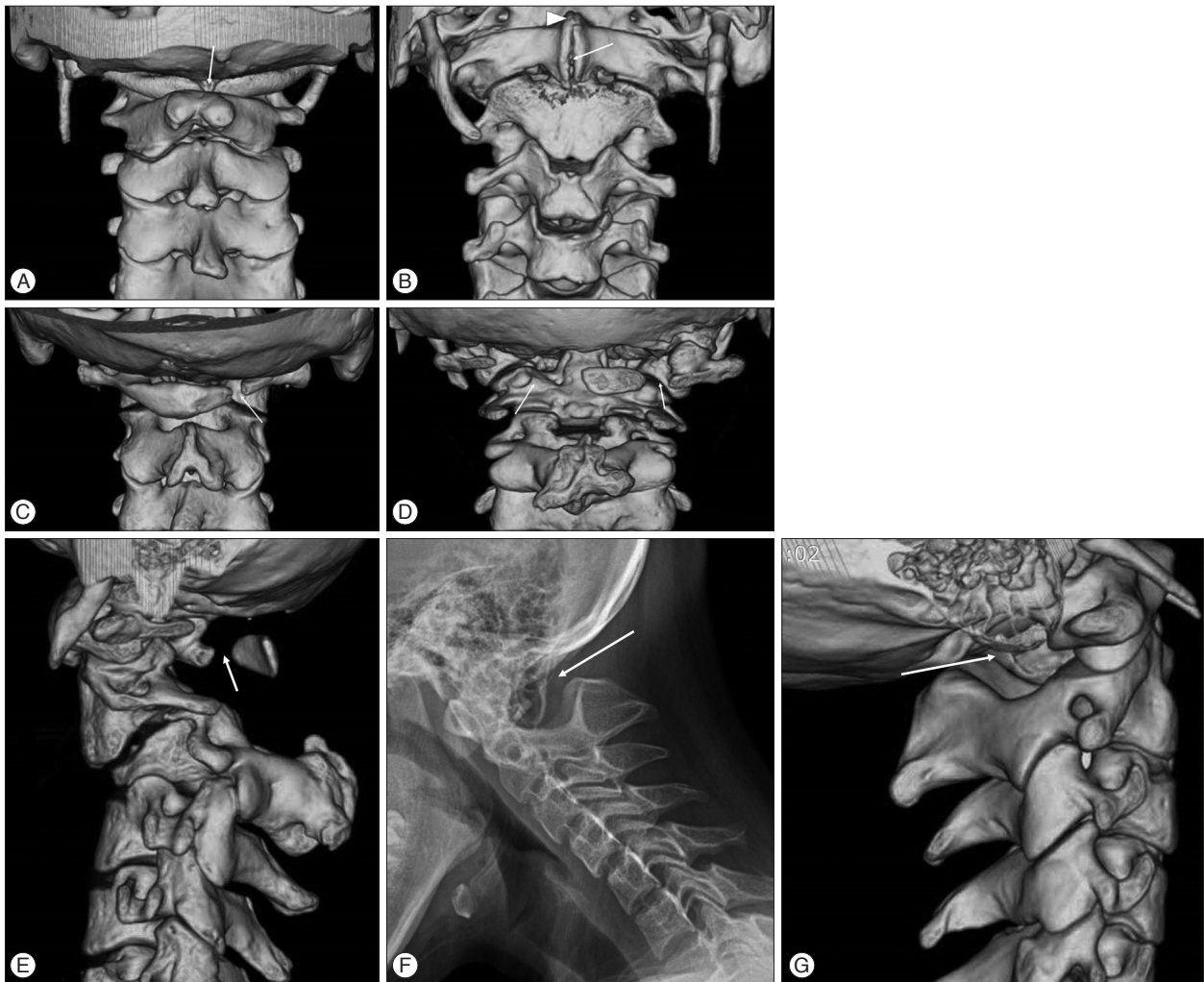


Fig. 4. Defect of the posterior arch of the atlas. A and B : Three-dimensional computed tomography of a 34-year-old man showing a Type A defect of the posterior arch of the atlas (A, arrow) and a defect of the anterior arch of the atlas (B, arrow, arrowhead : no defect in upper portion of anterior arch). C : Three-dimensional computed tomography of a 58-year-old woman showing a Type B defect (arrow). D and E : Three-dimensional computed tomography of a 41-year-old woman showing a Type D defect (arrow). F and G : Lateral cervical spine X-ray image (F, arrow : absence of the entire arch, including the tubercle) and three-dimensional computed tomography (G, arrow : absence of the entire arch, including the tubercle) of a 14-year-old girl showing a Type E defect.

graphs and, particularly, high-resolution CT cannot be overemphasized¹¹.

Occipitalization of the atlas

Occipitalization of the atlas (also known as atlanto-occipital assimilation) is thought to be a manifestation of so-called occipital vertebrae (that is, incomplete segmentation between the atlantal and occipital bone)¹¹. Occipitalization of the atlas is caused by failure of segmentation between the fourth occipital sclerotome (proatlas) and the first cervical sclerotome during embryonic development²¹. The incidence of occipitalization of the atlas ranges from 0.08% to 3.63%^{2,14,27}. In this study, the incidence of occipitalization of the atlas was 0.097%. The synostosis has been classified into four types based on the zones of the atlas fused with the occiput²³. Zone 1 fusion involves the anterior arch of the atlas in front of the lateral masses (20% of cases). Zone 2

fusion primarily involves the lateral processes (17%). Zone 3 fusion involves the posterior arch of the atlas behind the lateral masses (13%). Combinations of zones were seen in over 50% of patients. In our patient, combinations of zones of atlanto-occipital fusion were seen (Fig. 2).

Occipitocervical synostosis results in a shift of the first mobile segment between the skull and spine to the C1–2 junction. This causes stress and a restricted range of movement, as a result of which there may be overstretch failure of the supporting myoligamentous structure, leading to a gradual loosening of the atlantoaxial joint with progressive atlantoaxial subluxation²³. Compression of the spinal cord or the brain stem because of occipitocervical synostosis can produce signs and symptoms varying from a simple headache to a full blown neurological syndrome³¹. Compression of the VA can compromise blood flow to the brain. Our patients demonstrated no symptoms associated

with occipitalization of the atlas.

Atlantal occipitalization per se requires no treatment; however, when symptoms of neural compression or spinal instability develop, surgical intervention, such as CCJ decompression and/or fusion, may be required²⁶⁾. Most patients with occipitalization of the atlas probably remain asymptomatic and undetected. For those that develop symptoms, the onset is usually in the third or fourth decade. The surgeon should also recognize that manipulation of the cervical spine during surgical positioning may place patients with atlantal occipitalization in greater jeopardy of suffering VA occlusion^{19,29)}. According to Wang et al.³⁶⁾, anomalies of the VA occur more often in cases with occipitalization of the atlas. Wang et al.³⁶⁾ reported four distinct types of VA at the CCJ with occipitalization of the atlas. Type 1 : the VA courses medially after leaving the transverse foramen of the axis, enters the spinal canal below the occipitalized C1 posterior arch, and enters the foramen magnum. The course of the VA is below the occipitalized C1 lateral mass. Type 2 : the VA courses medially after leaving the transverse foramen of the axis, enters the spinal canal below the occipitalized C1 posterior arch, and enters the foramen magnum. The course of the VA is on the posterior surface of the occipitalized C1 lateral mass, or forms a curve on it. Type 3 : the VA ascends laterally after leaving the transverse foramen of the axis, passes through the transverse foramen of the atlas (if present), enters an osseous foramen created between the fused atlas and occiput, and then reaches the cranium. The anomalous pathway has its internal opening at the external edge or anterior part of the occipitalized C1 lateral mass. Type 4 : the VA is absent on one side of the CVJ. In our patients, we could not identify the type of either VA.

Congenital defect of the posterior arch of the atlas

The atlas normally develops from the three primary ossification centers : one midline anterior center, which forms the anterior arch, and two lateral centers for each lateral mass. It develops during the seventh week of gestation^{3,34)}. Two centers at the lateral masses extend posteromedially to form the posterior neural arch by year 4. Ossification of the anterior neural arch occurs posterolaterally from the midline anterior center to the lateral mass and is complete at 7 years of age⁸⁾. Rarely, in only 2% of the population, a fourth center appears, which results in the posterior tubercle of the atlas and unites with the lateral masses of the atlas. Posterior atlantal arch defects are attributed to the defective or absent development of the cartilaginous preformation of the arch rather than a disturbance of the ossification⁹⁾. This is supported by findings at autopsy or intraoperatively where connective tissue bridges the bony defect²⁷⁾. Isolated posterior arch clefts are relatively common, and are reported in 1.5–5% of the population^{3,5,9)}. In this study, the incidence of congenital defects of the posterior arch of the atlas was 1.17%.

Developmental anomalies of the posterior arch of the atlas range from simple clefts to absence of the entire arch. In 1994, Currarino et al.⁵⁾ classified aplasia and cleft in five forms : A) a

fissure or small gap because of failure of the posterior midline fusion of the two hemiarches, B) cleft or absence of one or two arms of the posterior arch, C) bilateral defects with preservation of the most dorsal part of the arch, D) absence of the posterior arch with a persistent posterior tubercle, and E) absence of the entire arch, including the tubercle. Currarino's classification is used in most of the literature. Type A clefts according to Currarino's classification occur in proximately 4% of the population. Over 90% of defects are Type A. Currarino et al.⁵⁾ estimated that 0.69% of the general population harbor Types B–E.

Patients are most commonly asymptomatic, although the defect can cause chronic cervical pain, headache, and Lhermitte's sign²⁸⁾. Cervical myelopathy is also possible, and has been reported in several cases^{15,28)}, especially with types C and D of Currarino's classification, which are both associated with the presence of a free-floating posterior osseous fragment. In these cases, the presence of a posterior tubercle may cause impingement on the cord, which may result in myelopathy or possibly cord contusion. Richardson et al.²⁷⁾ suggested that the symptoms were secondary to compression of the cord by the inward mobility of the isolated posterior bony fragment during extension of the cervical spine. Sharma et al.³⁰⁾ were the first to document true movement of the bony tubercle with neck extension. Torremans et al.³³⁾ reported that stenosis of the atlas and axis was observed because of slight abnormal movement and hyperostosis of the persistent posterior tubercle and hypertrophy of the posterior ligaments between the atlas and axis. Moreover, Torremans et al.³³⁾ suggested that this might explain the delayed occurrence of symptoms of this congenital partial agenesis. The cumulative effects of minor cervical traumas may cause myelopathy. In our study, all 12 cases with defects of the atlantal posterior arch were found incidentally. Flexion and extension X-ray films of the cervical spine in one patient with a Type D defect revealed no movement of the posterior tubercle of the atlas. In this study, one case with defects in both anterior and posterior atlantal arches, anterior arch have incomplete arch defect (Fig. 4A, B). We think that this anatomical feature may contribute to asymptomatic presentation in patient with defect of both atlantal arches.

CONCLUSION

An arcuate foramen is not an uncommon anomaly. The presence of this anomaly should be carefully assessed before screw insertion into the lateral mass of the atlas. Preoperative 3D CT should be conducted before atlas lateral mass screw insertion. Occipitalization of the atlas considerably changes the anatomy of the upper cervical spine and CCJ. Preoperative diagnosis using 3D CT is of paramount importance for detecting these changes and avoiding neurovascular injury during surgery. Despite the low incidence of defects of the posterior arch of the atlas, we recommend that surgeons keep the possibility of its existence in mind when considering traumatic atlantoaxial subluxation and atlas fracture.

• Acknowledgements

This work was supported by research grant from a Pohang SM Christianity Hospital.

References

- Ahmad FU, Wang MY : Lateral mass of C1 fixation and ponticulus-posticus. *World Neurosurg* 82 : e145-e146, 2014
- Al-Motabagani MA, Surendra M : Total occipitalization of the atlas. *Anat Sci Int* 81 : 173-180, 2006,
- Bailey DK : The normal cervical spine in infants and children. *Radiology* 59 : 712-719, 1952
- Cakmak O, Gurdal E, Ekin G, Yildiz E, Cavdar S : Arcuate foramen and its clinical significance. *Saudi Med J* 26 : 1409-1413, 2005
- Curarino G, Rollins N, Diehl JT : Congenital defects of the posterior arch of the atlas : a report of seven cases including an affected mother and son. *AJNR Am J Neuroradiol* 15 : 249-254, 1994
- Cushing KE, Ramesh V, Gardner-Medwin D, Todd NV, Gholkar A, Baxter P, et al. : Tethering of the vertebral artery in the congenital arcuate foramen of the atlas vertebra : a possible cause of vertebral artery dissection in children. *Dev Med Child Neurol* 43 : 491-496, 2001
- Erbengi A, Oge HK : Congenital malformations of the craniovertebral junction : classification and surgical treatment. *Acta Neurochir (Wien)* 127 : 180-185, 1994
- Garg A, Gaikwad SB, Gupta V, Mishra NK, Kale SS, Singh J : Bipartite atlas with os odontoideum : case report. *Spine (Phila Pa 1976)* 29 : E35-E38, 2004
- Geipel P : [Studies on the fissure formation of the atlas and epistropheus. IV]. *Zentralbl Allg Pathol* 94 : 19-84, 1955
- Gupta S, Goel A : Quantitative anatomy of the lateral masses of the atlas and axis vertebrae. *Neurol India* 48 : 120-125, 2000
- Harrower G : Variations in the region of the foramen magnum. *J Anat* 57 (Pt 2) : 178-192, 1923
- Hong JT, Jang WY, Kim IS, Yang SH, Sung JH, Son BC, et al. : Posterior C1 stabilization using superior lateral mass as an entry point in a case with vertebral artery anomaly : technical case report. *Neurosurgery* 68 (1 Suppl Operative) : 246-249; discussion 249, 2011
- Huang MJ, Glaser JA : Complete arcuate foramen precluding C1 lateral mass screw fixation in a patient with rheumatoid arthritis : case report. *Iowa Orthop J* 23 : 96-99, 2003
- Kassim NM, Latiff AA, Das S, Ghafar NA, Suhaimi FH, Othman F, et al. : Atlanto-occipital fusion : an osteological study with clinical implications. *Bratisl Lek Listy* 111 : 562-565, 2010
- Klimo P Jr, Blumenthal DT, Couldwell WT : Congenital partial aplasia of the posterior arch of the atlas causing myelopathy : case report and review of the literature. *Spine (Phila Pa 1976)* 28 : E224-E228, 2003
- Koutsouraki E, Avdelidi E, Michmizos D, Kapsali SE, Costa V, Baloyannis S : Kimmerle's anomaly as a possible causative factor of chronic tension-type headaches and neurosensory hearing loss : case report and literature review. *Int J Neurosci* 120 : 236-239, 2010
- Lamberty BG, Zivanović S : The retro-articular vertebral artery ring of the atlas and its significance. *Acta Anat (Basel)* 85 : 113-122, 1973
- Li S, Li W, Sun J : [Operative treatment for cervical vertigo caused by foramen arcuale]. *Zhonghua Wai Ke Za Zhi* 33 : 137-139, 1995
- Limousin CA : Foramen arcuale and syndrome of Barre-Lieou. Its surgical treatment. *Int Orthop* 4 : 19-23, 1980
- Manjunath KY : Posterior bridging of the atlas vertebra in south Indians. *Indian J Med Sci* 55 : 488-490, 2001
- Menezes AH : Craniocervical developmental anatomy and its implications. *Childs Nerv Syst* 24 : 1109-1122, 2008
- Mitchell J : The incidence of the lateral bridge of the atlas vertebra. *J Anat* 193 (Pt 2) : 283-285, 1998
- Mudaliar RP, Shetty S, Nanjundaiah K, Kumar JB, Kc J : An osteological study of occipitocervical synostosis : its embryological and clinical significance. *J Clin Diagn Res* 7 : 1835-1837, 2013
- Paraskevas G, Papaziogas B, Tsonidis C, Kapetanios G : Gross morphology of the bridges over the vertebral artery groove on the atlas. *Surg Radiol Anat* 27 : 129-136, 2005
- Penning L : **Functional pathology of cervical spine**, ed 1. London : Excerpta medica foundation, 1968, Vol. 4, pp76
- Piper JG, Traynelis VC : Congenital malformations of the craniovertebral junction in Dickman CA, Spetzler RF, Sonntag VKH (eds) : **Surgery of the craniovertebral junction**. New York : Thieme Medical Publishers, 1998, pp123-149
- Richardson EG, Boone SC, Reid RL : Intermittent quadriparesis associated with a congenital anomaly of the posterior arch of the atlas. Case report. *J Bone Joint Surg Am* 57 : 853-854, 1975
- Sagiuchi T, Tachibana S, Sato K, Shimizu S, Kobayashi I, Oka H, et al. : Lhermitte sign during yawning associated with congenital partial aplasia of the posterior arch of the atlas. *AJNR Am J Neuroradiol* 27 : 258-260, 2006
- Sakai K, Tsutsui T : Bow hunter's stroke associated with atlantooccipital assimilation--case report. *Neurol Med Chir (Tokyo)* 39 : 696-700, 1999
- Sharma A, Gaikwad SB, Deol PS, Mishra NK, Kale SS : Partial aplasia of the posterior arch of the atlas with an isolated posterior arch remnant : findings in three cases. *AJNR Am J Neuroradiol* 21 : 1167-1171, 2000
- Skrzat J, Mróz I, Jaworek JK, Walocha J : A case of occipitalization in the human skull. *Folia Morphol (Warsz)* 69 : 134-137, 2010
- Split W, Sawrasiewicz-Rybak M : [Clinical symptoms and signs in Kimmerle anomaly]. *Wiad Lek* 55 : 416-422, 2002
- Torremans M, Verhagen IT, Sluzewski M, Kok AJ, van Rooij WJ : Recurrent transient quadriparesis after minor cervical trauma associated with bilateral partial agenesis of the posterior arch of the atlas. Case report. *J Neurosurg* 84 : 663-665, 1996
- Travan L, Saccheri P, Sabbadini G, Crivellato E : Bilateral arcuate foramen associated with partial defect of the posterior arch of the atlas in a medieval skeleton : case report and review of the literature. Looking backward to go forward. *Surg Radiol Anat* 33 : 495-500, 2011
- Tubbs RS, Shoja MM, Shokouhi G, Farahani RM, Loukas M, Oakes WJ : Simultaneous lateral and posterior ponticles resulting in the formation of a vertebral artery tunnel of the atlas : case report and review of the literature. *Folia Neuropathol* 45 : 43-46, 2007
- Wang S, Wang C, Liu Y, Yan M, Zhou H : Anomalous vertebral artery in craniovertebral junction with occipitalization of the atlas. *Spine (Phila Pa 1976)* 34 : 2838-2842, 2009
- Wight S, Osborne N, Breen AC : Incidence of ponticulus posterior of the atlas in migraine and cervicogenic headache. *J Manipulative Physiol Ther* 22 : 15-20, 1999
- Wysocki J, Bubrowski M, Reymond J, Kwiatkowski J : Anatomical variants of the cervical vertebrae and the first thoracic vertebra in man. *Folia Morphol (Warsz)* 62 : 357-363, 2003
- Young JP, Young PH, Ackermann MJ, Anderson PA, Riew KD : The ponticulus posticus : implications for screw insertion into the first cervical lateral mass. *J Bone Joint Surg Am* 87 : 2495-2498, 2005