

Technical Note

Endovascular Rescue Method for Undesirably Stretched Coil

Jae Hoon Cho, M.D.

Department of Neurosurgery, Daegu Catholic University College of Medicine, Daegu, Korea

Undesirable detachment or stretching of coils within the parent artery during aneurysm embolization can be related with thrombus formation, which can be caused occlusion of parent artery or embolic event(s). To escape from this situation, several rescue methods have been reported. A case with undesirably stretched coil in which another rescue method was used, is presented. When the stretched coil is still located in the coil delivery microcatheter, the stretched coil can be removed safely using a snare and a handmade monorail microcatheter. After a snare is lodged in the handmade monorail microcatheter, the snare is introduced over the coil delivery microcatheter and located in the distal part of the stretched coil. After then, the handmade monorail microcatheter captures the stretched coil and the snare as one unit. This technique using a handmade monorail microcatheter and a snare can be a good rescue modality for the undesirably stretched coil, still remained within the coil delivery microcatheter.

Key Words : Intracranial aneurysm · Embolization · Complication · Removal.

INTRODUCTION

Endovascular treatment of intracranial aneurysms has advanced as the endovascular techniques and equipments including coils, stents, and microcatheters have been developed. However, unpredictable serious situations can be occurred in some complicated cases. Coil stretching is one of unpredictable dangerous conditions and this condition could result in difficult embolization, thromboembolic event or parent vessel occlusion. There are several rescue methods for the removal of the stretched coil. Here, the author reports experiences in which successful removal of the stretched coil using a snare and a handmade monorail microcatheter was achieved.

CASE REPORT

In a 60-year-old female with an unruptured paraclinoid aneurysm, which size was 3.5 (neck)×4.5 (height)×5.3 (width)×3.7 (depth) mm, coil embolization was scheduled under the general anesthesia (Fig. 1).

A 6 Fr Envoy (Codman Neurovascular, Raynham, MA, USA) guiding catheter was placed in the upper neck portion and the aneurysm was catheterized using two J-shaped Excelsior-10 microcatheters (Stryker Neurovascular, Fremont, CA, USA) over a Syn-

cro-14 microwire (Stryker Neurovascular, Fremont, CA, USA).

After successful displacement of two coils (GDC 360 5 mm×9

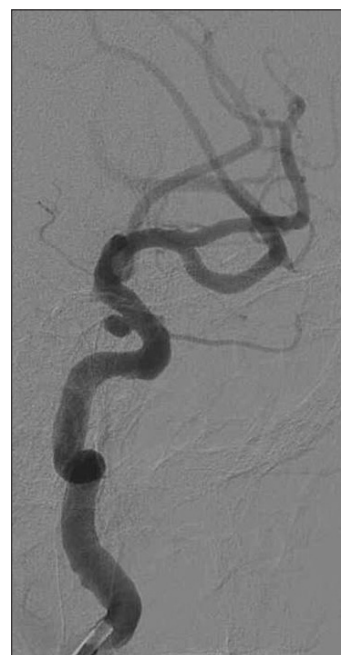

Fig. 1. Left internal carotid angiography shows a paraclinoid aneurysm.

• Received : December 16, 2013 • Revised : January 20, 2014 • Accepted : September 6, 2014

• Address for reprints : Jae Hoon Cho, M.D.

Department of Neurosurgery, Daegu Catholic University College of Medicine, 33 Duryugongwon-ro 17-gill, Nam-gu, Daegu, 705-718, Korea
Tel : +82-53-650-4258, Fax : +82-53-650-4932, E-mail : fhjcho@gmail.com

• This is an Open Access article distributed under the terms of the Creative Commons Attribution Non-Commercial License (<http://creativecommons.org/licenses/by-nc/3.0>) which permits unrestricted non-commercial use, distribution, and reproduction in any medium, provided the original work is properly cited.

cm & GDC US 3 mm×6 cm; Stryker Neurovascular, Fremont, CA, USA), 2 mm×4 cm Axium™ coil (ev3, Irvine, CA, USA) as third coil was used for complete packing of the neck portion of

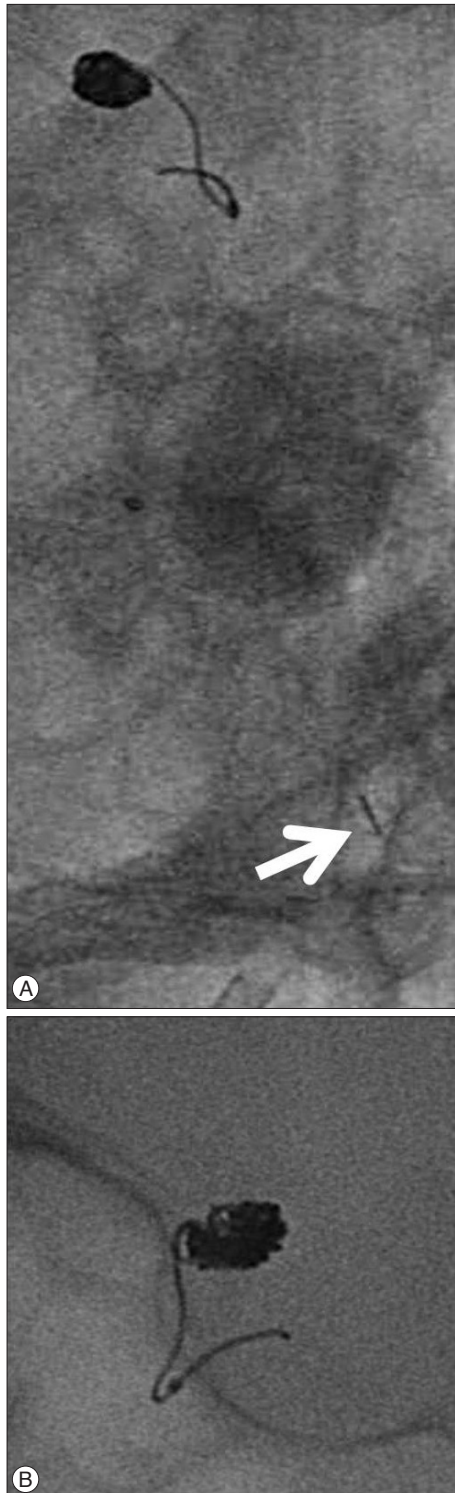

Fig. 2. A : Intraoperative angiography (anterior-posterior projection) demonstrates stretching of the coil. The white arrow indicates the proximal marker of coil pusher wire. B : Angiography (lateral projection) reveals that proximal portion of the stretched coil is still remained within the coil delivery catheter.

the aneurysm. After the coil advanced about 1 cm, further advancement was not possible. We decided to remove the third coil and replace it with another shorter coil. During the procedure, coil stretching was identified at the proximal portion of the coil, which was still within the coil delivery microcatheter (Fig. 2).

In order to removal of the stretched coil within delivery catheter, we first prepared a 2-mm Amplatz GooseNeck microsnare (Microvena Corp., WhiteBear Lake, MN, USA) and cut away the hub portion of the coil delivery microcatheter for the insertion of a goose neck snare over the catheter (a monorail guide). After the snare was introduced into the guiding catheter, the coil delivery microcatheter was fixed with a mosquito forcep to prevent the shift of the delivery catheter and the stretched coil. However, within a 6 Fr Envoy (Codman Neurovascular) guiding catheter, the coil delivery catheter and a snare catheter within the kit were not operated properly due to their profiles. We speculated the reason due to problem(s) originated from their profiles and/or thrombosis within the guiding catheter. So, we decided to exchange the snare catheter into another microcatheter such as Prowler Select Plus microcatheter (Codman Neurovascular, Raynham, MA, USA) which outer diameter (OD) is 2.8 Fr. It is compatible with Exceisior SL-10 microcatheter in 6 Fr Envoy (Codman Neurovascular) guiding catheter. This microcatheter has been used in stent-assisted coiling for the delivery of an intracranial stent. We thought that this microcatheter would provide enough space for the microsnare and the stretched coil. We re-

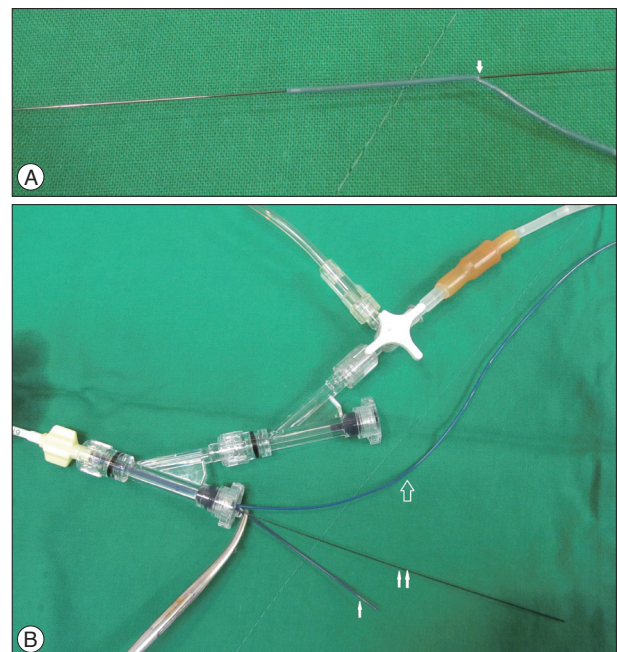


Fig. 3. A : Photograph showing the handmade monorail Prowler Select Plus microcatheter bearing the snare wire. An arrow indicates a side hole, near 2 cm from the distal end such as a monorail microcatheter. B : Photograph showing the external environment. Note the application of a mosquito forceps to fix the coil delivery catheter (cut) (arrow) for the prevention of shifting of the catheter and the coil. A double arrow indicates the proximal part of the snare and an open arrow indicates the monorailed Prowler Select Plus microcatheter.

moved the snare catheter from the field, leaving the snare within the guiding catheter. With the aid of the proximal portion of the snare which distal part was still over the coil delivery micro-

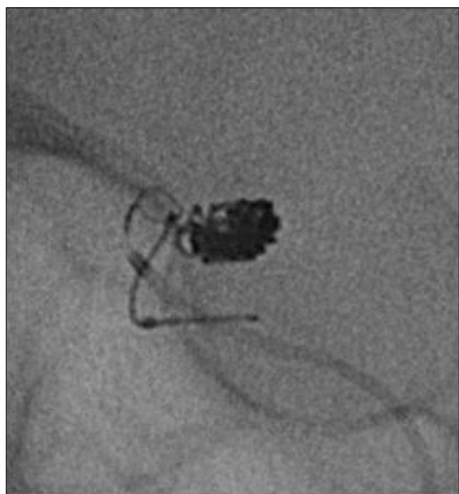


Fig. 4. Angiography (lateral projection) demonstrates that the location of the snare is located in the distal part of the stretched coil.

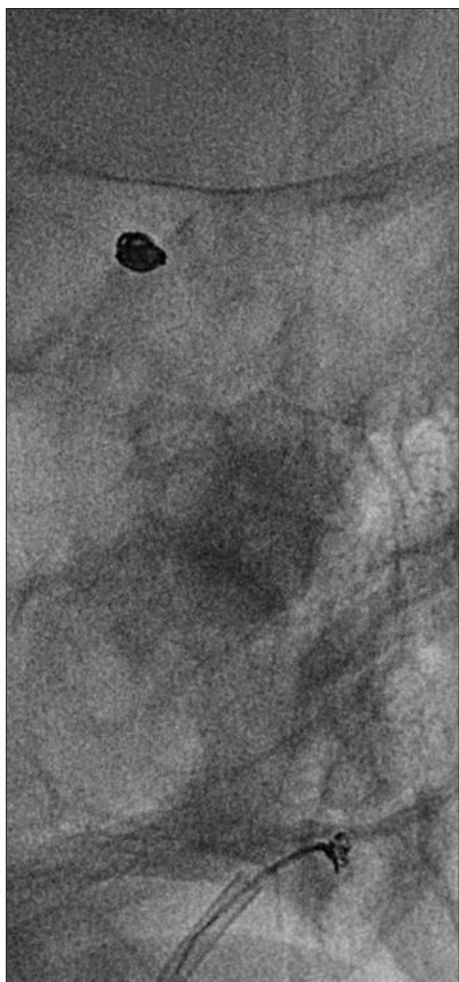


Fig. 5. The handmade monorail microcatheter captures the stretched coil and the snare as one unit.

catheter, we made the Prowler Select Plus microcatheter into the catheter having one side hole, near 2 cm from the distal end such as a monorail microcatheter. This manipulation is relatively easy (Fig. 3). After the snare was located in the unstretched distal part of the stretched coil (Fig. 4), the handmade monorail microcatheter captured the stretched coil and the snare as one unit. Careful retrieval of the system from the aneurysm was achieved successfully (Fig. 5) and further coiling with two coils was done uneventfully.

DISCUSSION

There have been significant advances in the endovascular techniques and devices for the treatment of intracranial aneurysms over recent years since the introduction of the Guglielmi detachable coil system (Target Therapeutics, Fremont, CA, USA) in the early 1990s^{2,3}. However, unpredictable situations such as thromboembolic events, aneurysmal rupture by microcatheter, coil(s) or wire, and stretching of coil can be occurred in some complicated cases.

Coil stretching is one of unpredictable conditions and this condition could result in difficult embolization, thromboembolic event(s) or parent vessel occlusion. To escape from this situation, several rescue methods have been reported^{1,5,6}.

Standard et al.⁶ reported a dual-guide wire technique in 1994. The aim of the authors is to jam a portion of the stretched coil using two 0.010-inch microwires. However, this technique died out today because a 0.021-inch-internal diameter catheter such as Track-18 microcatheter is no longer used initially for routine embolization of intracranial aneurysms.

Lee⁵ reported the use of wire as a snare for endovascular retrieval of displaced or stretched coils. In his report, he presented a case of coil stretching, in which the stretched coil within the coil delivery microcatheter was removed with the aid of a wire with a J-shaped tip. However, it appears somewhat difficult and dangerous because intimal damage of the parent artery by the wire, resultant thromboembolic event, and lack of pulling force may be possible. Fiorella et al.¹ reported monorail snare technique using a 2-mm Amplatz Goose Neck microsnare and a Prowler-14 microcatheter. In their report, one unit system composed of the snare and Prowler-14 microcatheter was advanced into the guiding catheter (6- or 7-Fr) over the indwelling SL-10 microcatheter. The SL-10 microcatheter and coil pusher wire worked as a "monorail" guide. After the snare was advanced over the stretched portion of the coil, the snare engaged the distal unstretched portion of the coil. The intact distal portion of the coil was then secured as the snare was gently retracted into the Prowler-14 microcatheter. With the same technique, Kelly et al.⁴ reported the retrieval of an adherent microcatheter from an Onyx cast.

Our case resembles the report of Fiorella et al.¹ closely. Initially, we tried the removal of the stretched coil with a snare kit provided by the company. However, within a 6 Fr guiding catheter, a coil delivery microcatheter and a snare catheter within the kit

were not operated properly. Consideration on the compatibility with multiple indwelling devices is very important during complex endovascular procedure. According to the brochure provided by Codman & Shurtleff, Inc., the inner diameter of 6 Fr Envoy (Codman Neurovascular) guiding catheter is 0.070 inch and is compatible with a 2.3 Fr microcatheter and a microcatheter less than 2.9 Fr. Proximal and distal OD of Excelsior SL-10 microcatheter is 2.4 Fr and 1.7 Fr respectively. Because the proximal size of Goose Neck Snare is 3 Fr, smaller microcatheter is needed to minimize resistance between devices. So, we decided to exchange the snare catheter into the microcatheter such as Prowler Select Plus microcatheter compatible with 6 Fr Envoy (Codman Neurovascular) guiding catheter. The rate of flushing with heparinized saline was also increased. Prowler Select Plus microcatheter which is widely used in stent assisted coiling has smaller size of outer diameter (distal 2.3 Fr and proximal 2.8 Fr) than the catheter size of an Amplatz GooseNeck snare, which is from 2.3 Fr (distal) to 3 Fr (proximal).

If the stretched coil is still located in the coil delivery microcatheter, the stretched coil can be removed safely using our technique without any specific difficulty. For the use of this meaningful method, it is important to recognize early the coil stretching and to maintain the stretched coil within the coil delivery catheter. During the procedure, it is necessary to make an effort to reduce the procedural time and to increase the flushing rate with heparinized saline to prevent possible thromboembolic events because the backflow through hemostasis valve is increased during the procedure. With careful monitoring and prevention, shift-

ing of the coil delivery microcatheter and the coil must be reduced as much as possible.

CONCLUSION

The technique using a handmade monorail microcatheter and a snare can be a good rescue modality for the undesirably stretched or detached coil, still remained within a coil delivery microcatheter.

References

1. Fiorella D, Albuquerque FC, Deshmukh VR, McDougall CG : Monorail snare technique for the recovery of stretched platinum coils : technical case report. *Neurosurgery* 57 (1 Suppl) : E210; discussion E210, 2005
2. Guglielmi G, Viñuela F, Dion J, Duckwiler G : Electrothrombosis of saccular aneurysms via endovascular approach. Part 2 : Preliminary clinical experience. *J Neurosurg* 75 : 8-14, 1991
3. Guglielmi G, Viñuela F, Sepetka I, Macellari V : Electrothrombosis of saccular aneurysms via endovascular approach. Part 1 : electrochemical basis, technique, and experimental results. *J Neurosurg* 75 : 1-7, 1991
4. Kelly ME, Turner R 4th, Gonugunta V, Rasmussen PA, Woo HH, Fiorella D : Monorail snare technique for the retrieval of an adherent microcatheter from an onyx cast : technical case report. *Neurosurgery* 63 (1 Suppl 1) : ONSE89; discussion ONSE89, 2008
5. Lee CY : Use of wire as a snare for endovascular retrieval of displaced or stretched coils : rescue from a technical complication. *Neuroradiology* 53 : 31-35, 2011
6. Standard SC, Chavis TD, Wakhloo AK, Ahuja A, Guterman LR, Hopkins LN : Retrieval of a Guglielmi detachable coil after unraveling and fracture : case report and experimental results. *Neurosurgery* 35 : 994-998; discussion 999, 1994