

## Case Report

# Pure Intramuscular Osteolipoma

Jin Seo Yang, M.D., Suk Hyung Kang, M.D., Ph.D., Yong Jun Cho, M.D., Ph.D., Hyuk Jai Choi, M.D., Ph.D.

Department of Neurosurgery, Spine Center, Chuncheon Sacred Heart Hospital, College of Medicine, Hallym University, Chuncheon, Korea

Ossified lipoma or osteolipoma are rarely reported. It is defined as a histologic variant of lipoma that has undergone osseous metaplasia. Osteolipoma presents with a dominant osseous component within a lipoma. We report a case of a histologically confirmed osteolipoma on the nuchal ligament independent of bone. The patient was a 51-year-old female who presented with a 5-year history of a painless, progressively enlarging mass on the posterior neck. Computed tomography and magnetic resonance imaging showed a circumscribed mass compatible with fat between the C2 and C6 spinous processes with a large calcified irregular component. The mass with dual components was totally removed under general anesthesia and no recurrence was observed after 6 months of follow-up. We also reviewed the clinicopathologic features of previously reported osteolipomas in the literature and suggest that although osteolipoma is a rare variant of lipoma, it should be considered in the differential diagnosis when a lipoma of the posterior neck mixed with a bony component is encountered.

**Key Words :** Lipoma · Osteolipoma · Ossified lipoma · Ossifying lipoma · Lipomatous tumor.

## INTRODUCTION

Lipoma is a common benign soft tissue neoplasm that sometimes may have mixed tissue components. Lipomas with mixed components are named according to the type of tissue. Ossification of a lipoma was first described in 1959, and it is rarely reported<sup>[7,16]</sup>. Several names have been used to describe ossification of lipomas, including secondary calcification, ossified lipoma, ossifying lipoma, or osteolipoma, and some authors have used these terms interchangeably. As with classic lipomas, lipomas with ossifications may be found in any part of the body, but are usually found in the head, neck, oral cavity, and extremities, adjacent to bone. Only two cases of osteolipoma arising in connection with vertebrae have been described. Here, we present a case of an intramuscular osteolipoma on the posterior neck, independent of vertebrae, and review the clinicopathologic features of osteolipoma previously published in the literature.

## CASE REPORT

A 51-year-old female presented with a 5-year history of a painless, progressively enlarging mass on the posterior neck.

She reported neck stiffness without associated neurological symptoms. Physical examination revealed a soft, non-tender, uniform mass without surface abnormalities. Computed tomography (CT) and magnetic resonance imaging (MRI) showed a circumscribed mass involving the posterior neck muscles in the midline between the C2 and C6 spinous processes with a large calcified component (Fig. 1). The ovoid mass was measured 4 cm in width, 6 cm in length, and 3 cm in height, without infiltration of the cervical spine. Subsequently, the patient underwent a whole body bone scan, which revealed an amorphous calcification of the posterior neck without metastasis (Fig. 2).

We performed tumor resection under general anaesthesia. The mass had a well-demarcated margin and the outer wall was very firm without adhesion to ligaments or paravertebral muscles. Gross examination revealed a well-circumscribed mass composed of adipose and bony tissue, with red bone marrow visible on the cut surface (Fig. 3). Histological study showed a lipomatous lesion with large foci of osseous metaplasia at the periphery of the mass; the bony portion was surrounded by mature adipose tissue (Fig. 4A). Microscopic examination of the red bone marrow showed a meshwork of bone trabeculae and hematopoietic marrow elements (Fig. 4B).

• Received : May 30, 2013 • Revised : September 29, 2013 • Accepted : December 12, 2013

• Address for reprints : Suk Hyung Kang, M.D., Ph.D.

Department of Neurosurgery, Chuncheon Sacred Heart Hospital, College of Medicine, Hallym University, 77 Sakju-ro, Chuncheon 200-704, Korea  
Tel : +82-33-240-5173, Fax : +82-33-242-9970, E-mail : nscharisma@hanmail.net

• This is an Open Access article distributed under the terms of the Creative Commons Attribution Non-Commercial License (<http://creativecommons.org/licenses/by-nc/3.0>) which permits unrestricted non-commercial use, distribution, and reproduction in any medium, provided the original work is properly cited.

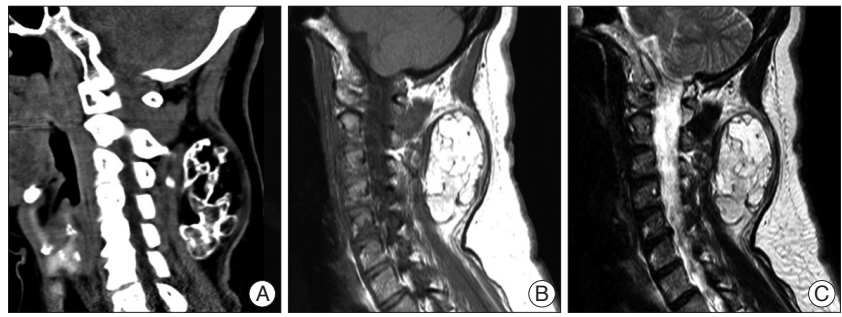
The patient was diagnosed with an intramuscular osteolipoma of the posterior neck and no recurrence was observed at the 6-month follow-up.

## DISCUSSION

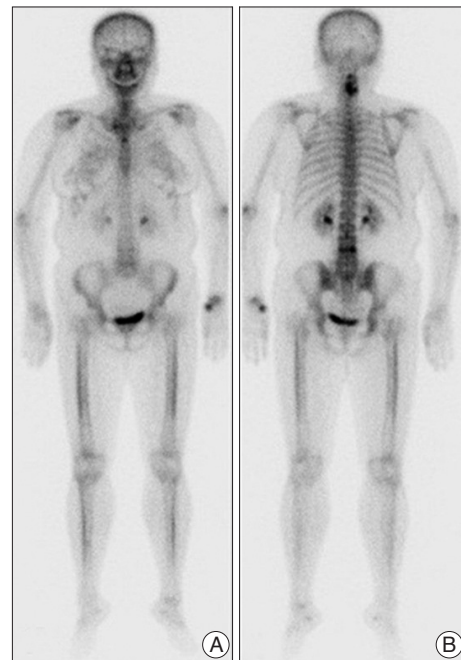
A lipoma is a common soft tissue neoplasm, but lipomas with distinct osseous components are rare<sup>2-4,8,10-12,14,15</sup>. As noted by Heffernan et al.<sup>11</sup>, in Allen's review of 635 cases, less than 1% of lipomas were ossified. Further, as reported by de Castro, et al.<sup>5</sup>, when Furlong analyzed histological findings from a group of 125 lipomas of the oral and maxillofacial region, there was no variant that presented as osseous metaplasia. Lipomas presenting with osseous components have been reported as secondary calcification of lipoma or ossified lipoma<sup>4,12,14</sup>. Secondary calcification of lipoma involves calcification that progresses from the periphery inwards as a result of necrosis after impaired blood supply or repeated microtrauma<sup>5,14</sup>. An ossified lipoma is defined as a histologic variant of lipoma that has undergone osseous metaplasia, and can be classified into 2 groups according to the predominance of the osseous component: ossifying lipoma and osteolipoma. If the adipose component of the lipoma is more dominant than the osseous component, it is an ossifying lipoma, whereas an osteolipoma presents with a dominant osseous component<sup>14</sup>. The terms have been used interchangeably.

Osteolipomas have been reported in middle aged or elderly patients presenting with large painless masses with a long duration, even years, and they may be found incidentally<sup>2,7</sup>. There are no reports indicating gender predilection. They have been reported at various sites located adjacent to bone or periosteum, including upper and lower extremity, oral mucosa, soft tissue of neck, and intracranial regions, including tuber cinereum, hypothalamus, suprasellar cistern, and the interhemispheric area<sup>1-5,7,10-15,17,18</sup>. Only 2 cases of spinal osteolipoma have been described. One patient was an 8-year-old female who presented with a progressively enlarging swelling over the lumbar region with a dermal sinus tract<sup>12</sup>, and other was 20-year-old female with a cervical osteolipoma contained within the spinal canal<sup>14</sup>. Both lesions had some continuity to adjacent bone. In the case presented here, the osseous lipoma was located in the deep neck musculature, independent of bony vertebral structures.

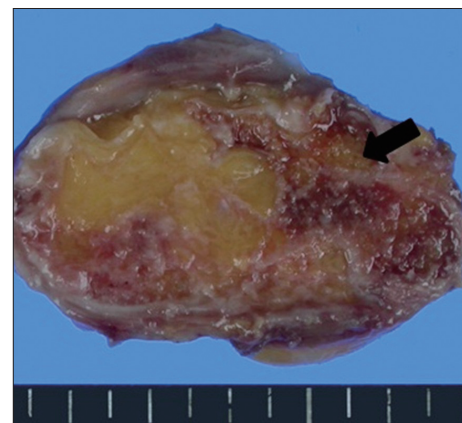
There are several hypotheses regarding the pathogenetic mechanisms that influence the osseous metaplasia of lipomas, but the details are still not clear. There are two generally accepted theories for osseous metaplasia<sup>3,4,6,8,13</sup>. First, these tumours may originate from multipotent mesenchymal cells that can differentiate into lipoblasts, chondroblasts, fibroblasts, angioblasts, and osteoblasts. This could account for the several lipomatous variations of classic lipomas, i.e. lipoblastoma, lipomatosis, fibrolipoma, angiolipoma, myolipoma, myelolipoma,



**Fig. 1.** Preoperatively CT (A : sagittal) and sagittal MRI (B : T1-weighted, C : T2-weighted) revealing a irregular calcification involving posterior neck within soft tissue mass compatible with fat tissue.



**Fig. 2.** Whole body bone scan (A : anterior, B : posterior) shows an amorphous calcification mass with increased uptake, and no bone metastases.



**Fig. 3.** Grossly, the tumor consists largely of fat and calcification presented with the red bone marrow (black arrow).

hibernoma, and atypical lipoma, and mesenchymoma is defined as a rare soft tissue lesion that is composed of fibrous tissue associated with two or more types of well differentiated

mesenchymal cells that would not normally be found in the same area<sup>2,7</sup>. Second, ossification may also have been induced by poor nutritional supply in the centre of a large lipoma after repetitive trauma, metabolic changes, or ischemia leading to transformation of fibroblasts into osteoblasts<sup>2,8</sup>. Fritchie et al.<sup>8</sup> reported cytogenetic analyses of three osteolipomas and reported that the translocations in all cases were consistent with the karyotypic features of lipoma. Thus, osteolipoma is a variant of classic lipoma.

Other benign tumors that may contain bone including teratomas or dermoids, masses with secondary ossification due to trauma, liposarcomas with metaplastic changes, or congenital malformations, should be considered in the differential diagnosis. In addition, tumour calcinosis, calcification in a bursa, and other conditions such as ossifying fibromas, myositis ossificans, and osteosarcomas should be taken into consideration. The use of CT scanning provides excellent visualization of the calcified or ossified components of a lipoma and confirmation of proximity to adjacent bone, and MR imaging can also provide detailed information that is useful for further evaluation<sup>2,9</sup>.

Definitive diagnosis of osteolipoma can be made with histopathologic findings after surgical excision, which is usually the recommended treatment. A histopathologic appearance of diffuse, mature ossification within adipose tissue and gross features demonstrating a dominant osseous component confirm the diagnosis. Histologically confirmed osteolipomas are benign neoplasms, as with classic lipomas, and do not recur<sup>2,4-6,11</sup>.

## CONCLUSION

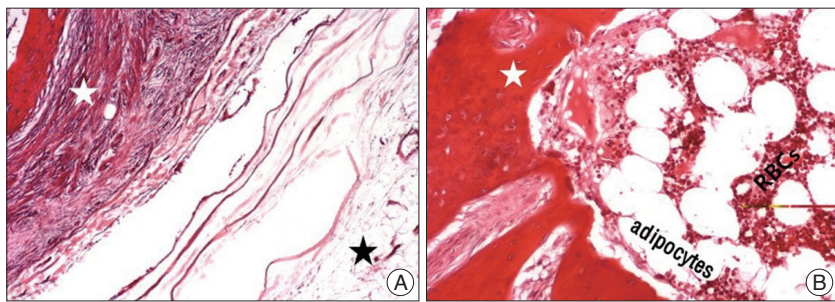
To the best of our knowledge, it is the first case report of an intramuscular osteolipoma within the posterior neck independent of adjacent bone. We suggest that although osteolipoma is a rare variant, it is important to keep it in mind when a soft tissue mass of the posterior neck mixed with osseous component is encountered.

### Acknowledgements

This study was supported by BioGreen21 Program (PJ009051) of Rural Development Administration.

### References

1. Abdalla WM, da Motta AC, Lin SY, McCarthy EF, Zinreich SJ : Intraosseous lipoma of the left frontoethmoidal sinuses and nasal cavity. *AJNR Am J Neuroradiol* 28 : 615-617, 2007
2. Adebisi KE, Ugboko VI, Maaji SM, Ndubizu G : Osteolipoma of the



**Fig. 4.** There is a large foci of osseous metaplasia (white star) and at the periphery of the mass, the bony portion is surrounded by mature adipose tissue (black star) [A : hematoxylin & eosin (H-E), ×40]. Microscopic appearance of red bone marrow shows a meshwork of bone trabeculae (white star) and hematopoietic marrow elements (B : H-E, ×100).

- palate : report of a case and review of the literature. *Niger J Clin Pract* 14 : 242-244, 2011
3. Bohm KC, Birman MV, Silva SR, Lesperance MM, Marentette LJ, Beyer GR, et al : Ossifying lipoma of c1-c2 in an adolescent. *J Pediatr Orthop* 31 : e53-e56, 2011
4. Brones A, Mengshol S, Wilkinson CC : Ossifying lipoma of the cervical spine. *J Neurosurg Pediatr* 5 : 283-284, 2010
5. de Castro AL, de Castro EV, Felipini RC, Ribeiro AC, Soubhia AM : Osteolipoma of the buccal mucosa. *Med Oral Patol Oral Cir Bucal* 15 : e347-e349, 2010
6. Demiralp B, Alderete JF, Kose O, Ozcan A, Cicek I, Basbozkurt M : Osteolipoma independent of bone tissue : a case report. *Cases J* 2 : 8711, 2009
7. Demirkan F, Demirkan N : Ossifying lipoma at the wrist. *Aegean Pathol J* 1 : 19-21, 2004
8. Fritchie KJ, Renner JB, Rao KW, Esther RJ : Osteolipoma : radiological, pathological, and cytogenetic analysis of three cases. *Skeletal Radiol* 41 : 237-244, 2012
9. Gaskin CM, Helms CA : Lipomas, lipoma variants, and well-differentiated liposarcomas (atypical lipomas) : results of MRI evaluations of 126 consecutive fatty masses. *AJR Am J Roentgenol* 182 : 733-739, 2004
10. Gokul S, Ranjini KV, Kirankumar K, Hallikeri K : Congenital osteolipoma associated with cleft palate : a case report. *Int J Oral Maxillofac Surg* 38 : 91-93, 2009
11. Heffernan EJ, Lefaivre K, Munk PL, Nielsen TO, Masri BA : Ossifying lipoma of the thigh. *Br J Radiol* 81 : e207-e210, 2008
12. Jaiswal AK, Garg A, Mahapatra AK : Spinal ossifying lipoma. *J Clin Neurosci* 12 : 714-717, 2005
13. Jamshidi K, Qomashi I, Shirazi MR : An unusual location of ossified intramuscular lipoma : a case report. *Acta Med Iran* 49 : 630-632, 2011
14. Lin YC, Huang CC, Chen HJ : Intraspinal osteolipoma. Case report. *J Neurosurg* 94 (1 Suppl) : 126-128, 2001
15. Park YS, Kwon JT, Park US : Interhemispheric osteolipoma with agenesis of the corpus callosum. *J Korean Neurosurg Soc* 47 : 148-150, 2010
16. Plaut GS, Salm R, Truscott DE : Three cases of ossifying lipoma. *J Pathol Bacteriol* 78 : 292-295, 1959
17. Sathe PA, Vaideeswar P : Unusual rib tumor : parosteal lipoma with extensive osteochondromatous metaplasia. *Indian J Pathol Microbiol* 51 : 525-527, 2008
18. Simsek T, Sonmez A, Aydogdu IO, Eroglu L, Karagoz F : Giant fibrolipoma with osseous metaplasia on the thigh. *J Plast Reconstr Aesthet Surg* 64 : e125-e127, 2011