

“Island Hole” Dural Tenting Suture on the Temporal Craniotomy for the Prevention of Epidural Hemorrhage in the Surgical Treatment of Unruptured Intracranial Aneurysms

Minchang Kim,¹ In-Chul Yang,² Bum-Tae Kim^{1,2}

College of Medicine,¹ Soonchunhyang University, Asan, Korea

Department of Neurosurgery,² Soonchunhyang University Bucheon Hospital, Bucheon, Korea

To the Editor,

The authors read the paper “Comparison between lateral supraorbital approach and pterional approach in the surgical treatment of unruptured intracranial aneurysms” by Cha et al.¹⁾ They concluded that the lateral supraorbital approach provides adequate exposure of the lesion and allows much shorter operation time and much smaller craniotomy, thereby decreasing surgical morbidity compared with the classic pterional approach. However, the epidural hemorrhage occurred in two cases in both methods.

A fronto-temporal approach is a surgical procedure that temporarily removes the skull to access the brain. One of the main complications of this operation is postoperative epidural hemorrhage. Dural tenting suture, the so-called tack-up suture, has proved its efficient control of arterial or venous bleeding from the surrounding epidural space beneath the edges of a craniotomy by elevating the dura mater using sutures to create a “tenting” effect⁴⁾. Moreover, it is effective in expanding the surgical field. The surgical viewing angle can be widened by lifting the dura.

It is difficult for the base of the temporal bone to elevate the dura mater and perform dura tenting without damaging adjacent structures due to small and narrow working spaces and limited visibility due to the middle meningeal artery and temporalis muscle.

After the skin incision, the temporalis muscle is lifted. When incising the innermost part (muscle-bearing side) to open the skull, a part of the skull is cut deeply to expose the middle meningeal artery, and then an incision in the periphery is made, protruding approximately 5×5 mm for fixation (Fig. 1), which is called the “island.” Then, a “hole” (2 mm diameter) is drilled for tenting the suture on the “island” using a blunt saw. Next, the dura mater and the island are sutured using a 4-0 ETHICON silk. Then, additional tenting sutures at the other parts are made, the dura mater is incised, and the surgery is initiated.

A 43-year-old female patient was initially found to have a lobulated, unruptured 6×3.3 mm sized right middle cerebral artery bifurcation (MCAB) aneurysm on the right temporal base sylvian cistern. Craniotomy was performed using the “island hole” dural tenting suture (Fig. 2). A lobulated MCAB

• Received : June 22, 2023 • Accepted : July 26, 2023

• Address for correspondence : **Bum Tae Kim**

Department of Neurosurgery, Soonchunhyang University Bucheon Hospital, 170 Jomaru-ro, Bucheon 14584, Korea

Tel : +82-32-621-5059, Fax : +82-32-621-6950, E-mail : bumtkim@gmail.com, ORCID : <https://orcid.org/0000-0003-2646-8165>

This is an Open Access article distributed under the terms of the Creative Commons Attribution Non-Commercial License (<http://creativecommons.org/licenses/by-nc/4.0>) which permits unrestricted non-commercial use, distribution, and reproduction in any medium, provided the original work is properly cited.

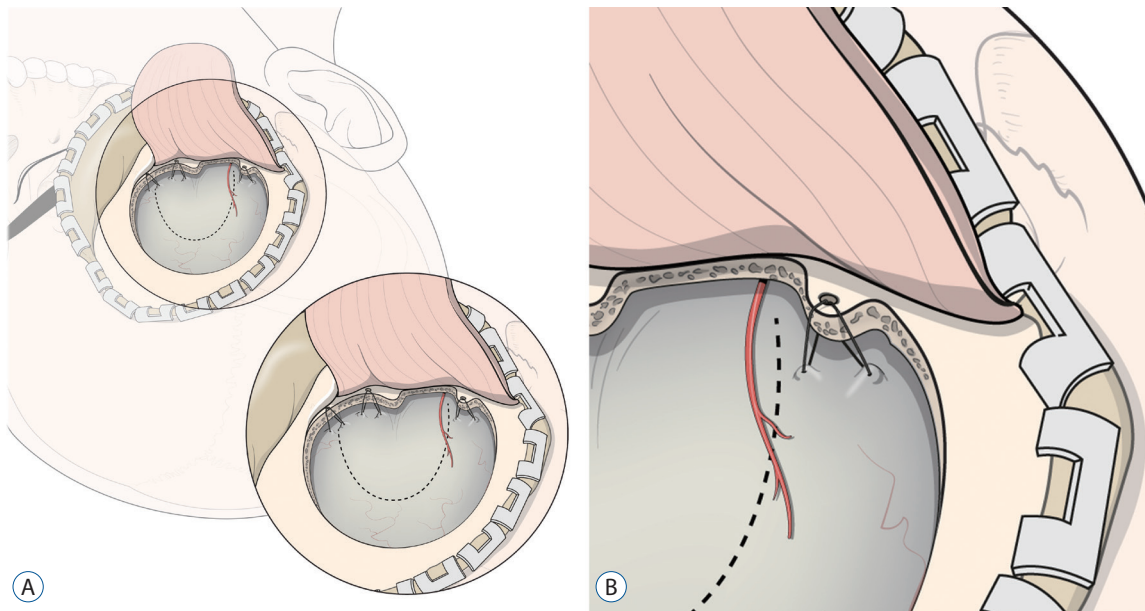


Fig. 1. Schematic drawing of “island hole” dural tenting suture in the temporal base during frontotemporal craniotomy (A and B). A red colored line on the dura mater indicates the middle meningeal artery. A curve-linear dotted line indicates the dural incision.

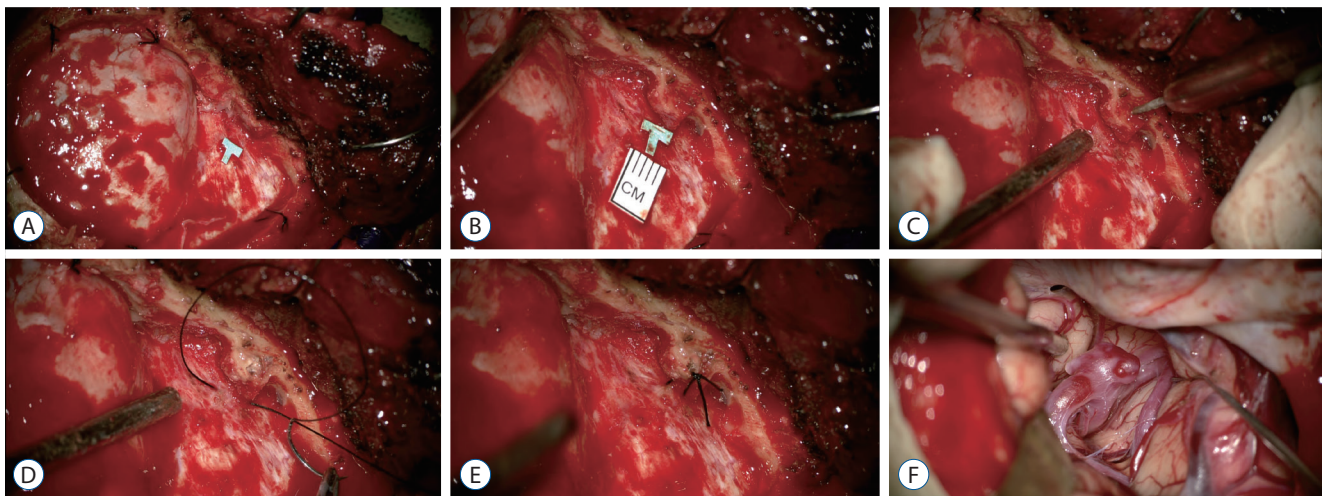


Fig. 2. Step-by-step procedures of “island hole” dural tenting suture in a 43-year-old female patient. Frontotemporal craniotomy was performed to reveal the dura mater. An incision in the periphery protruding approximately 5×5 mm for fixation has been made, and a letter “T” means the temporal dura mater (A and B). A small hole has been made in the protruded bone (C). The dura mater and island were sutured using a 4-0 ETHICON silk (D and E). A lobulated middle cerebral artery bifurcation aneurysm has been exposed with a sufficient operative field (F).

aneurysm has been exposed with a sufficient operative field. There was no complication related to these procedures.

A dural tenting suture is currently used in several craniotomies and has a high degree of performer satisfaction and preference^{3,6)}. Our institution devised the “island hole” dural tenting suture technique in 2019 and has been using it for clipping surgery. To date, no specific complications or problems have occurred.

Dural tenting is usually performed to reduce venous bleeding in the epidural space at the end of the surgery. It is also performed prior to the main surgery to widen the surgical field in micro-surgery. After performing the dural tenting with a simple pulling movement, the surgical viewing angle is widened. The difficulty of micro-surgery can vary depending on whether more space can be secured. In deep brain surgery, endoscopic surgery has not yet become popular. Inevitably,

deep brain surgery using a microscope is only possible; thus, deep brain surgery is unwillingly carried out in a very small space. Therefore, when performing deep brain surgery, it is necessary to make a large craniotomy for a large surgical field. However, most patients want minimal invasive surgery for cosmetic purposes. Therefore, minimal scalp incision and minimal craniotomy became necessary. Using our technique, a small effort in the process of craniotomy can create a few millimeters of larger space in the surgical field. These few millimeters will make the operation easier, reduce the operation time, and positively affect the patient.

In recently published journals, there is a debate on the relevance of dural tenting sutures to the reduction of postoperative epidural hemorrhage^{2,5)}. However, from the perspective of expanding the surgical field in micro-surgery, this is a sufficiently valuable procedure. If this technique is used, the risk during the procedure can be lowered.

The “island hole” dural tenting suture in temporal base craniotomy has the advantage of widening the surgical field to facilitate the process of intradural surgery and prevent postoperative epidural hemorrhage.

AUTHORS' DECLARATION

Conflicts of interest

No potential conflict of interest relevant to this article was reported.

Informed consent

This type of study does not require informed consent.

Author contributions

Conceptualization : BTK; Data curation : MK, BTK; Funding acquisition : BTK; Methodology : MK, ICY, BTK; Writing - original draft : MK, BTK; Writing - review & editing : ICY, BTK

Data sharing

None

Preprint

None

ORCID

Minchang Kim	https://orcid.org/0000-0003-4029-7569
In-Chul Yang	https://orcid.org/0000-0002-3696-8190
Bum-Tae Kim	https://orcid.org/0000-0003-2646-8165

• Acknowledgements

This work was supported by Soonchunhyang University Research Fund.

References

1. Cha KC, Hong SC, Kim JS : Comparison between lateral supraorbital approach and pterional approach in the surgical treatment of unruptured intracranial aneurysms. **J Korean Neurosurg Soc** 51 : 334-337, 2012
2. Kunert P, Przepiórka Ł, Fortuniak J, Wiśniewski K, Bobeff EJ, Larysz P, et al. : Prophylactic use of dural tenting sutures in elective craniotomies in adults-is it necessary? A study protocol for a multicentre, investigator- and participant-blinded randomised, parallel-group, non-inferiority trial. **Trials** 22 : 273, 2021
3. Park J : Self-drilling anchor screws for dural tenting sutures: technical note. **Surg Neurol** 72 : 175-176, 2009
4. Przepiórka Ł, Kunert P, Żyłkowski J, Fortuniak J, Larysz P, Szczepanek D, et al. : Necessity of dural tenting sutures in modern neurosurgery: protocol for a systematic review. **BMJ Open** 9 : e027904, 2019
5. Swayne OB, Horner BM, Dorward NL : The hitch stitch: an obsolete neurosurgical technique? **Br J Neurosurg** 16 : 541-544; discussion 544, 2002
6. Winston KR : Efficacy of dural tenting sutures. **J Neurosurg** 91 : 180-184, 1999