

# Intrawound Vancomycin Powder Application for Preventing Surgical Site Infection Following Cranioplasty

Seong Bin Youn,<sup>1</sup> Gyojun Hwang,<sup>1</sup> Hyun-Gon Kim,<sup>1</sup> Jae Seong Kang,<sup>1</sup> Hyung Cheol Kim,<sup>1</sup> Sung Han Oh,<sup>1</sup> Mi-Kyung Kim,<sup>2</sup> Bong Sub Chung,<sup>3</sup> Jong Kook Rhim,<sup>4</sup> Seung Hun Sheen<sup>5</sup>

*Department of Neurosurgery,<sup>1</sup> Bundang Jesaeng General Hospital, Daejin Medical Center, Seongnam, Korea*

*Department of Neurosurgery,<sup>2</sup> Myongji St Mary's Hospital, Seoul, Korea*

*Department of Neurosurgery,<sup>3</sup> Anyang Sam Hospital, Anyang, Korea*

*Department of Neurosurgery,<sup>4</sup> Jeju National University Hospital, Jeju, Korea*

*Department of Neurosurgery,<sup>5</sup> Bundang CHA Medical Center, CHA University, Seongnam, Korea*

**Objective :** Surgical site infection is the most detrimental complication following cranioplasty. In other surgical fields, intrawound vancomycin powder application has been introduced to prevent surgical site infection and is widely used based on results in multiple studies. This study evaluated the effect of intrawound vancomycin powder in cranioplasty compared with the conventional method without topical antibiotics.

**Methods :** This retrospective study included 580 patients with skull defects who underwent cranioplasty between August 1, 1998 and December 31, 2021. The conventional method was used in 475 (81.9%; conventional group) and vancomycin powder (1 g) was applied on the dura mater and bone flap in 105 patients (18.1%; vancomycin powder group). Surgical site infection was defined as infection of the incision, organ, or space that occurred after cranioplasty. Surgical site infection within 1-year surveillance period was compared between the conventional and vancomycin powder groups with logistic regression analysis. Penalized likelihood estimation method was used in logistic regression to deal with zero events. All local and systemic adverse events associated with topical vancomycin application were also evaluated.

**Results :** Surgical site infection occurred in 31 patients (5.3%) and all were observed in the conventional group. The median time between cranioplasty and detection of surgical site infection was 13 days (range, 4–333). Staphylococci were the most common organisms and identified in 25 (80.6%) of 31 cases with surgical site infections. The surgical site infection rate in the vancomycin powder group (0/105, 0.0%) was significantly lower than that in the conventional group (31/475, 6.5%; crude odds ratio [OR], 0.067; 95% confidence interval [CI], 0.006–0.762; adjusted OR, 0.068; 95% CI, 0.006–0.731;  $p=0.026$ ). No adverse events associated with intrawound vancomycin powder were observed during the follow-up.

**Conclusion :** Intrawound vancomycin powder effectively prevented surgical site infections following cranioplasty without local or systemic adverse events. Our results suggest that intrawound vancomycin powder is an effective and safe strategy for patients undergoing cranioplasty.

**Key Words :** Surgical wound infection · Vancomycin · Powders · Cranioplasty.

• Received : January 30, 2023 • Revised : March 31, 2023 • Accepted : April 4, 2023

• Address for correspondence : **Gyojun Hwang**

Department of Neurosurgery, Bundang Jesaeng General Hospital, Daejin Medical Center, 20 Seohyeon-ro 180beon-gil, Bundang-gu, Seongnam 13590, Korea  
Tel : +82-31-799-0280, Fax : +82-31-799-0929, E-mail : [hwang.gyojun.md@gmail.com](mailto:hwang.gyojun.md@gmail.com), ORCID : <https://orcid.org/0000-0002-7405-0487>

This is an Open Access article distributed under the terms of the Creative Commons Attribution Non-Commercial License (<http://creativecommons.org/licenses/by-nc/4.0>) which permits unrestricted non-commercial use, distribution, and reproduction in any medium, provided the original work is properly cited.

## INTRODUCTION

Cranioplasty is a surgical procedure for repairing a skull defect resulting from a previous operation or injury in order to protect the brain, improve cerebrospinal fluid dynamics, and provide a natural form of the skull. Nevertheless, cranioplasty can have serious complications, including intracranial hemorrhage, infection, seizures, bone resorption, wound dehiscence, and delayed hydrocephalus<sup>9,16,30</sup>. Among these complications, surgical site infection has the most detrimental effects on the brain. Although a simple scalp infection can be controlled with antibiotics, re-operation including bone flap removal is necessary when deep wound infection involving the bone flap or empyema in the epidural or subdural space occurs. Furthermore, long-term antibiotic therapy for surgical site infection can cause various medical complications. Recent studies showed that the surgical site infection rate was 3.7–26%<sup>14,15,19,26</sup> indicating that surgical site infection following cranioplasty is not infrequent.

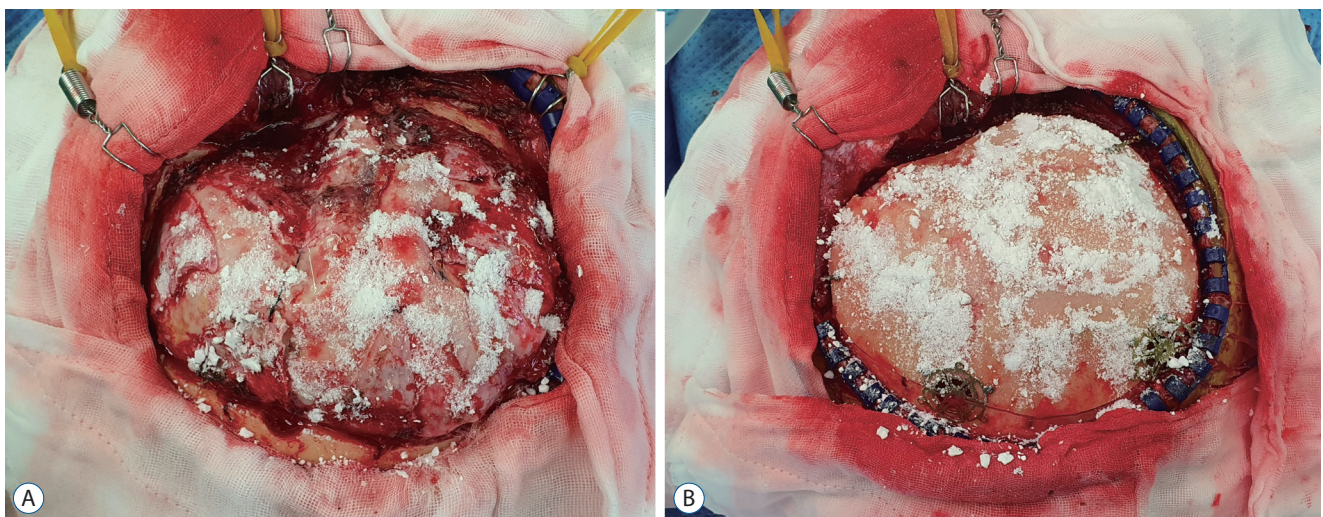
One of the ideas for decreasing surgical site infection is use of topical antibiotics to the surgical wound. The rationale of using intrawound antibiotics is to achieve a local high antibiotic concentration and a high bacterial killing rate, while minimizing systemic toxicity<sup>5</sup>. Given that the most common organisms associated with surgical site infections are gram-positive bacteria, intrawound vancomycin has been applied in various surgical procedures including cardiac, orthopedic,

and spine operations, and showed its effects and safety<sup>5,7,10,17,21,25,28</sup>. Based on this background, we have been using intrawound vancomycin powder in cranioplasty. The purpose of this study was to evaluate the effect of intrawound vancomycin powder application for preventing surgical site infection following cranioplasty compared with the conventional procedure without topical antibiotics.

## MATERIALS AND METHODS

This retrospective study was approved by the Institutional Review Board of Bundang Jesaeng General Hospital (DMC 2022-08-010). The requirement to obtain written informed consent to participate in this study was waived. All patients with skull defects who underwent cranioplasty in our institution between August 1, 1998 and December 31, 2021 were screened for eligibility. We excluded patients who 1) underwent craniectomy at other hospitals, 2) underwent craniectomy due to infectious conditions, or 3) were lost to regular follow-up after cranioplasty. According to inclusion and exclusion criteria, 595 patients were screened and 15 patients (three underwent craniectomy at other hospitals, two underwent craniectomy for infectious conditions, and 10 were lost to follow-up) were excluded. Finally, a total of 580 patients were included in this study.

Cranioplasty was performed by making an incision along the



**Fig. 1.** Intrawound vancomycin application. Vancomycin of 1 g is usually sufficient to cover the entire surface of the dura and bone flap. After dura defect repair, half of the vancomycin powder is applied on the dura (A). Bone flap is placed and then the remaining vancomycin powder is applied on the bone flap (B).

previous incision site. Any dura defect was repaired with dura substitutes and multiple sutures water-tightly. Autologous bone or alternative material such as polymethyl methacrylate or titanium was then used to cover the skull defect along the margin of the bone defect. A hemovac line was placed on the autologous bone or alternative materials, and the scalp flap was closed. When the skull defect was not large, a hemovac was not used according to the surgeon's decision. First-generation cephalosporin was administered intravenously for 7 days as a pro-

phylactic antibiotic. Other antibiotics for gram-positive organisms were used in patients showing adverse effects of cephalosporin. If other antibiotics were already being used for a concomitant infection and were effective against gram-positive bacteria, the antibiotics in use were continued. In the case of intrawound vancomycin, vancomycin powder was applied on the dura mater after dura repair. A bone flap was then placed, and the remaining vancomycin powder was applied on the bone flap (Fig. 1). Intrawound vancomycin powder was applied in

**Table 1.** Baseline characteristics of patients receiving cranioplasty using intrawound vancomycin powder and the conventional method without topical antibiotics

	Intrawound vancomycin powder (n=105)	Conventional method without topical antibiotics (n=475)	p-value
Male	57 (54.3)	272 (57.3)	0.588
Age (years)	53 (15)	52 (24)	0.001
Body mass index (kg/m <sup>2</sup> )	22.5 (3.4)	22.7 (4.2)	0.210
Hypertension	42 (40.0)	161 (33.9)	0.259
Diabetes mellitus	17 (16.2)	35 (7.4)	0.007
Smoking	24 (22.9)	168 (35.4)	0.016
Modified Rankin scale score			
0–2	13 (12.4)	86 (18.1)	0.130
3–4	40 (38.1)	201 (42.3)	
5	52 (49.5)	188 (39.6)	
Reason for initial craniectomy			
Trauma	34 (32.4)	163 (34.3)	0.272
Hemorrhage	54 (51.4)	252 (53.0)	
Tumor	4 (3.8)	27 (5.7)	
Infarction	13 (12.4)	33 (7.0)	
White blood cell (×10 <sup>3</sup> /μL)	8.4 (5.8)	8.3 (3.6)	0.311
C-reactive protein (mg/L)	0.9 (3.8)	0.4 (1.0)	<0.001
Interval from initial craniectomy to cranioplasty (days)	39 (51)	42 (36)	0.523
Operation time (minutes)	119 (49)	120 (65)	0.332
Materials used for cranioplasty			
Autologous bone	92 (87.6)	417 (87.8)	<0.001
Polymethyl methacrylate	4 (3.8)	54 (11.4)	
Titanium	9 (8.6)	4 (0.8)	
Post-cranioplasty antibiotics			
Cephalosporins	92 (87.6)	420 (88.4)	0.701
Penicillins	5 (4.8)	13 (2.7)	
Glycopeptides	4 (3.8)	18 (3.8)	
Other classes	4 (3.8)	24 (5.1)	

Values are presented as median (interquartile range, Q3 - Q1) or number (%)

105 patients (18.1%) and the conventional method without topical antibiotics was used in 475 patients (81.9%).

We collected demographic, clinical, laboratory, and procedural data of the patients. The clinical data included body mass index, medical history, history of smoking, neurological status before cranioplasty, the reason for the initial craniectomy, and post-cranioplasty antibiotics. The laboratory data included white blood cell count and C-reactive protein level before cranioplasty. The procedural data included the interval from the initial craniectomy to cranioplasty, operation time, and materials used for cranioplasty (autologous bone, polymethyl methacrylate, or titanium).

Surgical site infection was defined as infection of the incision, organ, or space that occurred after surgery, following the Centers for Disease Control and Prevention guidelines<sup>3,20</sup>. Craniotomy has a 90-day surveillance period for surgical site infection according to the guideline. However, because prosthetics were implanted in cranioplasty, the surveillance period in this study was extended to 1 year. As a safety parameter, all local and systemic adverse events associated with topical vancomycin application were evaluated.

The Mann-Whitney U test was used for continuous variables, and the chi-squared test or Fisher's exact test was used for nominal variables in comparisons of baseline characteristics. Outcomes were compared between patients receiving cranioplasty using intrawound vancomycin powder and the conventional method by logistic regression analysis. The comparison was adjusted for variables showing a baseline group difference with a  $p$ -value of  $<0.2$  and provided with an adjusted odds ratio (OR) and 95% confidence interval (CI). Penalized likelihood estimation method was used in logistic regression to deal with zero events. All statistical analyses were conducted using SAS Studio (version 3.8; SAS Institute Inc., Cary, NC, USA). Statistical significance was accepted at a  $p$ -value of  $<0.05$ .

## RESULTS

The baseline characteristics of patients using intrawound vancomycin powder and the conventional method are summarized in Table 1. The mean age ( $p=0.001$ ) of patients using intrawound vancomycin powder was higher than that of those using the conventional method. History of diabetes mellitus

( $p=0.007$ ), non-smokers ( $p=0.016$ ), and severe disability (modified Rankin scale score of 5,  $p=0.130$ ) were more frequent, and preoperative C-reactive protein levels ( $p<0.001$ ) were higher in patients using intrawound vancomycin powder. When choosing an artificial material for cranioplasty, titanium ( $p<0.001$ ) was more preferred in patients using intrawound vancomycin powder. These six variables were included as covariates in outcome comparison.

Surgical site infections following cranioplasty occurred in 31 patients (5.3%) (Table 2 and Supplementary Table 1). All were observed in patients who underwent cranioplasty using the conventional method. The median time between cranioplasty and the detection of surgical site infection was 13 days (range, 4–333). Staphylococci were the most common organisms. They were identified in 25 (80.6%) of 31 cases with surgical site infections. As a main treatment for surgical site infection, re-surgery was performed in 28 (90.3%; wound

**Table 2.** Summary of 31 patients with surgical site infections

Characteristics	Value
Cranioplasty method	
Intrawound vancomycin powder	0 (0.0)
Conventional method without topical antibiotics	31 (100.0)
Classification of surgical site infection	
Superficial	4 (12.9)
Deep	21 (67.7)
Organ/space	6 (19.4)
Reason for initial craniectomy	
Trauma	10 (32.3)
Hemorrhage	14 (45.2)
Tumor	5 (16.1)
Infarction	2 (6.4)
Organism	
Methicillin-resistant <i>Staphylococcus aureus</i>	22 (71.1)
Methicillin-resistant coagulase-negative <i>Staphylococcus</i>	2 (6.4)
Methicillin-sensitive <i>Staphylococcus aureus</i>	1 (3.2)
Multidrug-resistant <i>Acinetobacter baumannii</i>	1 (3.2)
No growth in culture study	5 (16.1)
Main treatment for surgical site infection	
Antibiotic therapy only	3 (9.7)
Wound revision and debridement of infected tissue	10 (32.2)
Wound revision and bone flap removal	18 (58.1)

Values are presented as number (%)



revision and only debridement of infected tissue in 10 [32.2%] and wound revision including bone flap removal in 18 [58.1%]) and antibiotic therapy only was used in the remaining three cases (9.7%). Six patients (19.4%) underwent re-cranioplasty after surgical site infection control. However, surgical site infection recurred, and the bone flap was eventually removed in four patients (12.9%). On final follow-up, 15 patients (48.4%) had skull defects and two patients (6.4%) died during treatment for surgical site infections.

In patients who underwent cranioplasty using intrawound vancomycin powder, no surgical site infection was detected during the 1-year surveillance period. Therefore, the surgical site infection rate in patients using intrawound vancomycin powder was significantly lower than that in patients using the conventional method (0/105 [0.0%] vs. 31/475 [6.5%]; crude OR, 0.067; 95% CI, 0.006–0.762). This difference was also found to be significant even when adjusted for age, diabetes mellitus, smoking, modified Rankin scale scores, preoperative C-reactive protein levels, and materials used for cranioplasty (adjusted OR, 0.068; 95% CI, 0.006–0.731;  $p=0.026$ ). No adverse events associated with intrawound vancomycin powder were observed during the follow-up.

## DISCUSSION

In this study, we found that surgical site infections were not infrequent in patients who underwent cranioplasty using the conventional method and application of vancomycin powder within the wound prevented surgical site infections following cranioplasty. The use of topical vancomycin did not yield any local or systemic adverse events which have been reported in other surgical fields.

Most patients with surgical site infections in this study underwent reoperation and received additional antibiotic therapy for a long time to control surgical site infections. Other studies reported that bone flap removal was required in 66–100% of patients with surgical site infections<sup>2,4,12,26</sup>. Similarly, we had to remove the bone flap in 18 (64.2%) of 28 patients who underwent re-surgery for surgical site infections. Thereafter, second cranioplasty was tried, but a considerable number of patients experienced surgical site infection recurrence and were eventually left with a skull defect. The application of vancomycin powder in the wound was a simple process during cra-

nioplasty and effectively prevented surgical site infections. Therefore, we recommend adding this simple process to cranioplasty procedure, based on the results of this study.

In a literature review, Staphylococci were found to be the most common causative organisms of surgical site infections, accounting for 48–70% of the isolated organisms<sup>1,19,23,27,29</sup>. Our study also showed that Staphylococci were isolated from most surgical site infections in culture studies. Additionally, 96% of the Staphylococci were found to be resistant to methicillin, which was consistent with the results of another study conducted in Korea<sup>13</sup>. Based on these findings, vancomycin can be the first-choice antibiotic if topical antibiotics are used in cranioplasty.

The patients in this study experienced no adverse events associated with the use of intrawound vancomycin, which is consistent with other published studies including cardiac and cranial surgeries<sup>7,22,24,25</sup>. However, several local (wound dehiscence, wound seroma, delayed wound healing, neuritis, and pseudoarthrosis) and systemic (anaphylactic reaction, renal toxicity, and ototoxicity) adverse events have been reported in spinal and orthopedic surgeries in which the effect and safety of intrawound vancomycin powder were most extensively evaluated<sup>15,6,8,11,18,21</sup>. Therefore, as recommended in these surgical fields, minimizing the amount of vancomycin powder and hemovac line placement for avoiding an over-concentration of vancomycin in the wound can be helpful for reducing adverse events. In our experience, 1 g of vancomycin powder was usually sufficient to cover the entire surface of the dura and bone flap before wound closure.

This study had several limitations. First, this was a retrospective cohort study. Thus, some confounding variables that could be associated with outcomes might have been missed and not included in the outcome comparison for effect adjustment. However, because the outcome difference between the two study groups is large, it is statistically impossible that our results are changed by effect of these missing variables. Second, the electrical medical record system in our institution has been changed several times. Therefore, some events, especially minor surgical site infections, could have been missed in the older medical records. Because cranioplasty was performed by the conventional method in all patients during the period in which older medical records were used, surgical site infections were more likely to have been missed in patients using the conventional method. Third, since the data used in

this study were based on multi-surgeons' experiences that differed in surgical techniques, this could have made a difference in the incidence of surgical site infections. Nevertheless, considering that the rate of surgical site infections decreased sharply after the application of intrawound vancomycin powder, we do not think that surgical techniques or experiences influenced key results of this study. Fourth, first-generation cephalosporin was administered intravenously for 7 days after cranioplasty. We disclose that this policy is not a general rule for surgical site infection prevention. Lastly, we used single-center data for this study. The environment which can affect surgical site infections is usually different in each hospital. Therefore, our results need to be confirmed with multi-center studies for generalization.

## CONCLUSION

We found that intrawound vancomycin powder prevented surgical site infections following cranioplasty which led to re-operation and long-term antibiotic therapy, without local or systemic adverse events. Our results suggest that intrawound vancomycin powder is an effective and safe strategy for patients undergoing cranioplasty.

## AUTHORS' DECLARATION

### Conflicts of interest

No potential conflict of interest relevant to this article was reported.

### Informed consent

This type of study does not require informed consent.

### Author contributions

Conceptualization : GH; Data curation : SBY, GH; Formal analysis : GH; Methodology : SBY, GH; Project administration : GH; Visualization : SBY, GH; Writing - original draft : SBY, GH; Writing - review & editing : SBY, GH, HGK, JSK, HCK, SHO, MKK, BSC, JKR, SHS

### Data sharing

None

### Preprint

None

### ORCID

Seong Bin Youn	<a href="https://orcid.org/0009-0009-4281-4348">https://orcid.org/0009-0009-4281-4348</a>
Gyojun Hwang	<a href="https://orcid.org/0000-0002-7405-0487">https://orcid.org/0000-0002-7405-0487</a>
Hyun-Gon Kim	<a href="https://orcid.org/0000-0002-8439-1306">https://orcid.org/0000-0002-8439-1306</a>
Jae Seong Kang	<a href="https://orcid.org/0009-0003-7026-4546">https://orcid.org/0009-0003-7026-4546</a>
Hyung Cheol Kim	<a href="https://orcid.org/0000-0001-7147-9176">https://orcid.org/0000-0001-7147-9176</a>
Sung Han Oh	<a href="https://orcid.org/0000-0001-9037-7386">https://orcid.org/0000-0001-9037-7386</a>
Mi-Kyung Kim	<a href="https://orcid.org/0000-0002-8824-0505">https://orcid.org/0000-0002-8824-0505</a>
Bong Sub Chung	<a href="https://orcid.org/0009-0002-4419-9472">https://orcid.org/0009-0002-4419-9472</a>
Jong Kook Rhim	<a href="https://orcid.org/0000-0003-2538-8374">https://orcid.org/0000-0003-2538-8374</a>
Seung Hun Sheen	<a href="https://orcid.org/0000-0002-0454-8810">https://orcid.org/0000-0002-0454-8810</a>

### • Supplementary materials

The online-only data supplement is available with this article at <https://doi.org/10.3340/jkns.2023.0024>.

## References

1. Abode-Iyamah KO, Chiang HY, Winslow N, Park B, Zanaty M, Dlouhy BJ, et al. : Risk factors for surgical site infections and assessment of vancomycin powder as a preventive measure in patients undergoing first-time cranioplasty. *J Neurosurg* **128** : 1241-1249, 2018
2. Bader ER, Kobets AJ, Ammar A, Goodrich JT : Factors predicting complications following cranioplasty. *J Craniomaxillofac Surg* **50** : 134-139, 2022
3. Berrios-Torres SI, Umscheid CA, Bratzler DW, Leas B, Stone EC, Kelz RR, et al. : Centers for Disease Control and Prevention guideline for the prevention of surgical site infection, 2017. *JAMA Surg* **152** : 784-791, 2017
4. Coulter IC, Pesic-Smith JD, Cato-Addison WB, Khan SA, Thompson D, Jenkins AJ, et al. : Routine but risky: a multi-centre analysis of the outcomes of cranioplasty in the Northeast of England. *Acta Neurochir (Wien)* **156** : 1361-1368, 2014
5. Devin CJ, Chotai S, McGirt MJ, Vaccaro AR, Youssef JA, Orndorff DG, et al. : Intrawound vancomycin decreases the risk of surgical site infection after posterior spine surgery: a multicenter analysis. *Spine (Phila Pa 1976)* **43** : 65-71, 2018
6. Dial BL, Lampley AJ, Green CL, Hallows R : Intrawound vancomycin powder in primary total hip arthroplasty increases rate of sterile wound complications. *Hip Pelvis* **30** : 37-44, 2018

7. Donovan TJ, Sino S, Paraforos A, Leick J, Friedrich I : Topical vancomycin reduces the incidence of deep sternal wound complications after sternotomy. **Ann Thorac Surg** 114 : 511-518, 2022
8. Ghobrial GM, Cadotte DW, Williams K Jr, Fehlings MG, Harrop JS : Complications from the use of intrawound vancomycin in lumbar spinal surgery: a systematic review. **Neurosurg Focus** 39 : E11, 2015
9. Goedemans T, Verbaan D, van der Veer O, Bot M, Post R, Hoogmoed J, et al. : Complications in cranioplasty after decompressive craniectomy: timing of the intervention. **J Neurol** 267 : 1312-1320, 2020
10. Haimoto S, Schär RT, Nishimura Y, Hara M, Wakabayashi T, Ginsberg HJ : Reduction in surgical site infection with suprafascial intrawound application of vancomycin powder in instrumented posterior spinal fusion: a retrospective case-control study. **J Neurosurg Spine** 29 : 193-198, 2018
11. Hanada M, Nishikino S, Hotta K, Furuhashi H, Hoshino H, Matsuyama Y : Intrawound vancomycin powder increases post-operative wound complications and does not decrease periprosthetic joint infection in primary total and unicompartmental knee arthroplasties. **Knee Surg Sports Traumatol Arthrosc** 27 : 2322-2327, 2019
12. Honeybul S, Ho KM : Cranioplasty: morbidity and failure. **Br J Neurosurg** 30 : 523-528, 2016
13. Im SH, Jang DK, Han YM, Kim JT, Chung DS, Park YS : Long-term incidence and predicting factors of cranioplasty infection after decompressive craniectomy. **J Korean Neurosurg Soc** 52 : 396-403, 2012
14. Jeong TS, Yee GT : Prospective multicenter surveillance study of surgical site infection after intracranial procedures in Korea : a preliminary study. **J Korean Neurosurg Soc** 61 : 645-652, 2018
15. Kim JS, Park IS, Kim SK, Park H, Kang DH, Lee CH, et al. : Analysis of the risk factors affecting the surgical site infection after cranioplasty following decompressive craniectomy. **Korean J Neurotrauma** 11 : 100-105, 2015
16. Kim YM, Park T, Lee SP, Baek JW, Ryou KS, Kim SH : Optimal timing and complications of cranioplasty: a single-center retrospective review of 109 cases. **J Neurointensive Care** 3 : 48-57, 2020
17. Major Extremity Trauma Research Consortium (METRC); O'Toole RV, Joshi M, Carlini AR, Murray CK, Allen LE, et al. : Effect of intrawound vancomycin powder in operatively treated high-risk tibia fractures: a randomized clinical trial. **JAMA Surg** 156 : e207259, 2021
18. Molinari RW, Khera OA, Molinari WJ 3rd : Prophylactic intraoperative powdered vancomycin and postoperative deep spinal wound infection: 1,512 consecutive surgical cases over a 6-year period. **Eur Spine J** 21 Suppl 4 : S476-S482, 2012
19. Morton RP, Abecassis JJ, Hanson JF, Barber J, Nerva JD, Emerson SN, et al. : Predictors of infection after 754 cranioplasty operations and the value of intraoperative cultures for cryopreserved bone flaps. **J Neurosurg** 125 : 766-770, 2016
20. National Healthcare Safety Network, Center for Disease Control and Prevention : **Surgical Site Infection (SSI) Event**. Available at : <https://www.cdc.gov/nhsn/pdfs/pscreportmanual/9pscscscurrent.pdf>
21. Patel NN, Guild GN 3rd, Kumar AR : Intrawound vancomycin in primary hip and knee arthroplasty: a safe and cost-effective means to decrease early periprosthetic joint infection. **Arthroplast Today** 4 : 479-483, 2018
22. Ravikumar V, Ho AL, Pendhakar AV, Sussman ES, Kwong-Hon Chow K, Li G : The use of vancomycin powder for surgical prophylaxis following craniotomy. **Neurosurgery** 80 : 754-758, 2017
23. Riordan MA, Simpson VM, Hall WA : Analysis of factors contributing to infections after cranioplasty: a single-institution retrospective chart review. **World Neurosurg** 87 : 207-213, 2016
24. Saleh A, Thabet A, Belkhair S : Topical vancomycin for prevention of surgical site infection after craniotomy: meta-analysis and systematic literature review. **World Neurosurg** 158 : e605-e611, 2022
25. Shah SJ, Jadhav UE : Efficacy of topical vancomycin application in cardiac surgery to reduce deep sternal wound infection: a randomised control trial at tertiary cardiac care hospital. **Int Surg J** 9 : 601-605, 2022
26. Shibahashi K, Hoda H, Takasu Y, Hanakawa K, Ide T, Hamabe Y : Cranioplasty outcomes and analysis of the factors influencing surgical site infection: a retrospective review of more than 10 years of institutional experience. **World Neurosurg** 101 : 20-25, 2017
27. Sundseth J, Sundseth A, Berg-Johnsen J, Sorteberg W, Lindegaard KF : Cranioplasty with autologous cryopreserved bone after decompressive craniectomy: complications and risk factors for developing surgical site infection. **Acta Neurochir (Wien)** 156 : 805-811; discussion 811, 2014
28. Ushirozako H, Hasegawa T, Yamato Y, Yoshida G, Yasuda T, Banno T, et al. : Impact of intrawound vancomycin powder on prevention of surgical site infection after posterior spinal surgery. **J Neurosurg Spine** 34 : 656-664, 2021
29. Zanaty M, Chalouhi N, Starke RM, Chitale R, Hann S, Bovenzi CD, et al. : Predictors of infections following cranioplasty: a retrospective review of a large single center study. **ScientificWorldJournal** 2014 : 356042, 2014
30. Zanaty M, Chalouhi N, Starke RM, Clark SW, Bovenzi CD, Saigh M, et al. : Complications following cranioplasty: incidence and predictors in 348 cases. **J Neurosurg** 123 : 182-188, 2015