

Right-to-Left Displacement of an Airgun Lead Bullet after Transorbital Entry into the Skull Complicated by Posttraumatic Epilepsy : A Case Report

Chao-bin Wang,^{1,2} Hui Wang,² Jun-shuang Zhao,² Ze-jun Wu,^{1,2} Hao-dong Liu,² Chao-jia Wang,² An-rong Li,² Dawei Wang,³ Juntao Hu²

Department of Neurosurgery,¹ Taihe Hospital, Jinzhou Medical University Union Training Base, Shiyan, China

Department of Neurosurgery,² Taihe Hospital, Hubei University of Medicine, Shiyan, China

Department of Ultrasonography,³ Taihe Hospital, Hubei University of Medicine, Shiyan, China

Penetrating head injury is a serious open cranial injury. In civilians, it is often caused by non-missile, low velocity flying objects that penetrate the skull through a weak cranial structure, forming intracranial foreign bodies. The intracranial foreign body can be displaced due to its special quality, shape, and location. In this paper, we report a rare case of right-to-left displacement of an airgun lead bullet after transorbital entry into the skull complicated by posttraumatic epilepsy, as a reminder to colleagues that intracranial metal foreign bodies maybe displaced intraoperatively. In addition, we have found that the presence of intracranial metallic foreign bodies may be a factor for the posttraumatic epilepsy, and their timely removal appears to be beneficial for epilepsy control.

Key Words : Penetrating head injury · Foreign body migration · Posttraumatic epilepsy.

INTRODUCTION

Penetrating head injuries (PHI) account for approximately 0.4% of all traumatic brain injuries (TBI)³⁾. In civilians, it is often caused by non-missile type, low velocity flying objects such as projectiles, wood, debris, or skull fragments, entering the cranial cavity through anatomically weak areas such as the external auditory canal or orbit¹⁾. In China, non-missile PHI is mostly caused by air guns, which have slow velocity and low kinetic energy, and the injuries are mostly blind tube injuries, often forming intracranial foreign bodies. There are few re-

ports of displacement of intracranial metallic foreign bodies complicated by posttraumatic epilepsy (PTE). In this paper, we report a case of right-to-left displacement of an airgun lead bullet after transorbital entry into the skull complicated by PTE. The patient in this case underwent two surgeries within 2 years : the first surgery mainly removed the broken bone fragments in the brain, but the lead bullet foreign body was not found due to its intraoperative displacement from the right hemisphere to the left. One year later, the patient was re-admitted due to PTE seizures frequently and strongly requested to remove the intracranial lead bullet foreign body. There-

• Received : November 3, 2022 • Revised : February 3, 2023 • Accepted : February 8, 2023

• Address for correspondence : Juntao Hu

Department of Neurosurgery, Taihe Hospital, Hubei University of Medicine, No. 32 Renmin South Road, Shiyan, Hubei Province 442000, China
Tel : +86-07198801712, Fax : +86-07198883809, E-mail : 29872780@qq.com, ORCID : <https://orcid.org/0000-0001-5595-7801>

This is an Open Access article distributed under the terms of the Creative Commons Attribution Non-Commercial License (<http://creativecommons.org/licenses/by-nc/4.0>) which permits unrestricted non-commercial use, distribution, and reproduction in any medium, provided the original work is properly cited.

for we operated the second surgery, during which the foreign body was successfully removed and the epilepsy was effectively controlled.

CASE REPORT

On March 18, 2020, a 40-year-old male was accidentally shot by an airgun lead bullet through the left eyeball into his skull, resulting in the lead bullet retained in his brain.

On March 19, 2020, he presented to the emergency depart-

ment, where the physician performed computed tomography (CT) scan of the head and found a foreign body retained in the frontal horn of the right lateral ventricle (Fig. 1A-D), then he was admitted to the neurosurgery department. He was admitted with a clear consciousness, stable vital signs, a Glasgow coma scale (GCS) score of 14 and a previously healthy body. He underwent an operation to remove the intracranial foreign body on the same day after completing the preoperative examination.

Some of the bony foreign bodies were removed during the operation, but the lead bullet foreign body was not successful-

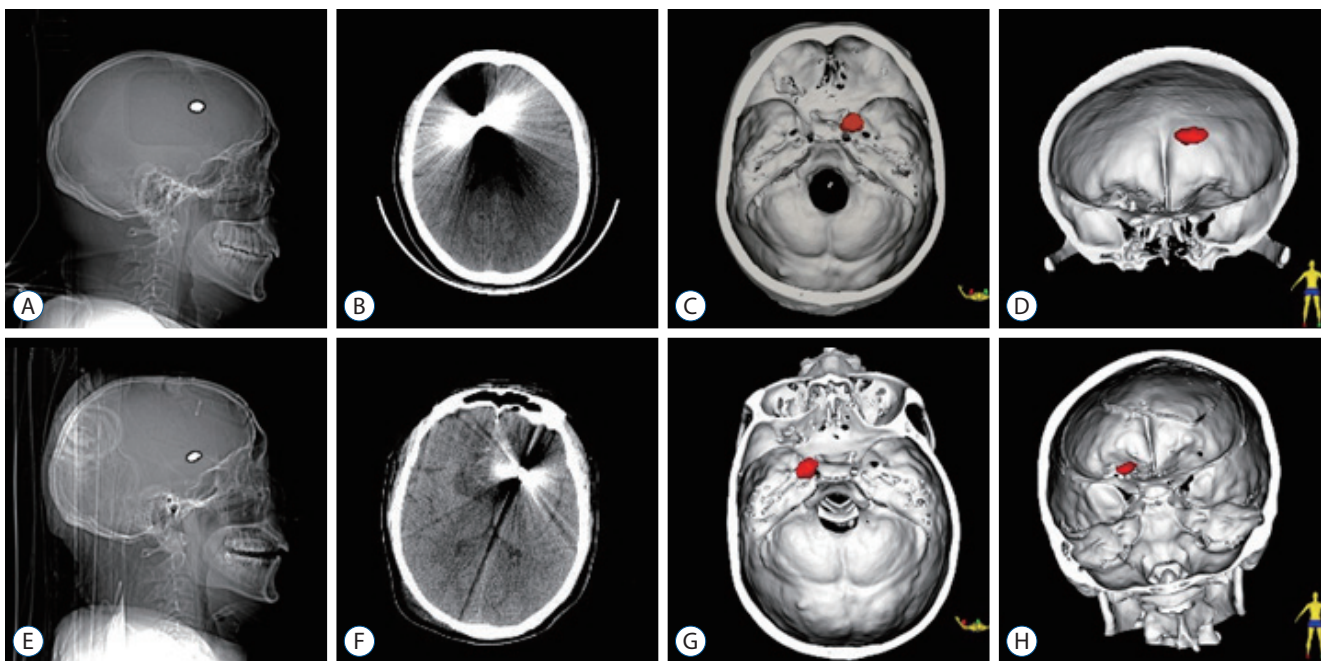


Fig. 1. Location of the intracranial foreign body before and after the first surgery. A-D : Preoperative. E-H : Postoperative. The red dots in (C, D, G, and H) indicate the intracranial foreign body which is reconstructed in 3D.

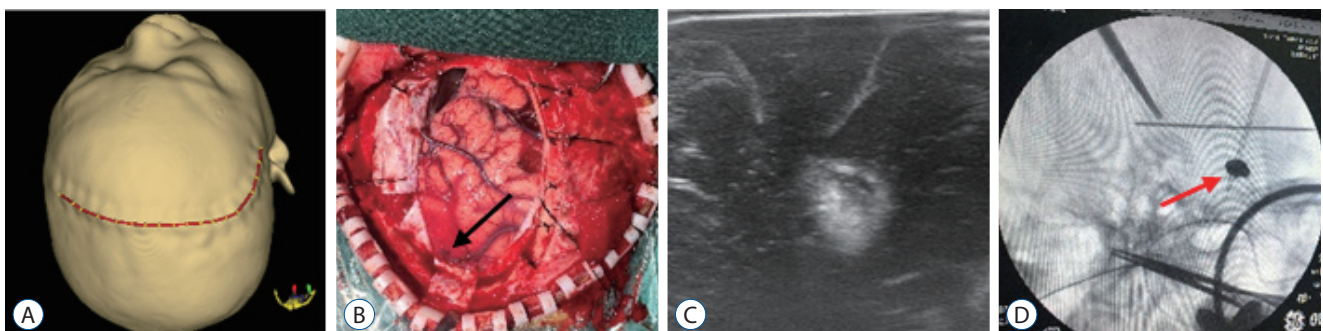


Fig. 2. The first surgical procedure. A : The skin incision design. B : The arrow in the middle indicates a brain surface wound. C : Intraoperative ultrasound, the highlighted area in the center of the figure is a foreign body shadow, which cannot be located. D : Intraoperative X-ray, the red arrow indicates a foreign body, which cannot be located despite the use of surgical instruments.

ly found due to intracranial displacement. We inability to locate it accurately by intraoperative X-ray and ultrasound (Fig. 2). The postoperative cranial CT showed that the foreign body was moved from the preoperative right lateral ventricular frontal horn to the left lateral ventricular frontal horn (Fig. 1E-H). We decided to treat with him conservatively and not do the second craniotomy for the patient after communicated with his relatives.

During hospitalization, we performed regular lumbar punctures to extract cerebrospinal fluid for bacterial culture, which showed no bacterial growth. After 1 month of hospitalization, he was discharged on April 18, 2020 with well-wound healing, blindness in the left eye and no other abnormal symptoms. He was seizure-free during hospitalization and continued out-of-hospital medication to prevent seizure.

After discharge from hospital, he was followed up by regular outpatient visits and telephone calls. He had several seizures separately at 4, 8, 11, and 12 months after the operation. One year later, the seizures occurred monthly with no apparent pattern and lasted from a few seconds to a few minutes separately. The sodium valproate couldn't control his seizures.

So, he visited the neurology clinic to adjust the treatment prescription to a combination of sodium valproate and levetiracetam, which reduced his seizures.

On December 20, 2021, he had a serious seizure. So, he re-admitted to the hospital on December 27, 2021, with a strong desire to remove the intracranial foreign body. The intracranial foreign body was successfully removed on December 29, 2021 (Fig. 3). The sodium valproate was applied intravenously but one seizure occurred during hospitalization. We completed the electroencephalography (EEG) for him, but we did not detect typical epileptic waves. He was discharged from hospital on January 14, 2022. Sodium valproate was administered out of hospital to prevent seizure. He had no seizures after followed up 8 months.

DISCUSSION

The airgun is the most common factor to PHI among civilians. The mechanism of injury from airguns is primarily derived from the kinetic energy of the pellet⁷. Due to the low ki-

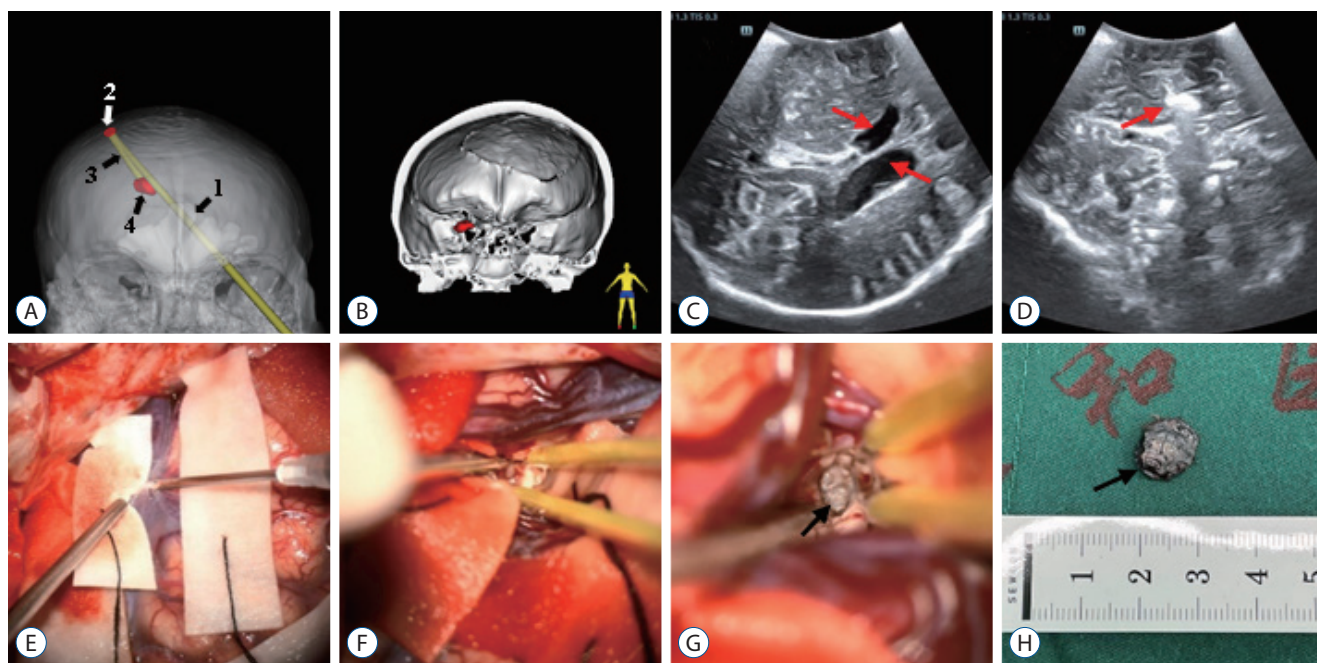


Fig. 3. A : Foreign body trajectory diagram. 1 to 4 in the diagram respectively indicate foreign body trajectory into the skull, foreign body and skull collision reflex point, rebound trajectory and foreign body stay location. B : Location of the intracranial foreign body (red dot) before the second operation, with a slight downward shift compared to the first operation. C and D : The second intraoperative ultrasound for clear visualization of intracerebral structures, the red arrows in (C) indicate the lateral ventricles and the arrow in (D) indicates the foreign body. E-H : The second operation to remove the foreign body, the arrows in (G) and (H) indicate the foreign body.

netic energy, the airgun pellets generally remain in brain tissue after they penetrate the skull, then damage the brain tissue and blood vessels in the trajectory of the pellet^{21,24}.

In this case, based on the patient's injury, the first preoperative imaging data and intraoperative observations, the ballistics of the intracranial projectile in this patient were analyzed as follows: the airgun lead bullet was shot from the left eyeball, penetrated the orbital wall, slightly changed its trajectory direction, passed obliquely upward through the left frontal lobe of the brain, penetrated the falx cerebri, entered the right side of the brain, then rebounded to the frontal corner of the right lateral ventricle after colliding with the right parietal bone (Fig. 3A).

Imaging

CT scan is the first choice of imaging. This noninvasive examination method not only allows rapid assessment of lesion extent, missile trajectory, shrapnel residue, size of the hematoma, and type of cranial injury but also helps us to assess patient prognosis and provides visual imaging guidance for surgical planning^{4,14-16,22}. However, metal artifacts in CT scans from intracranial foreign bodies may mask some of the injuries. Magnetic resonance imaging (MRI) is superior to CT in many fields. However, the pellets of airgun are mostly metallic, so MRI is not selected because it may lead the metal fragments to move⁴. The position, shape and number of foreign bodies such as metals can be easily obtained in the sagittal position with intraoperative X-ray, but it is difficult to obtain the position in the coronal and axial positions^{2,17}. Transcranial sonography (TCS) was usually used in TBI because it's noninvasive, convenient, and efficient¹⁹. Intraoperative TCS can clearly show the midline structures, ventricular system and other important structures in the brain (Fig. 3C). TCS can display the size, shape, depth, surrounding brain tissue structure and echogenic characteristics of the foreign body in real time intraoperatively (Fig. 3D). This is a unique advantage over the metal artifacts of CT and the movement of metallic foreign bodies of MRI. However, it is not easy to observe the foreign body by TCS when the foreign body is deep, when the foreign body has an obvious acoustic shadow, or when the foreign body is obscured by the skull.

In this case, the CT played an important role, as it directly clarified the displacement of the lead bullet and the location of the intracranial foreign body after the first operation. The us-

ing of X-rays only showed us a two-dimensional plane of information during the first operation. That made us difficult to locate the foreign body accurately. The use of intraoperative TCS can be helpful in the localization of foreign bodies sometimes.

Displacement of the intracranial foreign body

Displacement of the intracranial foreign body is a rare phenomenon¹⁴. The displacement is related to the qualities of the foreign body itself (e.g., mass, shape, surface, etc.) and the initial intracranial location (e.g., the foreign body is not easily displaced when proximity to bone, blood vessels, meninges, etc.)^{6,25}. There is still considerable controversy regarding the management of intracranial foreign bodies. Some scholars believe that the metallic foreign bodies can't to remove when they are located in deep vital structures, with small in size or has life-threatening by operation. However, for lead bullets and cranial fragment bodies, they should be removed completely because of their increased toxicity and chance of infection compared with other foreign bodies²³. In addition, intracranial shrapnel or projectiles >5 mm in diameter need to be completely removed because they are prone to foreign body displacement and can cause local brain tissue hyperplasia inducing epilepsy or toxic effects on brain tissue (especially lead and aluminum bullets)¹². However, Karadas et al.⁹ suggested that in cases without complications, where the foreign body is located deep and difficult to remove by surgery, the operation is not necessary and regular follow-up is sufficient.

However, intraoperative management of intracranial foreign body displacement has not been reported. There are no uniform criteria about the time to remove intracranial metallic foreign bodies. If the displacement of the intracranial foreign body occurs within a few hours of trauma, it is difficult to successfully remove it through surgery. For this reason, some investigators have suggested that intracranial foreign bodies should be accurately localized and removed 2 to 3 weeks after the injury. When they are easier to be removed as they are held in place by proliferating fibrous connective tissue or encapsulated by fibrous tissue¹³. However, intraoperative management of intracranial foreign body displacement has not been reported.

In this case, the intracranial metallic foreign body was easily displaced because of its large mass, spherical shape and smooth surface. We therefore suggest that intracranial dis-

placement should be considered if the foreign body is difficult to locate during the operation, especially in the early stages of trauma. It is particularly important to identify the location of the foreign body at this time. When the location of the foreign body is not clearly identifiable during the surgery, blind exploration is avoided in order to reduce the trauma associated with surgery. The CT scan should be done to locate the foreign body. When the intracranial foreign body is confirmed to be displaced, symptomatic treatment such as anti-infection can be administered first, and then the patient can be considered for surgical removal depending on his condition after the foreign body has been immobilized by localized hyperplastic brain tissue.

PTE

PTE is an important complication affecting the quality of life of patients and can be divided into early (≥ 7 days) and late (> 7 days) epilepsy. The incidence of PTE is 3.8% to 4.2% in all types of TBI¹⁰⁾. There is no direct evidence as to whether PHI in combination with intracranial foreign bodies increases the incidence of PTE. Based on this case, we consider that the presence of an intracranial metallic foreign body may precipitate seizures. Because this patient had frequent seizures after the first surgery, this may have been due to the trauma itself or the retention of the intracranial metallic foreign body. In contrast, the patient's seizures were effectively controlled after the second successful surgery to remove the intracranial metal foreign body.

The pathogenesis of PTE is unclear. Aarabi et al.¹⁾ suggested by multivariate regression analysis that GCS scores and motor deficits are associated with the development of epilepsy. Recent studies have concluded that excitotoxicity, neuroinflammation, oxidative stress, and neurodegeneration are the main causative factors in PTE¹⁸⁾. Towner et al.²⁰⁾ reported that the retention of lead bullets in the body resulted in a sustained increase in lead levels and toxic effects, and that the lead levels decreased rapidly after surgical removal of the lead bullets and the symptoms were effectively relieved. In this case, the patient had a GCS score of 14 and no motor deficits, so it was considered that seizures might be related to the type of foreign body. In other words, the intracranial metallic foreign body may increase the probability of PTE, which may be related to the slow release of metallic toxic ions from metallic substances acting on local brain tissue and causing abnormal local electrical activity.

There are no clear protocols on how to effectively prevent PTE. But there is clinical practice recommend the administration of drugs such as phenytoin sodium and carbamazepine to control epilepsy within 1 week after injury¹⁸⁾. Although there is evidence that the use of these prophylactic antiepileptic drugs may reduce early seizures, there is no evidence of benefit for late epilepsy⁵⁾. For those with severe seizures, anti-epileptic drug therapy is preferred, but the surgery can be tried after evaluation of the condition for those with well-localized and limited seizure foci¹⁸⁾.

In late epilepsy patients with intracranial retention of for-

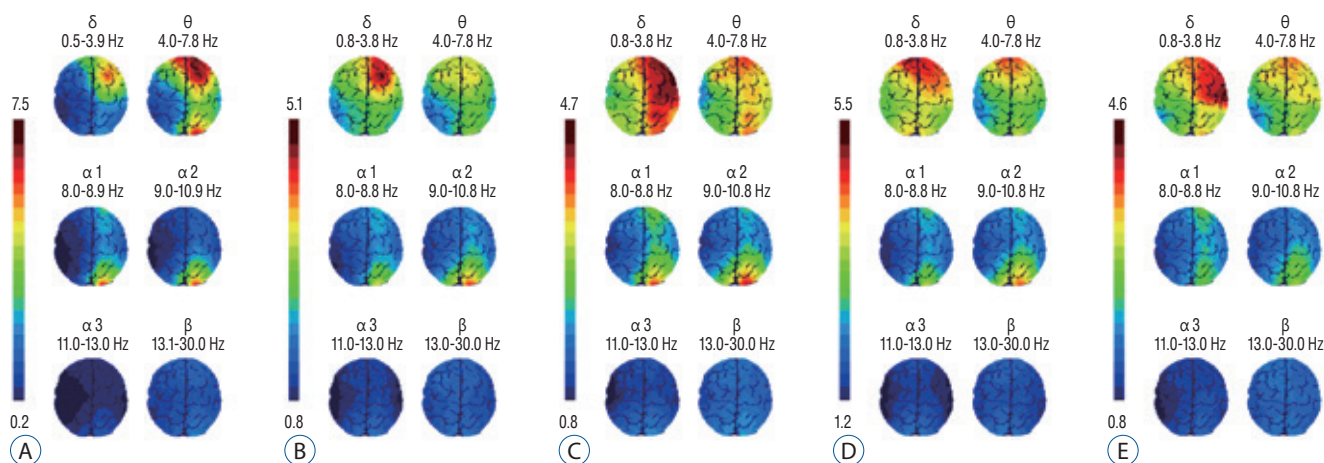


Fig. 4. EEG topography. (A-E) are respectively EEG topography at 1 month, 1 year after the first operation, 1 day before reoperation, 1 day after reoperation for seizures, and 2 months after reoperation. EEG : electroencephalography. In these figures, there has been abnormal electrical activity in the right cerebral hemisphere, which may be the location of the seizure foci.

foreign bodies, it has not been investigated whether removal of the foreign body can improve epileptic symptoms. In this case, the patient applied sodium valproate for seizure prevention during the first hospitalization and did not experience seizures, which supports the effectiveness of early antiepileptic drug application. However, the patient had several seizures during the follow-up period, and after adjusting the medication prescription, seizures continued and was more serious than before. Therefore we decided to have a surgery for the patient again, and the intracranial foreign body was successfully removed. The patient underwent seizures at the fourteenth day after the reoperation, which may be related to the trauma of the reoperation. But we did not find typical seizure waves after monitoring the EEG. However, based on EEG topographic (Fig. 4) changes since the patient's injury, we hypothesized that the patient may have a confined epileptic lesion in the right frontal lobe of the brain, but this epileptic lesion did not correspond to the location where the foreign body was located after its displacement. However, after removal of the intracranial foreign body, the patient's seizures were significantly relieved compared with before (continued follow-up for 8 months without seizures). Therefore, we conjecture that the removal of the intracranial metallic foreign body may contribute to the control of PTE by reducing the release of toxins from the metallic foreign body.

In addition, the reduction of psychological stress after the intracranial foreign body was removed from the patient in this case may have contributed to the control of PTE also. As some studies have concluded that psychological stress is an important trigger and sometimes the cause of seizures⁸⁾. However, the relationship between changes in psychological factors and the progression of PTE still needs to be confirmed by further clinical studies.

CONCLUSION

PHI caused by airgun pellets often forms intracranial foreign bodies, and such intracranial foreign bodies can shift in position during early surgery because of their mass, shape and surface smoothness. Therefore, if a foreign body is difficult to be found during the surgery, it may be displaced, and it is particularly important to accurately its location at this time. If it is hard to locate the foreign bodies during the operation, the

surgery should be stopped and have the CT scan to certain the location. If the foreign body is confirmed to be displaced, symptomatic treatment, such as anti-infection, can be administered firstly. The surgery can be considered for the patient to remove the foreign body after it has been fixed by the around brain tissue. If an intracranial foreign body is present in the patient, especially a metallic foreign body, complicated with PTE, it may be facilitated to control the PTE by removing the metallic foreign body. Those may due to reduce the release of toxins from the metallic foreign body and reduce the patient's psychological stress.

AUTHORS' DECLARATION

Conflicts of interest

No potential conflict of interest relevant to this article was reported.

Informed consent

Informed consent was obtained from the patient.

Author contributions

Conceptualization : HW, JH; Data curation : CW, JZ, ZW, HL; Formal analysis : JH, CW, AL; Funding acquisition : JH; Methodology : JH, HW, CW; Project administration : JH, HW; Visualization : CW, DW, JH; Writing - original draft : CW; Writing - review & editing : JH, CW

Data sharing

None

Preprint

None

ORCID

Chao-bin Wang	https://orcid.org/0000-0003-2630-8006
Hui Wang	https://orcid.org/0000-0001-9627-4484
Jun-shuang Zhao	https://orcid.org/0000-0003-3511-1635
Ze-jun Wu	https://orcid.org/0000-0003-4129-0449
Hao-dong Liu	https://orcid.org/0000-0001-5854-7963
Chao-jia Wang	https://orcid.org/0000-0002-3183-250X

An-rong Li <https://orcid.org/0000-0003-2073-811X>
 Dawei Wang <https://orcid.org/0000-0003-0791-0798>
 Juntao Hu <https://orcid.org/0000-0001-5595-7801>

References

1. Aarabi B, Taghipour M, Haghnegahdar A, Farokhi M, Mobley L : Prognostic factors in the occurrence of posttraumatic epilepsy after penetrating head injury suffered during military service. **Neurosurg Focus** 8 : e1, 2000
2. Bilotta F, Rosa G, Delfini R, Pinto R, Fiorani B : Unrecognized periorbital penetrating nail in the brain: case report. **Am J Emerg Med** 25 : 198-199, 2007
3. Borkar SA, Garg K, Garg M, Sharma BS : Transorbital penetrating cerebral injury caused by a wooden stick: surgical nuances for removal of a foreign body lodged in cavernous sinus. **Childs Nerv Syst** 30 : 1441-1444, 2014
4. Buttram SD, Garcia-Filion P, Miller J, Youssfi M, Brown SD, Dalton HJ, et al. : Computed tomography vs magnetic resonance imaging for identifying acute lesions in pediatric traumatic brain injury. **Hosp Pediatr** 5 : 79-84, 2015
5. Carney N, Totten AM, O'Reilly C, Ullman JS, Hawryluk GW, Bell MJ, et al. : Guidelines for the management of severe traumatic brain injury, fourth edition. **Neurosurgery** 80 : 6-15, 2017
6. Darwazeh R, Darwazeh M, Sun X : Spontaneous migration of retained intracranial missiles: experience with 16 cases. **Neurosurg Rev** 45 : 2417-2430, 2022
7. DiGiulio GA, Kulick RM, Garcia VF : Penetrating abdominal air gun injuries: pitfalls in recognition and management. **Ann Emerg Med** 26 : 224-228, 1995
8. Galtrey CM, Mula M, Cock HR : Stress and epilepsy: fact or fiction, and what can we do about it? **Pract Neurol** 16 : 270-278, 2016
9. Karadas S, Dursun R, Kiyamaz N : Treatment of intracranial foreign body. **J Pak Med Assoc** 64 : 828-829, 2014
10. Karlander M, Ljungqvist J, Zelano J : Post-traumatic epilepsy in adults: a nationwide register-based study. **J Neurol Neurosurg Psychiatry** 92 : 617-621, 2021
11. Kazanci A, Ozdemir HI, Kazanci B, Kazanci DO, Er U : Intracranial sewing needles in an adult patient. **Turk Neurosurg** 22 : 775-776, 2012
12. Lei P, Ong CD, Wang Y, Zhou J, Zhi ZY : Characteristics and management of gunshot wounds and nonpowder gunshot wounds to the head in civilian practice. **J Trauma Surg** 12 : 484-486, 2010
13. Lei P, Zhang Y, Wu G, Zhi ZY : Removal of retained intracranial projectile shrapnel in 24 cases. **Chin J Traumatol** 16 : 576, 2000
14. Lolli V, Pezzullo M, Delpierre I, Sadeghi N : MDCT imaging of traumatic brain injury. **Br J Radiol** 89 : 20150849, 2016
15. Morton MJ, Korley FK : Head computed tomography use in the emergency department for mild traumatic brain injury: integrating evidence into practice for the resident physician. **Ann Emerg Med** 60 : 361-367, 2012
16. Muehlschlegel S, Ayturk D, Ahlawat A, Izzy S, Scalea TM, Stein DM, et al. : Predicting survival after acute civilian penetrating brain injuries: the SPIN score. **Neurology** 87 : 2244-2253, 2016
17. Rahimizadeh A : Intracranial migration of a broken rod after orbitocranial injury in an adult. **World Neurosurg** 121 : 232-238, 2019
18. Sharma S, Tiarks G, Haight J, Bassuk AG : Neuropathophysiological mechanisms and treatment strategies for post-traumatic epilepsy. **Front Mol Neurosci** 14 : 612073, 2021
19. Thelin EP, Nelson DW, Vehviläinen J, Nyström H, Kivisaari R, Siironen J, et al. : Evaluation of novel computerized tomography scoring systems in human traumatic brain injury: an observational, multicenter study. **PLoS Med** 14 : e1002368, 2017
20. Towner JE, Pieters TA, Maurer PK : Lead toxicity from intradiscal retained bullet fragment: management considerations and recommendations. **World Neurosurg** 141 : 377-382, 2020
21. Tsranchev I, Timonov P, Alexandrov A : Penetrating brain trauma due to air gun shot - a case report. **Folia Med (Plovdiv)** 63 : 977-980, 2021
22. Vakil MT, Singh AK : A review of penetrating brain trauma: epidemiology, pathophysiology, imaging assessment, complications, and treatment. **Emerg Radiol** 24 : 301-309, 2017
23. Wei LF, Wang SS, Jing JJ, Zheng ZC, Gao JX, Liu Z, et al. : Surgical therapy for craniocerebral firearm injury. **Turk Neurosurg** 23 : 491-497, 2013
24. Wightman G, Beard J, Allison R : An investigation into the behaviour of air rifle pellets in ballistic gel and their interaction with bone. **Forensic Sci Int** 200 : 41-49, 2010
25. Yue JK, Chang D, Han KJ, Wang AS, Oh T, Sun PP : Management of migrating intracranial bullet fragments in a 13-year-old female after firearm brain injury: technical and surgical nuances. **Brain Inj** 36 : 432-439, 2022