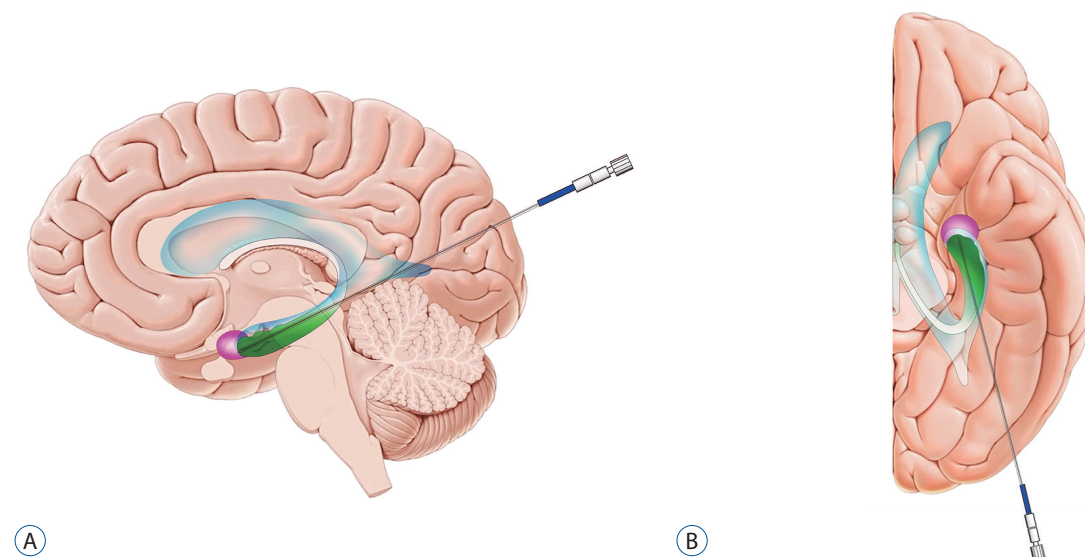


# Erratum to “A Primer on Magnetic Resonance-Guided Laser Interstitial Thermal Therapy for Medically Refractory Epilepsy” by Lee EJ, et al. (J Korean Neurosurg Soc 62 : 353-360, 2019)

<https://doi.org/10.3340/jkns.2019.0105>

In this article by Lee EJ et al., it was reported that the legend for Fig. 2 was incomplete. The complete figure legend is:



**Fig. 2.** Schematic depicting the target and the trajectory of laser probe for magnetic resonance-guided laser interstitial thermal therapy in patients with mesial temporal lobe epilepsy. Note the anatomical relationships between the ventricle (blue), hippocampus (green), and amygdala (pink). A : Sagittal view. B : Axial view. The reference of the background brain images is © Kenhub ([www.kenhub.com](http://www.kenhub.com)); Illustrator: Paul Kim.