

CASE REPORT

성인에서 간혈관종에 의해 발생한 카사바-메리트 증후군

옥찬영*, 전충환*, 조은애, 이두현, 조성범, 박창환, 주영은, 김현수, 류종선, 최성규

전남대학교 의과대학 내과학교실 소화기내과

Hepatic Hemangioma with Kasabach-Merritt Syndrome in an Adult Patient

Chan Young Oak*, Chung Hwan Jun*, Eun Ae Cho, Du Hyun Lee, Sung Bum Cho, Chang Hwan Park, Young Eun Joo, Hyun Soo Kim, Jong Sun Rew, and Sung Kyu Choi

Department of Internal Medicine, Chonnam National University Medical School, Gwangju, Korea

Hemangiomas are the most common benign tumors of the liver. They are generally asymptomatic, but giant hemangiomas can lead to abdominal discomfort, bleeding, or obstructive symptoms. Kasabach-Merritt syndrome is a rare but life-threatening complication of hemangioma, characterized by consumptive coagulopathy with large vascular tumors. More than 80% of Kasabach-Merritt syndrome cases occur within the first year of life. However, there are few reports of Kasabach-Merritt syndrome with giant hepatic hemangioma in adults and, as far as we know, no reports of Kasabach-Merritt syndrome with hepatic hemangioma treated with first line medical treatment only. The most important treatment for this syndrome is removal of the large vascular tumor. However, surgical treatment entails risk of bleeding, and the patient's condition can mitigate against surgery. We herein present a case of unresectable giant hepatic hemangioma with disseminated intravascular coagulopathy. The patient was a 60-year-old woman who complained of hematochezia, ecchymosis, and abdominal distension. She refused all surgical management and was therefore treated with systemic glucocorticoids and beta-blockers. After two weeks of steroid therapy, she responded partially to the treatment. Her laboratory findings and hematochezia improved. She was discharged on hospital day 33 and observed without signs of bleeding for three months. (*Korean J Gastroenterol* 2016;67:220-223)

Key Words: Kasabach-Merritt syndrome; Hemangioma; Disseminated intravascular coagulation

INTRODUCTION

Hepatic hemangiomas are one of the most common hepatic tumors. The prevalence of hepatic hemangiomas ranges from 0.4% to 20% and are diagnosed via on imaging studies or autopsies.^{1,2} Most hepatic hemangiomas are small and do not produce any symptoms. However, hemangiomas larger than 4 cm are defined as giant hemangiomas,³ and they are more symptomatic. The most common symptoms are ab-

dominal pain and right upper quadrant discomfort. Consumption coagulopathy is rare but can occur as a symptom of hemangioma, and this phenomenon is known as Kasabach-Merritt syndrome (KMS). KMS is characterized by a large vascular anomaly and consumption coagulopathy with thrombocytopenia, prothrombin time and partial thromboplastin time prolongation, hypo-fibrinogenemia, and production of D-dimer and fibrin split product, with or without micro-angiopathic hemolytic anemia.⁴ KMS, first reported by Kasabach and

Received November 18, 2015. Revised January 14, 2016. Accepted January 15, 2016.

© This is an open access article distributed under the terms of the Creative Commons Attribution Non-Commercial License (<http://creativecommons.org/licenses/by-nc/4.0>) which permits unrestricted non-commercial use, distribution, and reproduction in any medium, provided the original work is properly cited.

Copyright © 2016. Korean Society of Gastroenterology.

교신저자: 최성규, 61469, 광주시 동구 제봉로 42, 전남대학교병원 소화기내과

Correspondence to: Sung Kyu Choi, Division of Gastroenterology, Department of Internal Medicine, Chonnam National University Hospital, 42 Jebong-ro, Dong-gu, Gwangju 61469, Korea. Tel: +82-62-220-6296, Fax: +82-62-225-8578, E-mail: choisk@jnu.ac.kr

*These two authors have equally contributed to this work.

Financial support: None. Conflict of interest: None.

Merritt⁵ in 1940, is a rare, potentially life-threatening condition most often occurring in infants. The vascular tumors can manifest on the extremities, trunk, face, or retroperitoneal organs. Although some argue that this syndrome is only associated with tufted angioma and Kaposi-form hemangio-endotheliomas (KHE), an aggressive form of hemangioma, and not true common hemangiomas,⁶ previous cases of consumption coagulopathy with giant hepatic hemangioma in adults have been reported as KMS.⁷⁻¹¹ However, as far as we know, there have been no reports of KMS with hepatic hemangioma treated with first line medical treatment only.

We herein report our experience of KMS with giant hemangioma in an adult who was treated with steroid therapy and beta-blockers. The patient visited our institution because of hematochezia and bleeding tendency. Clinical symptoms and coagulation profile improved with medical treatments alone.

CASE REPORT

A 60-year-old woman presented to the emergency department with hematochezia. She was admitted to another hospital when this symptom developed two weeks previously. Her medical history included a skull cavernous hemangioma, resected 10 years previously, and a huge hepatic hemangioma detected eight years previously. For the resolution of her epigastric discomfort and pain, surgical resection was considered, but at that time the surgeon recommended liver transplantation because of technical problems related to its large size (it occupied most of the right hepatic lobe). However, her disseminated intravascular coagulopathy profile was within the normal range at that time, and she refused surgery. She then was not seen for five years.

On admission, physical examination showed a distended right upper quadrant with a hard palpable mass, and generalized ecchymosis was observed on the trunk and extremities (Fig. 1). Fresh bloody stool was noted on digital rectal exam. On laboratory testing, her hemoglobin level was 8.2 g/dL, and platelet count was 32,000/mm³. Prothrombin time was prolonged to 28.0 sec, and prolonged activated partial thromboplastin time revealed no coagulation (normal range, 26.5-41.0 sec). Fibrinogen was lower than 50 mg/dL (normal range, 180-350 mg/dL), and D-dimer and fibrinogen degradation products (FDP) were elevated at 31.58 mg/L (normal

range 0-0.55 mg/L fibrinogen equivalent units [FEU]) and 115.2 µg/mL (normal range, 0-5 µg/mL), respectively. Peripheral blood smear showed pancytopenia with anisopoikilocytosis, and schistocytes were not found. Direct and indirect Coombs' tests were negative. Liver function tests and renal function tests were within normal range. There was no evidence of infection. These results were compatible with consumption coagulopathy, and other hematologic diseases, such as hemolytic anemia, hemolytic uremic syndrome, and systemic inflammatory response syndrome, could be excluded. Abdominal computed tomography showed an exophytic hemangioma measuring 32.3×27.5×25.4 cm (Fig. 2A, B), increased over the abdominal computed tomography of eight years prior (Fig. 2C). Sigmoidoscopy showed diffuse mucosal bleeding, but an active bleeding focus was not found. Despite packed red blood cell concentrate and platelet concentrate, fresh frozen plasma, and cryoprecipitate transfusions, bleeding tendency and coagulation profiles were not corrected completely (Table 1). We recommended liver transplantation for removal of the giant hepatic hemangioma. However, the patient and her family refused any surgical management. Therefore, we decided to start medical treatment with steroid therapy and a beta-blocker.

Prednisone at a dose of 3 mg/kg/day (total dose, 125 mg) and 20 mg of propranolol twice a day were administered for 14 days, followed by a tapering dose. The frequency and amount of hematochezia decreased by the fourth day of ste-

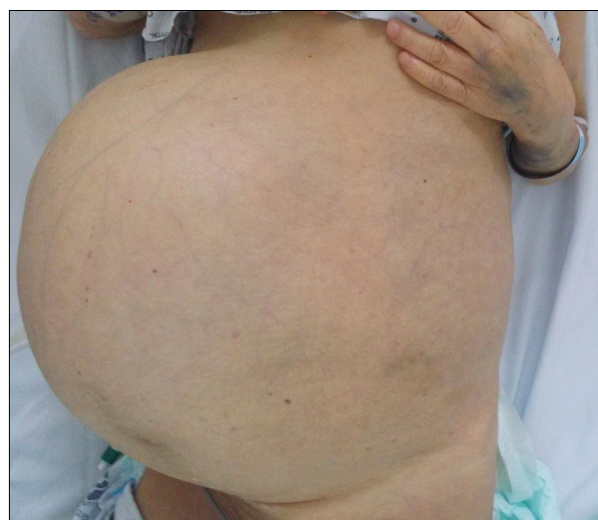


Fig. 1. Physical examination at admission showed distended abdomen and extremity ecchymosis.

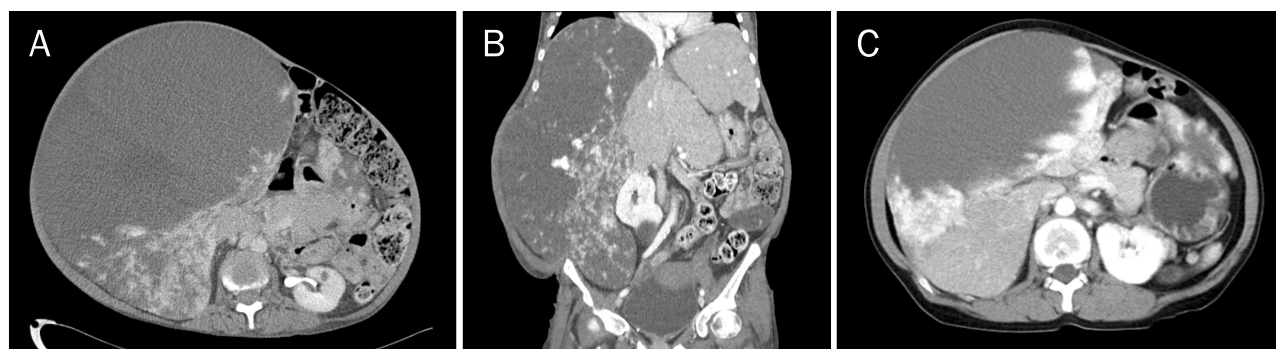

Fig. 2. Abdominal CT scan at presentation with several centripetal enhancing exophytic masses in both hepatic lobes (maximum size, 32.3×27.5×25.4 cm). (A) Cross section image. (B) Coronal section image. (C) Cross section image of abdominal CT 8 years prior (maximal size, 22.3 cm).

Table 1. Complete Blood Count and Coagulation Profile during Hospital Stay

	HD 1 ^a	HD 3 ^a	HD 5 ^a (steroid+1)	HD 10 ^a (steroid+6)	HD 16 (steroid+12)	HD 23 (steroid+19)	HD 29 (steroid+25)
Hemoglobin (g/dL)	8.2	7.5	9.1	8.8	9.0	7.9	8.4
Platelet (/mm ³)	32,000	29,000	36,000	39,000	40,000	54,000	92,000
PT (sec)	28.0	15.7	16.9	> 100	18.0	14.2	13.1
aPTT (sec)	> 100	51.6	41.8	> 100	39.8	37.4	40.0
Fibrinogen (mg/dL)	< 50	59.1	46.2	< 50	< 50	60	109.1
FDP (μg/mL)	115.2	184.3			268.6	241.7	137.0

HD, hospital day; FDP, fibrinogen degradation products.

^aFresh frozen plasma, cryoprecipitate transfusion (HD 1-HD 10).

roid therapy. Coagulation time stabilized on the twelfth day without transfusion. Fibrinogen and fibrin split product levels were not normalized completely despite steroid therapy, but the fibrinogen level slightly increased to 60 mg/dL, and the FDP and D-dimer levels decreased to 241.7 μg/mL and 35.2 mg/L FEU, respectively, at the 19th day without transfusion. The platelet count improved at the 29th day to 96,000/mm³. We concluded that these laboratory findings were appropriate for partial response and decided to continue steroid therapy. Although partial response was observed, complete correction of laboratory results was not expected due to the residual hepatic lesion in this patient. We considered combination therapy with vincristine, interferon therapy, or radiation therapy as second line treatment due to her slow response, but the patient and her family refused further treatment. As the laboratory findings had stabilized, she was discharged on hospital day 33 on 30 mg/day of oral prednisolone. Three months later, the patient is still alive. She has been admitted to hospital care, and did not attend our hospital, but her local laboratory results showed no aggravation of coagulopathy.

DISCUSSION

KMS is a rare, life-threatening thrombocytopenic coagulopathy associated with a large vascular lesion, with significant morbidity and mortality (up to 30%).¹² This syndrome is characterized by thrombocytopenia, hypo-fibrinogenemia, and elevated fibrin split products.¹³ The pathogenesis is triggered by sequestration of platelets and clotting factors in abnormal endothelium within the vascular lesion.⁴ KHE and tufted angioma are the most common vascular lesions with coagulopathy, but these vascular tumors arise in early infancy and are rare in adults.

With this rare disorder, there is no consensus for treatment in adults. Most research of KMS are of infants and children. Protocols for infants are composed of supportive therapy to correct coagulopathy and curative therapy to treat the underlying causes. Fresh frozen plasma and cryoprecipitate can be used to replace clotting factors. However, platelet transfusion can result in rapid expansion of the hemangioma and probably cause intra-lesional clotting.¹⁴ Therefore, platelet transfusion should be reserved for active bleeding or in prep-

aration for a surgical procedure.

The first line medical treatment for KMS is corticosteroids.⁴ Although the mechanisms are not clear, steroids increase vasoconstriction, inhibit fibrinolysis, increase platelet lifespan, and interrupt angiogenesis. Starting steroid doses are 2-3 mg/kg/day in most centers, and response is within days. However, the response rates are variable, and about 30% of patients will not respond to corticosteroids alone.⁴ Interferon alpha (IFN- α) has been used with steroids or alone. IFN- α has anti-proliferative and anti-angiogenic effects and its efficacy is estimated at 50-60%.⁴ Vincristine has been used as a second line medical therapy because of its efficacy and good tolerance.¹⁵ Vincristine inhibits tumor growth by apoptosis of endothelial cells and anti-angiogenesis. However, the optimal dose and duration of therapy have not been identified. Non-selective beta-blockers were first used in 2008 as a new therapeutic approach. Beta-blockers increase vasoconstriction, downregulation of angiogenic factors, and upregulation of apoptosis of endothelial cells.¹⁶ Definitive treatment of KMS is removal of the vascular tumor. Trans-arterial embolization,⁹ radiation therapy,¹¹ surgical resection,⁷ and liver transplantation⁸ are potential therapeutic interventions for KMS if the vascular tumor is a hepatic hemangioma.

The patient in our case recovered from KMS with steroids and a beta-blocker only. There are a few reports of KMS with hepatic hemangioma in adults, which were treated with tumoral ablation with surgery, radiation, and radiologic intervention.⁷⁻¹¹ As far as we know, there have been no reports of KMS with hepatic hemangioma treated with first line medical treatment only. Although our patient did not undergo surgical therapy or second line therapy, her hematochezia and coagulation profile did improve. However, complete recovery was not expected, and the possibility of recurrence without complete regression of the vascular tumor should be considered.

KMS with hepatic hemangioma in adults is rare, considering the high prevalence of hepatic hemangiomas. A diagnosis of KMS should be considered for patients with hemangioma who complain of symptoms such as bleeding tendency, and who have a giant hepatic hemangioma (ranging from 7 to 25 cm) or multiple giant hemangiomas found on imaging studies.⁷⁻¹¹

Therefore, it is important to consider the possibility of KMS

in patients with giant hemangiomas and bleeding tendency. We should check the complete blood cell count and coagulation profiles to exclude KMS in these patients. However, a large study will be needed to confirm these findings.

REFERENCES

1. Ishak KG, Rabin L. Benign tumors of the liver. *Med Clin North Am* 1975;59:995-1013.
2. Choi BY, Nguyen MH. The diagnosis and management of benign hepatic tumors. *J Clin Gastroenterol* 2005;39:401-412.
3. Adam YG, Huvos AG, Fortner JG. Giant hemangiomas of the liver. *Ann Surg* 1970;172:239-245.
4. Hall GW. Kasabach-Merritt syndrome: pathogenesis and management. *Br J Haematol* 2001;112:851-862.
5. Kasabach HH, Merritt KK. Capillary hemangioma with extensive purpura. *Am J Dis* 1940;59:1063-1070.
6. Enjolras O, Wassef M, Mazoyer E, et al. Infants with Kasabach-Merritt syndrome do not have "true" hemangiomas. *J Pediatr* 1997;130:631-640.
7. Hochwald SN, Blumgart LH. Giant hepatic hemangioma with Kasabach-Merritt syndrome: is the appropriate treatment enucleation or liver transplantation? *HPB Surg* 2000;11:413-419.
8. Meguro M, Soejima Y, Taketomi A, et al. Living donor liver transplantation in a patient with giant hepatic hemangioma complicated by Kasabach-Merritt syndrome: report of a case. *Surg Today* 2008;38:463-468.
9. Malagari K, Alexopoulou E, Dourakis S, et al. Transarterial embolization of giant liver hemangiomas associated with Kasabach-Merritt syndrome: a case report. *Acta Radiol* 2007;48:608-612.
10. Aslan A, Meyer Zu Vilsendorf A, Kleine M, Bredt M, Bektas H. Adult Kasabach-merritt syndrome due to hepatic giant hemangioma. *Case Rep Gastroenterol* 2009;3:306-312.
11. McKay MJ, Carr PJ, Langlands AO. Treatment of hepatic cavernous haemangioma with radiation therapy: case report and literature review. *Aust N Z J Surg* 1989;59:965-968.
12. el-Dessouky M, Azmy AF, Raine PA, Young DG. Kasabach-Merritt syndrome. *J Pediatr Surg* 1988;23:109-111.
13. Kelly M. Kasabach-Merritt phenomenon. *Pediatr Clin North Am* 2010;57:1085-1089.
14. Seo SK, Suh JC, Na GY, Kim IS, Sohn KR. Kasabach-Merritt syndrome: identification of platelet trapping in a tufted angioma by immunohistochemistry technique using monoclonal antibody to CD61. *Pediatr Dermatol* 1999;16:392-394.
15. Gidding CE, Kellie SJ, Kamps WA, de Graaf SS. Vincristine revisited. *Crit Rev Oncol Hematol* 1999;29:267-287.
16. Léauté-Labrèze C, Dumas de la Roque E, Hubiche T, Boralevi F, Thambo JB, Taïeb A. Propranolol for severe hemangiomas of infancy. *N Engl J Med* 2008;358:2649-2651.