

CASE REPORT

## 대장 혈관이형성증에 대한 아르곤 플라즈마 응고 소작술 이후 생긴 자발성 세균성 복막염 1예

정혜진, 류수형, 박경식, 윤원재, 김진남, 김유선, 문정섭

인제대학교 의과대학 서울백병원 내과학교실

### A Case of Spontaneous Bacterial Peritonitis Following Argon Plasma Coagulation for Angiodysplasias in the Colon

Hye Jin Jung, Soo Hyung Ryu, Kyoung Sik Park, Won Jae Yoon, Jin Nam Kim, You Sun Kim and Jeong Seop Moon

Department of Internal Medicine, Seoul Paik Hospital, Inje University College of Medicine, Seoul, Korea

Spontaneous bacterial peritonitis (SBP) is the most common infection in liver cirrhosis patients, and is not a result of surgery or intra abdominal infection. Argon plasma coagulation (APC) is an endoscopic procedure used with a high-frequency electrical current for control of bleeding from gastrointestinal vascular ectasias including angiodysplasia and gastric antral vascular ectasia. This procedure is known to be safe because it uses a noncontact method. Therefore, tissue injury is minimal and up to two to three millimeters. However, we experienced a case of SBP occurring immediately after performance of APC for control of severe bleeding from angiodysplasia in the colon in a patient with liver cirrhosis and hepatocellular carcinoma. (**Korean J Gastroenterol 2014;64:115-118**)

**Key Words:** Peritonitis; Argon plasma coagulation; Angiodysplasia; Liver cirrhosis

#### INTRODUCTION

Spontaneous bacterial peritonitis (SBP) is a serious major complication of liver cirrhosis.<sup>1</sup> Even harmless procedures such as nasogastric tube placement, endoscopy, and intravenous catheter insertion may cause temporary bacteremia and SBP. Argon plasma coagulation (APC) is a non-contact endoscopic electrocoagulation method used for hemostasis or tissue ablation in the upper and lower gastrointestinal tract. This procedure is known to be relatively safe due to only a few minor complications such as gas bloating and transient abdominal or anal pain after the procedure. However, serious complications, including bowel perforation, rectovaginal fis-

tula, and stricture have been rarely reported.<sup>2-5</sup> To the best of our knowledge, no case of SBP occurring immediately after APC without evidence of bowel perforation in a cirrhotic patient has been reported. Herein, we report on a case of SBP that occurred after APC in a 71-year-old female with liver cirrhosis and hepatocellular carcinoma (HCC).

#### CASE REPORT

A 71-year-old female was admitted to the emergency department with melena that had started one week prior to hospitalization. She had a history of hepatitis C virus-associated liver cirrhosis and HCC. She was hospitalized with

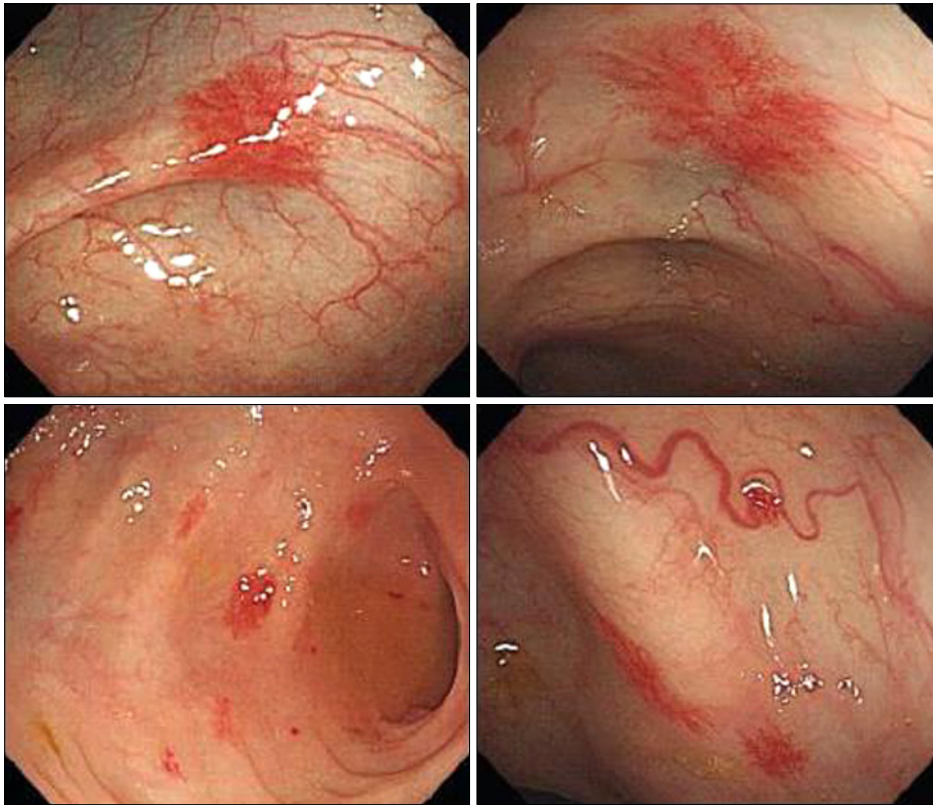
Received November 16, 2013. Revised January 20, 2014. Accepted January 21, 2014.

© This is an open access article distributed under the terms of the Creative Commons Attribution Non-Commercial License (<http://creativecommons.org/licenses/by-nc/3.0>) which permits unrestricted non-commercial use, distribution, and reproduction in any medium, provided the original work is properly cited.

교신저자: 류수형, 100-032, 서울시 중구 마른대로 9, 인제대학교 서울백병원 내과

Correspondence to: Soo Hyung Ryu, Department of Internal Medicine, Inje University Seoul Paik Hospital, 9 Mareunnae-ro, Jung-gu, Seoul 100-032, Korea. Tel: +82-2-2270-0012, Fax: +82-2-2279-4021, E-mail: rshdrryu@medimail.co.kr

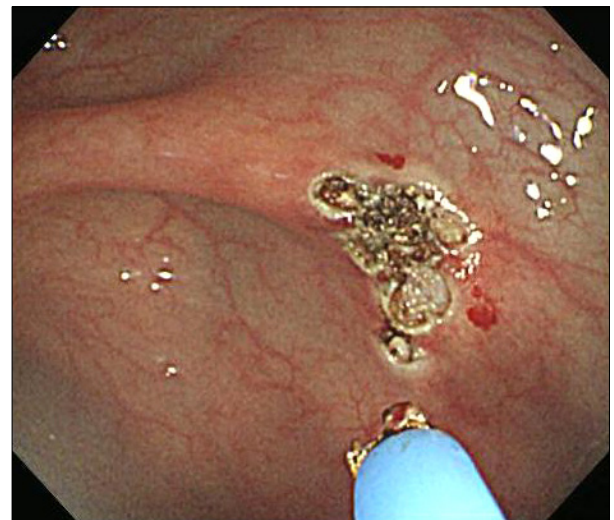
Financial support: None. Conflict of interest: None.



**Fig. 1.** Colonoscopy findings show many small vascular malformations (angiodysplasias) over the entire colon.

blood pressure of 100/70 mmHg, body temperature of 37.2°C, heart rate of 84 beats per minute, and respiratory rate of 20 breaths per minute. Physical examination showed a clear breathing sound on both lung fields and a regular heart beat without any murmur. The abdomen was distended with a moderate amount of ascites, but she did not have abdominal pain. Laboratory data showed a white blood cell count of 4,940/mm<sup>3</sup>, hematocrit of 19.3%, hemoglobin of 6.1 g/dL, platelet count of 157,000/mm<sup>3</sup>, glucose of 117 mg/dL, AST of 51 IU/L, ALT of 29 IU/L, total bilirubin of 0.8 mg/dL, albumin of 3.1 g/dL, blood urea nitrogen 40 mg/dL, creatinine concentration of 1.19 mg/dL, and prothrombin time of 18.2 seconds (52%). She was classified as Child-Turcotte-Pugh class B.

Esophagogastroduodenoscopy (EGD) showed grade II esophageal varices without evidence of bleeding. Colonoscopy showed angiodysplasias scattered over the entire colon with no obvious bleeding (Fig. 1). She had already visited the emergency department several times before this hospitalization with melena and all medical evaluations had shown the same results. We could not treat all angiodysplasias with alcohol injection therapy or hemoclips. Therefore, we only treated the prominent angiodysplasia



**Fig. 2.** Argon plasma coagulation applied on the prominent angiodysplasia suspected to cause bleeding.

which showed the largest size and was suspected to cause bleeding with endoscopic APC (Fig. 2). After the APC procedure, no complication such as bleeding or perforation was observed. After 5 hours of APC, the patient suffered from a stomach ache and experienced a fever of 38.5°C. Physical examination revealed tenderness and rebound tenderness on

the whole abdomen, and distention of the abdomen had deteriorated. Diagnostic paracentesis was performed for analysis of ascitic fluid. Results showed 5,590/mm<sup>3</sup> white blood cell count, 5,031/mm<sup>3</sup> polymorphonuclear leukocytes (90% of white blood cell count) and gram-negative rods, and cultures showed growth of *Escherichia coli*. Therefore, she was diagnosed as SBP and intravenous third generation cephalosporin was administered immediately.

On the 15th day of antibiotic treatment, follow-up ascitic fluid analysis showed 1/mm<sup>3</sup> polymorphonuclear leukocytes, and cultures showed no growth of micro-organisms. She made a full recovery with stable vital signs and normal laboratory findings.

## DISCUSSION

To the best of our knowledge, this is the first report on a patient with SBP as a complication of cirrhotic ascites after APC for multiple angiodysplasias, which provoked serious melena in the colon. SBP, a bacterial infection of ascitic fluid, is diagnosed by analysis of ascitic fluid. Liver cirrhosis has been known to increase risk for bacterial infection including SBP.<sup>6</sup> The incidence accounted for 10-30 percent of hospitalized patients of cirrhosis who have ascites.<sup>7</sup> The one-year mortality rate for patients who suffer from SBP is 30-50 percent.<sup>8</sup> *Escherichia coli*, *Klebsiella pneumonia*, and *Aeromonas* are the most commonly isolated organisms.<sup>9-12</sup> SBP is now easily treated with third generation cephalosporin and quinolone. Prophylactic antibiotics are recommended for patients who have upper gastrointestinal bleeding.<sup>13</sup>

APC is a non-contact electrocoagulation and controls hemorrhaging of the gastrointestinal tract during performance of EGD or colonoscopy.<sup>14</sup> It uses an ionized argon gas with a high voltage discharge. The procedure is considered effective and safe, because the depth of coagulation is just two to three millimeters. Minor complications like transient pain can occur following APC, but major complications such as perforation and intestinal emphysema are rare.<sup>2-5</sup> However, in the current case, it was suspected that the translocation of intestinal flora into ascites through the weakened bowel wall after APC caused SBP in a cirrhotic patient. According to another report, SBP occurred during bowel preparation for colonoscopy because gut bacteria passed through the intestinal wall and into the portal circulation.<sup>15</sup> There was one report of

the occurrence of peritonitis following argon plasma coagulation of colonic angiodysplasia in a continuous ambulatory peritoneal dialysis (CAPD) patient.<sup>16</sup> The patient on CAPD presented with recurrent massive bleeding from angiodysplasia of the cecum and developed peritonitis caused by *E. coli* within 24 hours after hemostasis with APC. In another case, an advanced cirrhosis patient who showed colonic ulcerations suggestive of Crohn's disease had peritonitis during colonoscopy without obvious perforation.<sup>17</sup> However, no cases of APC causing systemic infection such as bacteremia and SBP in cirrhosis patients have been reported. The pathophysiology of APC-induced SBP is unclear. APC is a non-invasive and safe procedure. However, APC may cause translocation of bacteria from the gut to the ascites, and development of SBP and bacteremia. In addition, due to their immunocompromised status, there is an increased risk of infection in liver cirrhosis patients.<sup>18</sup> Therefore, physicians should consider that prophylactic antibiotics must be administered before the APC procedure in cirrhotic patients with ascites. We report on a case of immediate occurrence of SBP after APC treatment for control of severe melena in a patient with cirrhotic ascites.

## REFERENCES

1. Ginés P, Rimola A, Planas R, et al. Norfloxacin prevents spontaneous bacterial peritonitis recurrence in cirrhosis: results of a double-blind, placebo-controlled trial. *Hepatology* 1990;12: 716-724.
2. Silva RA, Correia AJ, Dias LM, Viana HL, Viana RL. Argon plasma coagulation therapy for hemorrhagic radiation proctosigmoiditis. *Gastrointest Endosc* 1999;50:221-224.
3. Taïeb S, Rolachon A, Cenni JC, et al. Effective use of argon plasma coagulation in the treatment of severe radiation proctitis. *Dis Colon Rectum* 2001;44:1766-1771.
4. Grund KE, Storek D, Farin G. Endoscopic argon plasma coagulation (APC) first clinical experiences in flexible endoscopy. *Endosc Surg Allied Technol* 1994;2:42-46.
5. Ben Soussan E, Mathieu N, Roque I, Antonietti M. Bowel explosion with colonic perforation during argon plasma coagulation for hemorrhagic radiation-induced proctitis. *Gastrointest Endosc* 2003;57:412-413.
6. Fernández J, Navasa M, Gómez J, et al. Bacterial infections in cirrhosis: epidemiological changes with invasive procedures and norfloxacin prophylaxis. *Hepatology* 2002;35:140-148.
7. Suzuki K, Takikawa Y. Marked improvement in the resolution of, and survival rates in, spontaneous bacterial peritonitis. *J Gastroenterol* 2002;37:149-150.
8. Garcia-Tsao G. Identifying new risk factors for spontaneous bacterial peritonitis: how important is it? *Gastroenterology* 1999;

- 117:495-499.
9. Song HG, Lee HC, Joo YH, et al. Clinical and microbiological characteristics of spontaneous bacterial peritonitis (SBP) in a recent five year period. *Taehan Kan Hakhoe Chi* 2002;8:61-70.
10. Park MK, Lee JH, Byun YH, et al. Changes in the profiles of causative agents and antibiotic resistance rate for spontaneous bacterial peritonitis: an analysis of cultured microorganisms in recent 12 years. *Korean J Hepatol* 2007;13:370-377.
11. Seo YS, Um SH, Yim HJ, et al. Clinical features and outcomes of spontaneous bacterial peritonitis in patients with cirrhosis. *Korean J Hepatol* 2007;13(Suppl 3):S71.
12. Lee MR, Chon JY, Moon YM, Park IS, Lee KW. Efficacy of ascitic fluid culture technique using blood culture media in the diagnosis of spontaneous bacterial peritonitis. *Korean J Gastroenterol* 1995;27:659-671.
13. Bernard B, Grangé JD, Khac EN, Amiot X, Opolon P, Poynard T. Antibiotic prophylaxis for the prevention of bacterial infections in cirrhotic patients with gastrointestinal bleeding: a meta-analysis. *Hepatology* 1999;29:1655-1661.
14. Chiu YC, Lu LS, Wu KL, et al. Comparison of argon plasma coagulation in management of upper gastrointestinal angiodysplasia and gastric antral vascular ectasia hemorrhage. *BMC Gastroenterol* 2012;12:67.
15. Poole GV. Spontaneous bacterial peritonitis during bowel preparation: an example of clinical translocation. *South Med J* 1991;84:1412-1413.
16. Gumpenberger C, Kirchgatterer A, Wallner M, Kramar R, Prischl FC. Peritonitis following argon plasma coagulation of colonic angiodysplasia in a CAPD patient—an avoidable complication? *Perit Dial Int* 2005;25:500-502.
17. Macrae FA, Tan KG, Williams CB. Towards safer colonoscopy: a report on the complications of 5000 diagnostic or therapeutic colonoscopies. *Gut* 1983;24:376-383.
18. Bunchorntavakul C, Chavalitdhamrong D. Bacterial infections other than spontaneous bacterial peritonitis in cirrhosis. *World J Hepatol* 2012;4:158-168.