

A CASE REPORT OF A LARGE UNILOCULAR OVARIAN CYST.

By

T. W. YUN (尹致旺) M. B., CH. B., M. D.

and

D. H. CHO (趙東浹) M. B.

*Department of Gynaecology and Obstetrics,
Severance Union Medical College, Seoul, Korea.*

There are many large ovarian cysts on record in medical literature, but, since an abdominal operation was made possible through the discovery of Lister's antiseptic surgery, no ovarian cyst was allowed to attain any large size in the West, while it is not the case in the East, and occasionally one finds an enormous ovarian cyst. Among some of the large ovarian cysts reported in the medical journals of Japan, the most outstanding case was that of Dr. M. Kono. The measurements of his case were: circumference 161 cm., the total weight of the patient 101.4 kg., and he aspirated the cyst three times and the total quantity was 59,800 cc., weight of the patient after the operation was 54 kg.

Lately we encountered an extraordinarily large ovarian cyst and we believe that even in the East, such a case is very rare. She was admitted and operated in our hospital and returned home with a good result.

Patient:— Mrs. O.H.K., age 41, primipara, operated on the 27th. October 1936.

Complaint:— Abdominal enlargement and dyspnoea.

Duration:— Nine years.

Past History:— She enjoyed good health throughout.

On Examination:— The constitution medium, nutrition poor, sallow complexion, lungs and heart showed no change, and no oedema in the legs. The abdomen was enormously distended, some varices on the upper part of the abdomen but not so marked. There was a slight degree of oedema on the lower part of the abdomen. Very well marked thrill present and well marked tympanitic note on both flanks and epigastrium and it did not shift with the change of the posture. We diagnosed the case as an ovarian cyst, and laparotomy was performed one day after her admission into the hospital.

The findings on operation:— The abdomen was opened by the median incision between the symphysis pubis and umbilicus, and found much adhesion between the cyst and the abdominal wall, intestines, omentum, etc. After draining the fluid with an ovarian trocar and cannula, the

adhesion was separated manually in most part. The content of the cyst was rather dark red in colour and rather thin in constituency. The cyst was eventually removed with the uterine tube. The wall of the cyst was rather thickened in parts and very bulky, also it turned out to be unilocular. The cyst was from the right side ovary and still a part of the ovary could be identified. The left side ovary was normal but the tube was crumpled up, so the tube alone was resected and the ovary was left intact. The uterus was normal and we shortened the round ligaments by the plication of them. The abdominal incision was sutured by the usual method. After the suture the abdominal wall presented a shapeless, flabby bag, owing to the enormous stretch made by the cyst. The costal margin was very much everted, just like that of a trumpet end. The result of the operation was quite good and she recovered very well.

Before the operation the total weight of the patient was 120 kg., the circumference of the abdomen 160 cm., from xyphoid process to symphysis pubes 100 cm., the quantity of the fluid 58,000 cc., on the day of discharge from the hospital she weighed 44.1 kg.

REFERENCES.

1. M. Kono. *Nippon Gekagakkai*. Vol. 35, No. 4, 1934.
2. R. Samechima. *Hokkai-iho*. Part 73, 1934.
3. M. Morii. *Sanka to Fujinka*. Vol. 3, No. 3, 1935.
4. K. Hurui. *Nippon Gekagakkai*. Vol. 35, No. 10, 1935.

EXPLANATION OF FIGURE.

Fig. 1. Before the operation.

Fig. 2. After the operation.

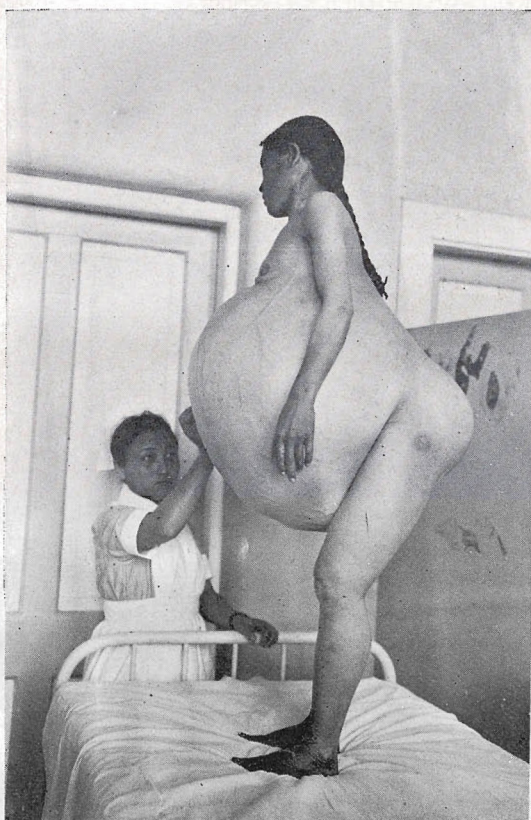


Fig. 1. Before the operation.

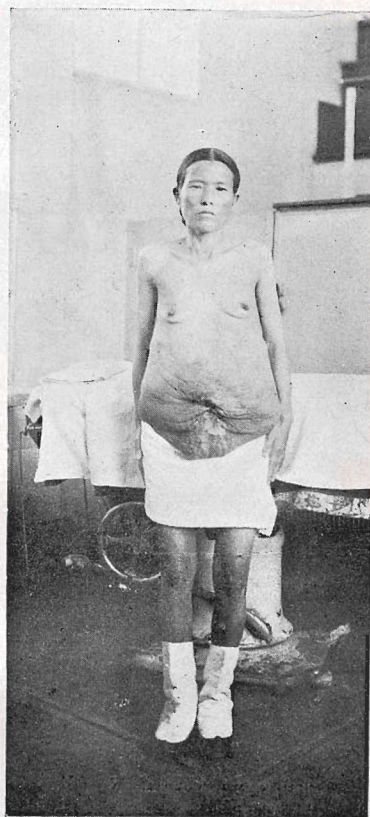

Fig. 2. After the operation.