



The Effectiveness of Interventional Trans-Arterial Embolization to Control Active Bleeding Before Medical Treatment in Patients with Acquired Hemophilia Presenting as Retroperitoneal Hematoma and Hemothorax: A Case Report

후천적 혈우병 환자에서 후복막 혈종 및 혈흉 등의 활동성 출혈의 치료로써, 중재적 혈관 시술의 효과: 증례 보고

Dong-Kyu Kim, MD* 

Department of Radiology, Severance Hospital, Yonsei University College of Medicine, Seoul, Korea

The author report a case involving a 60-year-old man with acquired hemophilia who presented with sudden-onset left abdominal pain and exhibited retroperitoneal hematoma and hemothorax. In the long term, the patient is being successfully treated with recombinant activated coagulation factor VII. Before this, when the initial active bleeding was detected, successful interventional trans-arterial embolization of the lumbar arteries was performed for immediate hemostasis using N-butyl cyanoacrylate glue and microcoils. This report highlights the effectiveness of immediate interventional trans-arterial embolization in a case of active bleeding in a patient with acquired hemophilia.

Index terms Hemophilia; Retroperitoneal Space; Hematoma; Hemothorax; Embolization, Therapeutic

Received February 1, 2019
Revised February 23, 2019
Accepted February 27, 2019

***Corresponding author**

Dong-Kyu Kim, MD
Department of Radiology,
Severance Hospital,
Yonsei University
College of Medicine,
50-1 Yonsei-ro, Seodaemun-gu,
Seoul 03722, Korea.

Tel 82-2-2228-7400

Fax 82-2-393-3035

E-mail kdk7118@yuhs.ac

This is an Open Access article distributed under the terms of the Creative Commons Attribution Non-Commercial License (<https://creativecommons.org/licenses/by-nc/4.0>) which permits unrestricted non-commercial use, distribution, and reproduction in any medium, provided the original work is properly cited.

ORCID iD

Dong-Kyu Kim 

<https://orcid.org/0000-0001-7322-2550>

INTRODUCTION

Acquired hemophilia is a rare disease caused by the development of auto-antibodies to factor VIII, and occurs in approximately 1 in 1 million individuals. Spontaneous unexpected bleeding is the most serious life-threatening complication. Clinically distinct from its inherited counterpart, individuals with acquired hemophilia experience frequent skin and other soft tissue hematomas with less common hemarthrosis (1). While spontaneous retroperitoneal hemorrhage is not common in healthy individuals, patients undergoing anticoagulation therapy, hemodialysis, or have bleeding tendencies, including hemophilia (both acquired and inherited), von Willebrand disease, or antiphospholipid syndrome, have a higher risk for developing this rare complication (2).

Because retroperitoneal hemorrhage is associated with high morbidity and mortality, adequate and timely treatment is critical. However, treatment for retroperitoneal hematoma remains controversial. Several studies have reported that hemophilia-associated hemorrhage could be prevented by clotting factor replacement therapy to achieve and maintain normal physiological levels of factor VIII or IX. However, such successful treatment has been rarely achieved (2, 3). In addition, a previous study that compared conservative management, endovascular intervention, and open surgery concluded that in hemodynamically unstable patients, endovascular embolization or stent-graft insertion should be the primary treatment of choice (2).

In the present report, we describe a patient with acquired hemophilia and sudden-onset, spontaneous retroperitoneal hematoma and associated hemothorax, who was successfully treated with endovascular embolization first, followed by hematological replacement therapy and conservative management.

CASE REPORT

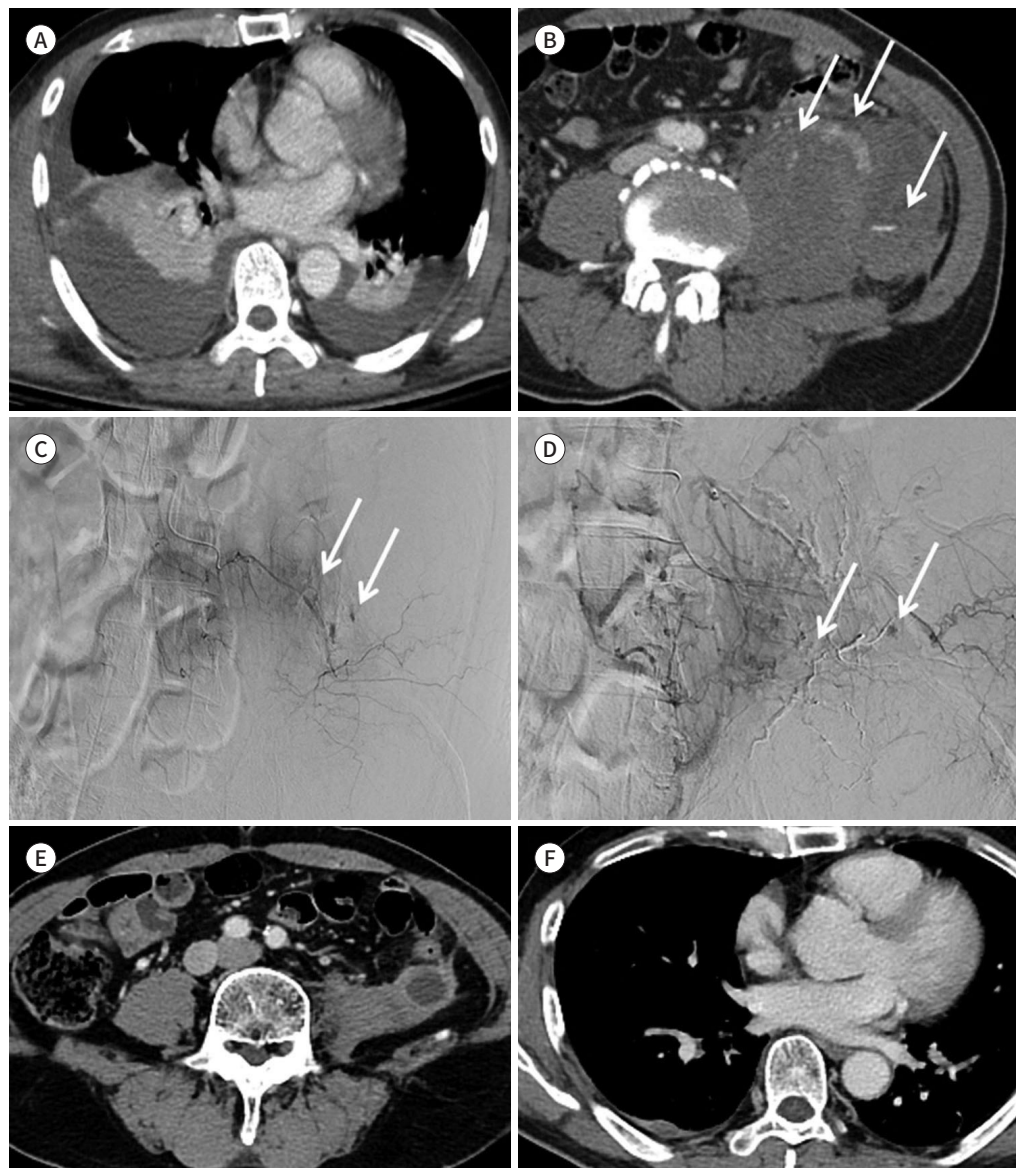
A 60-year-old man visited the emergency center complaining of acute left abdominal pain. His medical history was unremarkable, except for seizure, which well-controlled with anti-epileptic drugs. He had no known bleeding tendencies or coagulopathies, and reported no incidence of trauma. Initial iodine contrast-enhanced abdominopelvic CT (APCT) and chest CT scan revealed extensive swelling of the left psoas muscle, with associated retroperitoneal hematoma and right hemothorax. There was multifocal, bizarre intramuscular bleeding foci in the left psoas muscle, but no definite bleeding focus in the right thorax (Fig. 1A, B). Due to hemodynamic instability and the aforementioned CT findings, primary endovascular radiological intervention was preferred over exploratory laparotomy. Angiography confirmed the CT findings of multifocal active bleeding sites originating from the left lower lumbar arteries. The left lower lumbar arteries were embolized using N-butyl cyanoacrylate (NBCA) glue (Histoacryl, B. Braun Melsungen, Melsungen, Germany) and microcoils (Tornado, Cook Medical, Bloomington, IN, USA). If a bleeding branch was superselected with a 2.0 Fr microcatheter (Progreat Alpha, Terumo, Somerset, NJ, USA), the NBCA mixture with lipiodol (Guerbet, Seoul, Korea) was used as the primary embolic agent. The ratio of the mixture was 1:1 to 1:2, depending on the distance between the bleeding focus and the tip of the micro-

catheter. If the bleeding branch could not be superselected, microcoils were used as the primary embolic agent. The final angiographic examination confirmed successful hemostasis (Fig. 1C, D). Conservative management with fresh frozen plasma transfusion was initiated after the embolization procedure, and the patient continued to be hemodynamically stable.

Initial CT findings of spontaneous retroperitoneal and right thoracic hemorrhage—a rare combination—prompted the physicians to consider the possibility of hemophilia. Subse-

Fig. 1. Interventional trans-arterial embolization to control active bleeding before medical treatment in patients with acquired hemophilia.

Initial chest and abdominopelvic CT scan revealing right hemothorax (A) and extensive left psoas hemorrhagic muscular swelling, with adjacent retroperitoneal hematoma and bizarre, multifocal bleeding foci (B, arrows). Emergent endovascular embolization of the left lower lumbar arteries was performed successfully using N-butyl cyanoacrylate glue and microcoils. Similar to the initial CT scan, multifocal tiny bleeding foci were confirmed on angiography (C and D, arrows). At the latest follow-up abdominopelvic CT and chest CT scan 4 months after successful embolization, markedly decreased left retroperitoneal hematoma (E) and right hemothorax (F) with liquefaction were noted without evidence of active bleeding.



quent laboratory tests revealed prolongation of activated partial thromboplastin time, reduced factor VIII level, and positive for factor VIII inhibitor, confirming the diagnosis of acquired hemophilia. Consequently, the patient underwent recombinant activated factor VII (FVIIa) transfusion with a target hemoglobin level > 10.0 g/dL. The patient continued to undergo FVIIa transfusion. The latest follow-up APCT, performed 4 months after the embolization procedure, revealed marked decrease in the size of the retroperitoneal hematoma and hemothorax, without any active contrast extravasation (Fig. 1E, F), with a normal hemoglobin level of 13.7 g/dL. On serial chest radiograph, blunting of the right costophrenic angle, representing fluid collection in the pleural cavity, was resolved during the follow-up period without any treatment.

DISCUSSION

Few existing reports describing spontaneous retroperitoneal hematoma with hemothorax involve patients receiving warfarin with nonsteroidal anti-inflammatory drugs (4), anticoagulant agents with or without enoxaparin (5), or unfractionated heparin (6). However, to the best of our knowledge, the present report is the first to describe spontaneous retroperitoneal hematoma in a patient with acquired hemophilia, without any anticoagulation or antiplatelet therapy.

Patients with acquired hemophilia can present with a sudden onset of serious bleeding without a history of coagulopathy or anticoagulation/antiplatelet treatment. Therefore, spontaneous soft tissue bleeding, such as retroperitoneal hemorrhage and/or hemothorax—both of which are very rare in healthy individuals (7, 8)—in patients without any history of predisposing factors, should raise suspicion of acquired hemophilia. With the possibility of acquired hemophilia, appropriate treatment is critical. Treatment options include immunosuppressive therapy (to suppresses the production of the FVIII inhibitor) and hemostasis (to address uncontrolled or active bleeding). While transfusion of coagulation system activators, such as recombinant FVIIa or the active form of prothrombin complex concentrates derived from human plasma, are necessary to control bleeding (9), there may be insufficient time for these treatments to take effect in patients with severe hemodynamic instability. However, open surgery may not be feasible due to the underlying high risk for bleeding, with a high mortality rate and poor localization of the multiple bleeding sources in patients with acquired hemophilia.

Recently, endovascular embolization has been established as an effective and safe treatment modality for diverse arterial bleeding, owing to advances in embolic materials and procedural techniques. NBCA has advantages in rapid and permanent embolization, with fast polymerization upon contact with blood, compared with other embolic materials. Furthermore, the therapeutic effect of NBCA does not depend on the coagulation process; therefore, NBCA is useful in patients with coagulopathy. However, bleeding branches cannot always be superselected. If superselective embolization can be performed, microcoils can be used for vessel embolization proximal to the bleeding focus. Additionally, microcoils can be used to embolize larger vessels, which is not recommended with NBCA (10). Therefore, endovascular embolization using NBCA and microcoils has advantages in effectiveness and rapidity in pa-

tients with coagulopathy and multiple bleeding branches. As indicated in our case, minimally invasive endovascular embolization offers successful management of acute spontaneous hemorrhage in patients with acquired hemophilia, and should be considered first to control active bleeding.

In conclusion, in patients with acquired hemophilia with active soft tissue hemorrhage and hemodynamic instability, minimally invasive endovascular embolization offers successful, life-saving management to stabilize and control acute bleeding.

Conflicts of Interest

The author has no potential conflicts of interest to disclose.

REFERENCES

1. Lottenberg R, Kentro TB, Kitchens CS. Acquired hemophilia: a natural history study of 16 patients with factor VIII inhibitors receiving little or no therapy. *Arch Intern Med* 1987;147:1077-1081
2. Chan YC, Morales JP, Reidy JF, Taylor PR. Management of spontaneous and iatrogenic retroperitoneal haemorrhage: conservative management, endovascular intervention or open surgery? *Int J Clin Pract* 2008; 62:1604-1613
3. Hoots WK. Emergency care issues in hemophilia. *Treatment of Hemophilia. Montreal: World Federation of Hemophilia (WFH)* 2007:43
4. Dzielski T, Nowicka D, Pasz P, Wojciechowska J. Hemothorax and retroperitoneal hematoma with the secondary posthemorrhagic anemia as a complication of oral anticoagulant and non-steroidal anti-inflammatory drug therapy. *Pol Merkur Lekarski* 2000;8:335-336
5. Fan WX, Deng ZX, Liu F, Liu RB, He L, Amrit B, et al. Spontaneous retroperitoneal hemorrhage after hemodialysis involving anticoagulant agents. *J Zhejiang Univ Sci B* 2012;13:408-412
6. Moskovitz B, Braner B, Engel A, Kleinhaus U, Levin DR. Multifocal bleeding due to anticoagulant therapy. *Urol Int* 1988;43:53-55
7. Fukushima T, Mikane T, Ono D, Oku S, Kobayashi H, Watanabe Y, et al. A case of acquired hemophilia A with massive hemothorax. *J Anesth* 2012;26:262-264
8. Franchini M, Gandini G, Di Paolantonio T, Mariani G. Acquired hemophilia A: a concise review. *Am J Hematol* 2005;80:55-63
9. Huth-Kühne A, Baudo F, Collins P, Ingerslev J, Kessler CM, Lévesque H, et al. International recommendations on the diagnosis and treatment of patients with acquired hemophilia A. *Haematologica* 2009;94:566-575
10. Jae HJ, Chung JW, Jung AY, Lee W, Park JH. Transcatheter arterial embolization of nonvariceal upper gastrointestinal bleeding with N-butyl cyanoacrylate. *Korean J Radiol* 2007;8:48-56

후천적 혈우병 환자에서 후복막 혈종 및 혈흉 등의 활동성 출혈의 치료로써, 중재적 혈관 시술의 효과: 증례 보고

김 동 규*

우리는 갑자기 발생한 좌측 옆구리 통증을 주소로 내원한 후천성 혈우병 환자가 후복막 혈종과 혈흉이 있는 것을 관찰하였다. 장기적으로 환자는 재조합 활성 응고 인자 VII를 통해 치료받고 있지만, 그 전에 활동성 출혈이 있었을 때 N-butyl cyanoacrylate 색전 물질과 마이크로 코일을 사용하여 즉각적이고 성공적인 중재적 동맥 색전술을 시행하였다. 이에 저자들은 후천적 혈우병 환자에서 출혈이 있을 경우 즉각적인 중재적 혈관 색전술의 효과를 보고하고자 한다.

연세대학교 의과대학 세브란스병원 영상의학과