

## Bleeding from an Ileal Conduit Stomal Varix: Diagnosis with Three-Dimensional Volume Rendered Images by the use of Multidetector-Row CT (MDCT) and Management with a Transjugular Intrahepatic Portosystemic Shunt<sup>1</sup>

Eun-Ju Kang, M.D., Seong Kuk Yoon, M.D., Sang-Hyeon Kim, M.D., Jin Han Cho, M.D.,  
Myong Jin Kang, M.D., Byeong-Ho Park, M.D.

Stomal variceal bleeding is an uncommon cause of serious hemorrhage and is associated with an estimated mortality of 3-4% per episode. We report a case of ileal conduit variceal bleeding in a cirrhotic patient that was detected by the use of three-dimensional (3D) volume rendering images. The ileal conduit variceal bleeding was successfully managed by the use of a transjugular intrahepatic portosystemic shunt (TIPS) with coil embolization.

**Index words :** Ileal conduit varix  
Portosystemic shunt  
Transjugular intrahepatic  
Hypertension, portal

Stomal variceal bleeding after a colostomy, ileostomy and an ileal conduit is rare, but is a well-known complication of patients with portal hypertension. Previously, a diagnosis of stomal varix was difficult to make and most patients were treated with conservative local treatment or by the use of a surgical shunting procedure (1). However, recently, a stomal varix can be easily detected by the use of three-dimensional (3D) volume rendering images and the use of a transjugular intrahepatic portosystemic shunt (TIPS) has been generally accepted as a safe and effective therapeutic option (1-3). We report a case of the use of a TIPS with coil embolization in a cirrhotic patient where massive ileal conduit variceal hemorrhage was successfully managed.

### Case Report

A 63-year-old man was admitted to our hospital with

gross hematuria in February 2006. Computed tomography (CT) and ultrasonography examinations showed the presence of bladder cancer. The patient underwent a laparoscopic radical cystectomy and ileal conduit in March 2006. A histological examination identified the presence of transitional cell carcinoma of the bladder (stage T1 based on the American Joint Committee on Cancer AJCC classification and grade 1 based on the World Health Organization WHO 2004 classification). The patient had a history of alcoholic liver disease and bronchial asthma.

In September 2006, liver enzyme levels were elevated as determined from a routine follow-up evaluation (alkaline phosphatase ALP level, 578 IU/L; aspartate aminotransferase AST level, 241 IU/L; alanine aminotransferase ALT level, 118 IU/L). Abdominal ultrasonography and CT images suggested alcoholic liver cirrhosis but no definite evidence of abnormality in the stoma site was seen. The patient was discharged from the hospital, and the patient was recommended to receive routine follow-up care as an outpatient.

In July 2007, the patient was admitted to our hospital with stoma site pain. Based on a physical examination and CT images, no definite evidence of an abnormality

<sup>1</sup>Department of Radiology, Dong-A University College of Medicine, Busan, Republic of Korea

Received October 25, 2008 ; Accepted February 5, 2009

Address reprint requests to : Seong Kuk Yoon, M.D., Department of Radiology, Dong-A University College of Medicine, 3-1, Dongdaesindong, Seo-gu, Busan, 602-715, Republic of Korea.

Tel. 82-51-240-5367 Fax. 82-51-253-4931 E-mail: cerub@chollian.net

in the stoma site was seen. Again, the patient was discharged from the hospital. However, from a retrospective review of this case, we discovered that a newly developed peristomal varix around the conduit stoma was present as detected on CT 3D volume rendered images (Figs. 1A, B).

The patient reported spontaneous bleeding from the stoma five months later. The hemoglobin level was 8.2

mg/dl in spite of transfusion (with three units of red packed cells and three units of fresh frozen plasma). Abdominal CT and 3D volume rendered images demonstrated the presence of a more advanced peristomal varix (Figs. 1C, D), and the use of a TIPS was recommended. The procedure was performed in an emergency setting in the angiographic suite under regional anesthesia. Following the right jugular vein approach, catheteriza-

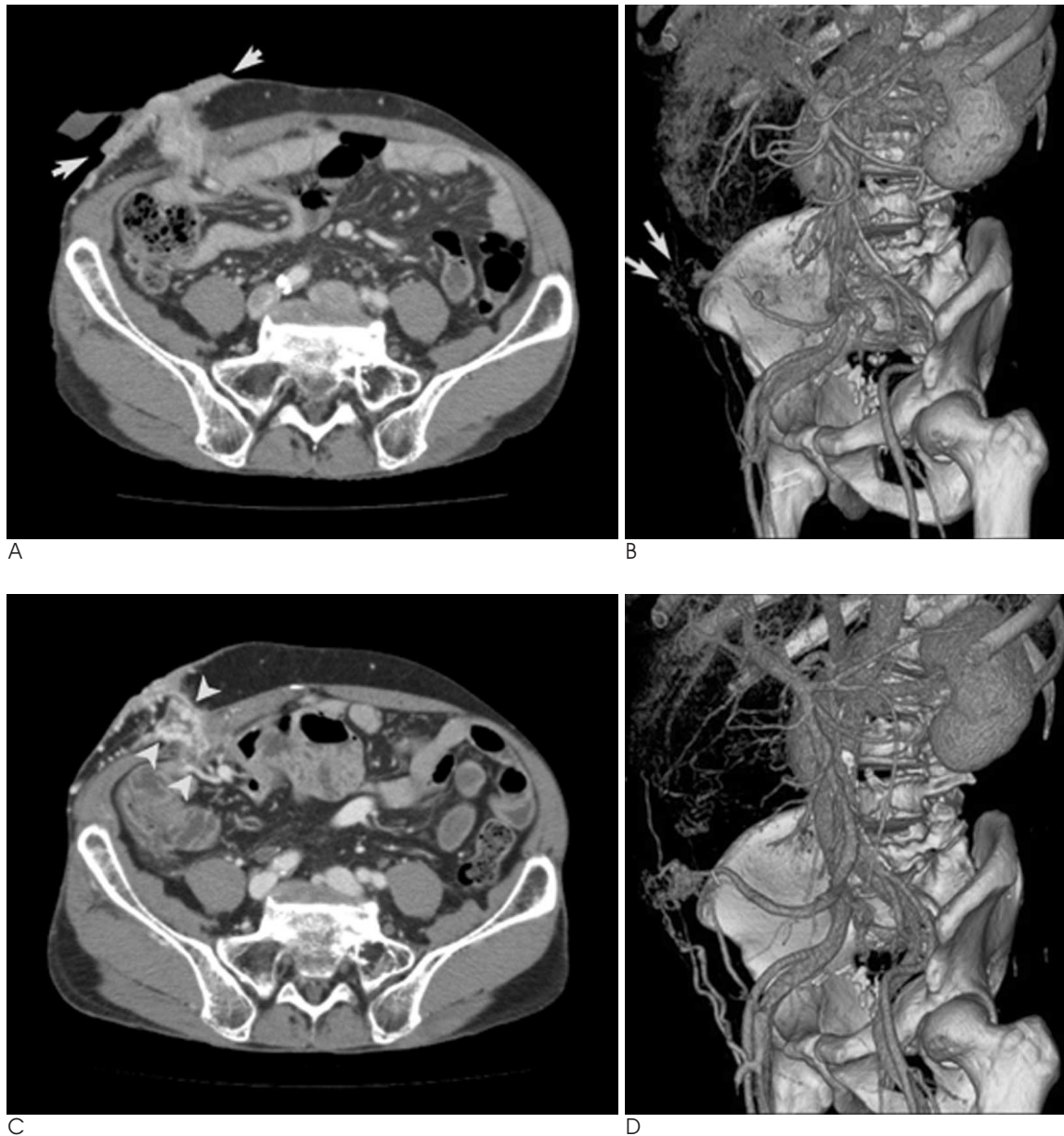


Fig. 1. A, B. A 63-year-old man visited our hospital with stoma site pain (the patient underwent a laparoscopic radical cystectomy and ileal conduit for the treatment of transitional cell carcinoma of the bladder 16 months prior).

(A) An axial CT image shows mild thickening of the peristomal skin (small arrows), but there is no definite evidence of abnormal vessels around the stoma. (B) 3D volume rendering images demonstrate the presence of peristomal collateral vessels (large arrows) that drain into the superior mesenteric vein to the right iliac vein (double arrows).

C, D. The patient reported spontaneous bleeding from the stoma five months later.

(C) An axial CT image shows the rich collateral vessels (arrowheads) around the stoma with peristomal skin thickening. (D) 3D volume rendering images show more engorged peristomal vessels.

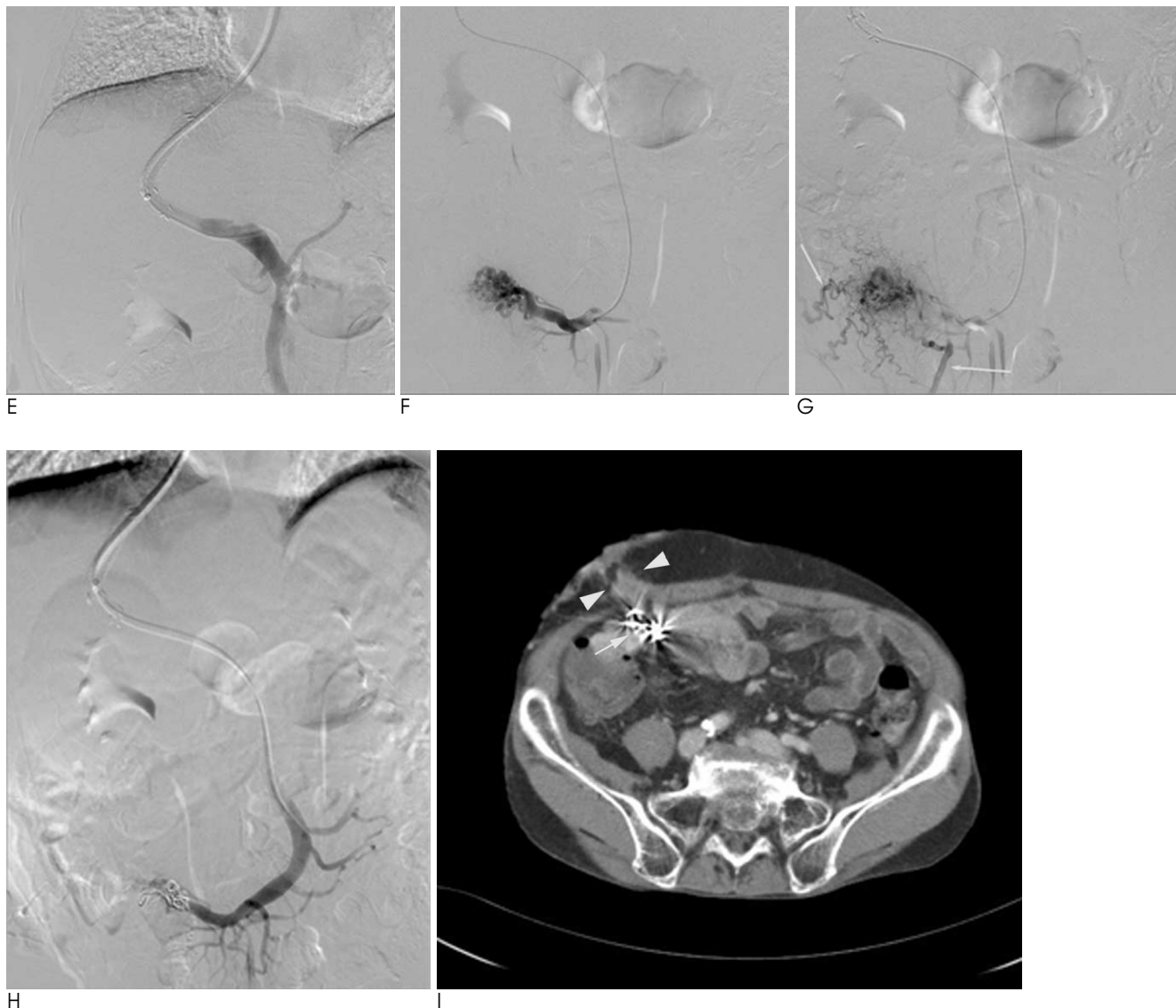


Fig. 1. E-H. A subtracted transjugular portogram demonstrates the TIPS with coil embolization, in steps. (E) A portal venogram obtained after insertion of a TIPS stent-graft. (F) A well-developed stomal varix from an ileal branch of the superior mesenteric vein is noted. (G) A delayed image demonstrates systemic drainage (arrows) of the stomal varix. (H) After coil embolization of the stomal varix, there is no further bleeding and systemic drainage. I. The patient visited the hospital after five months for routine follow-up. (I) An axial CT image shows the presence of previously inserted metallic coils (arrow). There is no evidence of abnormal vessels around the stoma (arrowheads).

tion of the right hepatic vein was performed. Then, a Colapinto needle was advanced through the liver parenchyma into the portal vein. After guide wire exchange, a catheter was advanced into the portal system and a venogram was obtained. For dilation of the parenchymal tract between the hepatic and portal vein, a 10 mm angioplasty balloon was used. A self-expandable, covered stent (with a 10 mm diameter and 9 cm length) was placed to maintain patency of the shunt. After insertion of the TIPS stent-graft, a portal venogram and superior mesenteric venogram were obtained. The

venograms demonstrated a prominent tangle of a varix that arose from an ileal branch of the superior mesenteric vein with extravasation of contrast material. We proceeded to perform embolization of the ileal varicose vein using nest coils (with two 12 mm diameter coils and one 8 mm diameter coil). Post-embolization venography showed no further bleeding at the site of the stoma varicose vein (Figs. 1E-H). The patient has remained asymptomatic during a 5-month postoperative follow-up period (Fig. 1I).

## Discussion

"Ectopic varices" are dilated portosystemic venous collaterals in unusual locations other than the gastroesophageal region. These venous collaterals can develop almost anywhere in the gastrointestinal tract and are an uncommon cause of gastrointestinal bleeding that is responsible for up to 5% of all cases of variceal bleeding (4). Bleeding ectopic varices are most commonly found at sites of previous bowel surgery including stomas. In a previously reported large series of 169 cases of bleeding ectopic varices, 26% of the cases showed bleeding from the peristomal varix. Bleeding from the duodenum was found in 17% of the cases, bleeding from the jejunum or ileum was found in 17% of the cases, bleeding from the colon was found in 14% of the cases, bleeding from the rectum was found in 8% of the cases and bleeding from the peritoneum was found in 9% of the cases (5).

A stomal varix occurs at the level of the mucocutaneous border of the stoma due to anastomoses between the high-pressure portal venous system and the low-pressure systemic venous vasculature of the adjacent abdominal wall (2). With the absence of valves in the portal system, the development of portal hypertension allows the portosystemic collaterals to open, including sites of obliterated fetal circulation in the falciform ligament and the areas of the gastrointestinal tract behind the peritoneum. Portosystemic collaterals that occur between the superior mesenteric venous component of the portal system and the abdominal wall are quite rare. However, surgery that results in apposition of the bowel to the abdominal wall or other structures drained by the systemic venous circulation may result in the development of collaterals that form in the parastomal varix or other unusual site varices (5, 6).

Bleeding from a stomal varix has been reported in as many as 25% of patients suffering with chronic liver failure with a stoma (7). This type of bleeding is an uncommon cause of serious hemorrhage and carries an estimated mortality of 3–4% per episode (8). The average time from the creation of a stoma to the development of ectopic varices and subsequent bleeding is 38 months for a ileal conduit varix and is dependent on the severity and rate of progression of liver disease (1, 7).

In the past, a diagnosis of stomal varix was difficult to make as stomal bleeding could not be distinguished from gastrointestinal bleeding. When a history of liver disease or physical signs consistent with cirrhosis or por-

tal hypertension exist, a stomal varix should be considered and the definite diagnosis is based on the use of portal venography with selective catheterization of the abnormal vein. However, recently, a stomal varix can be easily detected with the use of contrast enhanced two-dimensional reformatted and 3D volume rendering images during the portal venous and equilibrium phases of contrast administration (3). Furthermore, the use of CT imaging is noninvasive and useful for the morphological assessment of abdominal vasculature, including the arterial system as well as the portal vein.

Until 1990, most patients were treated for stomal bleeding with conservative local treatment such as direct pressure, suture ligation and sclerotherapy. However, a high re-bleeding rate occurred due to reformation of varices when portal hypertension was not treated. Furthermore, the surgical shunting procedure can provide definitive control of variceal bleeding, but the procedure frequently has not been indicated in high-risk cirrhotic patients (1). The use of a TIPS to treat ectopic varices was first reported in 1994 for patients with an intestinal varix (9). Since 1994, many cases have been reported that have described the effectiveness and safety of the use of a TIPS for treatment of ectopic varices (1–3). Currently, the use of a TIPS is considered as the treatment of choice in patients with portal hypertension and a stomal varix.

In conclusion, we have shown the development of a stomal varix in underlying liver cirrhosis patients with serial radiological images and have demonstrated the usefulness of 3D volume rendering images for the detection of a stomal varix. In addition, the use of a TIPS with coil embolization is an effective method in the therapy of cirrhotic patients with a bleeding stomal varix.

## References

1. Conte JV, Arcomano TA, Naficy MA, Holt RW. Treatment of bleeding stomal varices. Report of a case and review of the literature. *Dis Colon Rectum* 1990;33:308-314
2. Shibata D, Brophy DP, Gordon FD, Anastopoulos HT, Sentovich SM, Bleday R. Transjugular intrahepatic portosystemic shunt for treatment of bleeding ectopic varices with portal hypertension. *Dis Colon Rectum* 1999;42:1581-1585
3. Choi JW, Lee CH, Kim KA, Park CM, Kim JY. Ectopic varices in colonic stoma: MDCT findings. *Korean J Radiol* 2006;7:297-299
4. Kinkhabwala M, Mousavi A, Iyer S, Adamsons R. Bleeding ileal varicosity demonstrated by transhepatic portography. *AJR Am J Roentgenol* 1997;129:514-516
5. Norton ID, Andrews JC, Kamath PS. Management of ectopic varices. *Hepatology* 1998;28:1154-1158
6. Eckhauser FE, Sonda LP, Strodel WE, Edgcomb LP, Turcotte JG.

- Parastomal ileal conduit hemorrhage and portal hypertension. *Ann Surg* 1980;192:620-624
7. Fucini C, Wolff BG, Dozois RR. Bleeding from peristomal varices: perspectives on prevention and treatment. *Dis Colon Rectum* 1991; 34:1073-1078
8. Samaraweera RN, Feldman L, Widrich WC, Waltman A, Steinberg F, Greenfield A. Stomal varices: percutaneous transhepatic embolization. *Radiology* 1989;170:779-782
9. Haskal ZJ, Scott M, Rubin RA, Cope C. Intestinal varices: treatment with the transjugular intrahepatic portosystemic shunt. *Radiology* 1994;191:183-187

대한영상의학회지 2009; 60 : 227-231

## 회장도관정맥류출혈: 다중검출기 컴퓨터단층촬영술을 통한 3차원용적연출영상을 이용한 진단과 경피 경정맥 간내 문맥전신성 단락술을 이용한 치료<sup>1</sup>

<sup>1</sup>동아대학교병원 영상의학과

강은주 · 윤성국 · 김상현 · 조진한 · 강명진 · 박병호

도관정맥류 출혈은 심각한 출혈의 드문 원인이며 건당 3-4%의 사망률이 보고되었다. 저자들은 간경변증 환자의 회장도관정맥류 출혈을 3차원 용적연출영상을 이용하여 진단하고 경피 경정맥 간내 문맥전신성 단락술과 코일색전술을 이용하여 성공적으로 치료한 증례를 보고하는 바이다.