

Spontaneous Occlusion of Traumatic Carotid Cavernous Fistula with Pseudoaneurysm Formation-management with Neuroform Stent and Coiling

- A Case Report -

Hyun-Hee Ye, M.D., Chang-Won Cho, M.D., Chang-Soo Kim, M.D.¹,
June-Woo Park, M.D., Jae-Eon Lee, M.D., and Dae-Jo Kim, M.D.

Department of Neurosurgery, Radiology¹, Maryknoll Medical Center, Busan Catholic Health System, Busan, Korea

We experienced a case of traumatic carotid cavernous fistula (CCF) which was occluded spontaneously within 7 days after transfemoral carotid angiography with complete disappearance of symptoms. Traumatic CCF is almost always type A and known to rarely resolve spontaneously. The suggested mechanism of spontaneous occlusion were manual compression of carotid artery, hypotension during percutaneous or open direct carotid angiography under general anesthesia in the past as well as thrombogenicity of iodinated contrast media and catheterization procedure itself are more related with recent transfemoral carotid angiography. The pseudoaneurysm managed with coil or balloon should be frequently followed up due to compaction by the surrounding thrombus.

Key Words: Spontaneous occlusion · Traumatic CCF · Thrombogenicity · Contrast media · Pseudoaneurysm



INTRODUCTION

Traumatic carotid cavernous fistula (CCF) is mostly type A by Barrow's classification which needs therapeutic intervention mostly and rarely resolve spontaneously². In contrast, dural forms of traumatic CCF are very rare and have a much more tendency to resolve spontaneously and show better response to conservative management. We experienced a case of spontaneous occlusion of type A traumatic CCF with pseudoaneurysm formation which was managed with stent assisted coiling.



CASE REPORT

A 38-year old male fell down and had blunt trauma to his head. He got admitted to local hospital on November 20th, 2004.

Corresponding author: **Chang-Won Cho, M.D.**
Department of Neurosurgery, Maryknoll Medical Center,
Daechong-dong 4-ga, Jung-gu, Busan, 600-730, Korea
Tel: 82-51-461-2456, Fax: 82-51-466-6164
E-mail: braincwc@hotmail.com

Ptosis developed on his right side 2 days after admission. During admission at the hospital for 33 days, he felt bruit in his head, progressive proptosis, exophthalmus and decreased visual acuity. The Magnetic resonance imaging checked one week after admission showed the prominent right ophthalmic vein which was unnoticed at that time on retrospective review (Fig. 1). He was transferred to another local hospital for diagnostic angiography which confirmed the traumatic CCF on December 24th, 2004 (Fig 2). He has felt bruit in his head until transfemoral carotid angiography (TFCA). He was transferred to our hospital one week later for therapeutic intervention on December 30th, 2004. He had proptosis, ophthalmoplegia, ptosis and complained of headache, right eyeball pain and decreased visual acuity at outpatient clinic. However, bruit was not audible by auscultation and not felt by the patient, himself anymore. The right internal carotid angiogram checked one week earlier before transfer showed cavernous sinus opacification with early draining to superior ophthalmic vein (Fig. 2). Three-dimensional computed tomography angiography (3D-CTA) checked at our hospital showed aneurysm at C4/5 junction of right cavernous carotid artery and no draining vein (Fig.

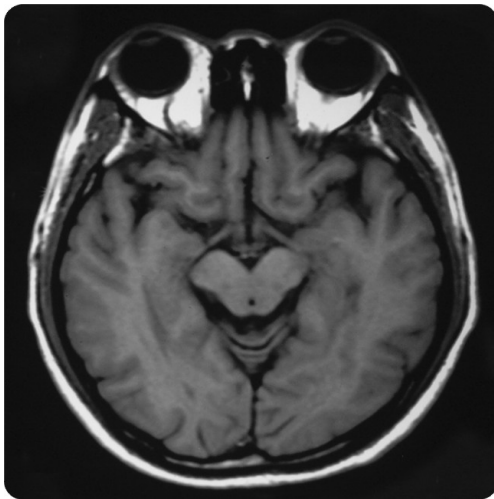


Fig. 1. Magnetic resonance imaging shows the prominent right ophthalmic vein.

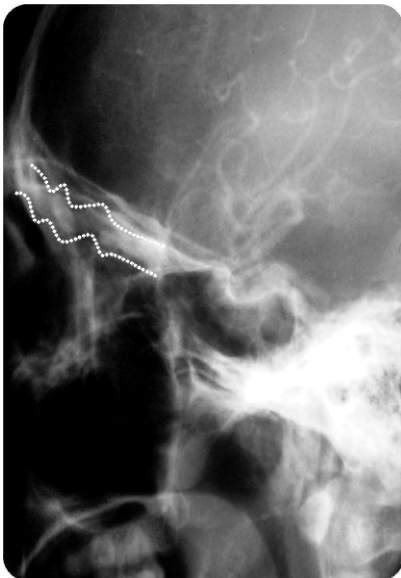


Fig. 2. Right internal carotid artery angiogram shows cavernous sinus opacification with early draining to superior ophthalmic vein (dotted line).

3A). A follow up TFCA showed aneurysmal sac at the C4/5 junction, neck 3.5 mm and height 3 mm, dome 3.8 mm in size with no opacification of cavernous sinus and draining vein (Fig. 3B). The CCF was occluded spontaneously with pseudoaneurysm formation during the 7 days since diagnostic angiography. We tried the neuro form 2 stent-assisted coiling to occlude the pseudoaneurysm. The self expandable neuro form 2 stent was successfully deployed across the rent of carotid wall. However, the proximal end of stent was bent toward carotid lumen and the stent migra-

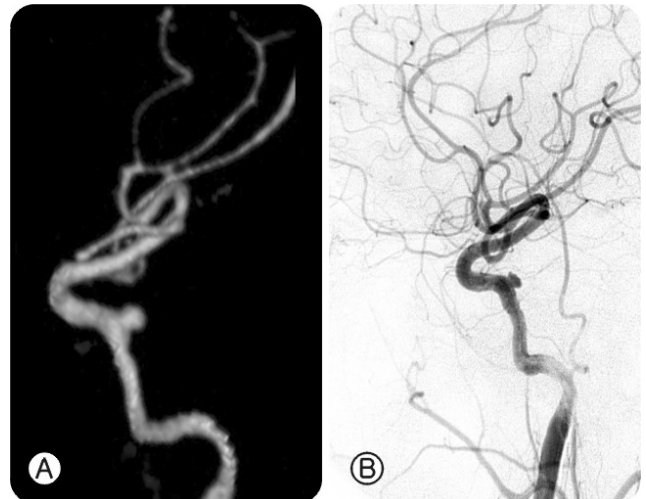


Fig. 3. **A:** Three-dimensional computed tomography angiography shows aneurysm at C4/5 junction of right cavernous carotid artery and no draining vein. **B:** Follow up, right internal carotid artery angiogram shows the aneurysmal sac at the C4/5 junction with no opacification of cavernous sinus and draining vein.

ted distally a little bit by the catheter during the coiling procedure which was aborted (Fig 4A). Two months later, we did control TFCA and found out the size of pseudoaneurysm increased, neck 2.4 mm and dome 6 mm in size (Fig 4B). We tried Guglielmi detachable coil (GDC) embolization again and occluded the pseudoaneurysm successfully (Fig 4C). The patient showed rapid improvement since spontaneous occlusion of CCF and all the symptoms & signs were free when he left hospital. Control TFCA was done again 10 months later and showed partial filling of aneurysmal sac due to coil compaction without symptoms (Fig 4D).



DISCUSSION

Barrow et al classified the CCF in according to the angiographic finding into 4 types²⁾. Type A fistula is direct shunting between internal carotid artery and cavernous sinus and has no contribution from the meningeal branches of internal and external carotid artery. Type B, C and D are dural shunts between cavernous sinus and meningeal branches of internal and external carotid arteries. Traumatic CCF are almost always type A and 3% are dural forms^{2,5)}. Type A traumatic CCF rarely resolves spontaneously, about 3%, however, dural forms of CCF tends to

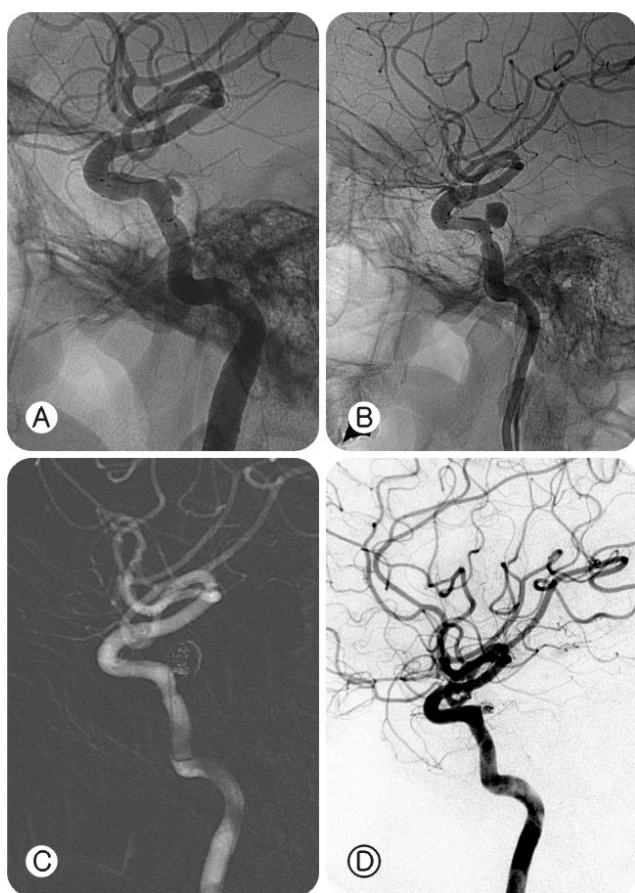


Fig. 4. Stent-assisted Guglielmi detachable coil (GDC) embolization for carotid cavernous fistula. **A:** Poststenting angiogram shows proximal end of stent bent toward carotid lumen. **B:** Two months later, right internal carotid artery angiogram shows the pseudoaneurysm increased in size. **C:** Right internal carotid artery angiogram at immediate post-GDC embolization shows complete occlusion of pseudoaneurysm. **D:** 10 months later, right internal carotid artery angiogram shows partial filling of pseudoaneurysmal sac due to coil compaction.

resolve spontaneously more about 30%^{5,7,8,10,11,17,27}. The spontaneous thrombosis of traumatic CCF with pseudoaneurysm formation were rarely reported^{15,20,21,23-31}. Nishijima et al reported 5 cases of spontaneous occlusion of traumatic CCF verified by angiography on 1985 by retrospective literature review including their case²³. Three of the five cases developed the false aneurysm after spontaneous occlusion of CCF and no further detail about the fate of false aneurysms was described. Most of the case reports of spontaneous occlusion of CCF were done by direct percutaneous carotid angiography or open carotid angiography

under general anesthesia in the past^{15,24,26,30,31}. However, spontaneous obliteration of CCF after TFCA was also reported rarely since first time on 1981 by Shields et al^{20,23,27}. Several mechanisms of the spontaneous occlusion of traumatic CCF were suggested. Firstly, manual compression of carotid artery during the direct carotid angiography procedure which may reduce the pressure difference through the shunts and cause occlusion^{15,24,26,30,31}. There was a case of spontaneous occlusion of CCF during orbital venogram in which a temporary decrease of pressure difference between the internal carotid artery and the cavernous sinus during dye injection through the superior ophthalmic vein may cause stasis of blood flow and thrombosis²³. Secondly, hypotension could be a cause of occlusion²⁴. Carotid angiography procedure was done under general anesthesia in the past with resultant hypotension which may reduce blood flow through the shunt and cause occlusion. There was a case of occlusion of preexisting CCF due to shock state from other cause²⁴. Third one was contrast media used during the angiography^{23,24,28,29}. The ionic and non-ionic contrast media are well known to activate the coagulation system and platelets in vivo study¹³. Lastly, the catheterization procedure itself induce activation of coagulation system and platelets through vessel injury and cause vessel spasm¹³. In this case, the CCF was occluded within 7 days after angiographic procedure which was performed by transfemoral route and not associated with hypotension and manual compression of carotid artery. The exact mechanism of spontaneous occlusion of CCF in this case is uncertain, but the thrombogenicity of contrast media and the catheterization procedure itself could be related with the occlusion of shunts. The natural history of pseudoaneurysm after spontaneous occlusion of traumatic CCF is controversial^{4,9,11,12,16,18,19,22}. Even though spontaneous regression could be possible, they also could cause cerebral embolism and ischemic event, enlargement and recanalization²². In our case, the pseudoaneurysm enlarged significantly after two months which was managed neuroform² stent assisted coiling successfully^{1,3,6,14}. After 10 months, the pseudoaneurysm was partially filled with dye on control TFCA due to coil compaction. Higashida et al reported five cases of pseudoaneurysms in a series of 206 patients with direct CCF and found that direct placement of detachable balloons or coils into the pseudoaneurysm did not prevent further expansion or dissection of tear

because no wall or tissue plane other than the thrombus existed to keep the embolic material in place¹²⁾. Kinugasa et al used liquid embolic material instead of coil or ballon to obliterate the pseudoaneurysm to prevent the compaction¹⁶⁾. The pseudoaneurysm should be followed up regularly to check up late recanalization due to compaction^{4,9,11,12,16)}.



CONCLUSION

Traumatic CCF could be occluded spontaneously very rarely. The mechanism of the spontaneous occlusion is unclear but the contrast media and/or the catheterization procedure itself could be related with this event. The pseudoaneurysm after spontaneous occlusion of CCF may cause cerebral embolic ischemia and/or recanalize to make CCF again. The pseudoaneurysm should be regularly followed up after coiling due to compaction to surrounding thrombus.



REFERENCES

1. Ahn JY, Lee BH, Joo JY: Stent-assisted Guglielmi detachable coils embolization for the treatment of a traumatic carotid cavernous fistula. **J Clin Neurosci** 10:96-98, 2003
2. Barrow DL, Spector RH, Braun IF, Landman JA, Tindall SC, Tindall GT: Classification and treatment of spontaneous carotid-cavernous sinus fistulas. **J Neurosurg** 62:248-256, 1985
3. Benitez RP, Silva MT, Klem J, Veznedaroglu E, Rosenwasser RH: Endovascular occlusion of wide-necked aneurysms with a new intracranial microstent (Neuroform) and detachable coils. **Neurosurgery** 54:1359-1367, 2004
4. Debrun G, Lacour P, Vinuela F, Fox A, Drake CG, Caron JP: Treatment of 54 traumatic carotid-cavernous fistulas. **J Neurosurg** 55:678-692, 1981
5. Debrun GM, Vinuela F, Fox AJ, Davis KR, Ahn HS: Indications for treatment and classification of 132 carotid-cavernous fistulas. **Neurosurgery** 22:285-289, 1988
6. Fiorella D, Albuquerque FC, Han P, McDougall CG: Preliminary experience using the Neuroform stent for the treatment of cerebral aneurysms. **Neurosurgery** 54:6-16, 2004
7. Ghosh S, Larsen D, Day JD: Cavernous carotid fistulas in Winn HR (ed): **Neurological surgery**, ed 5. Philadelphia: WB Saunders, 4:2341-2352, 2004
8. Goto K, Hieshima GB, Higashida RT, Halbach VV, Bentson JR, Mehringer CM, et al: Treatment of direct carotid cavernous sinus fistulae. Various therapeutic approaches and results in 148 cases. **Acta Radiol Suppl** 369:576-579, 1986
9. Graves VB, Strother CM, Partington CR, Rappe A: Flow dynamics of lateral carotid artery aneurysms and their effects on coils and balloons: An experimental study in dogs. **AJNR Am J Neuroradiol** 13:189-196, 1992
10. Halbach VV, Hieshima GB, Higashida RT, Reicher M: Carotid cavernous fistulae: Indications for urgent treatment. **AJR Am J Roentgenol** 149:587-593, 1987
11. Halbach VV, Higashida RT, Dowd CF, Fraser KW, Smith TP, Teitelbaum GP, et al: Endovascular treatment of vertebral artery dissections and pseudoaneurysms. **J Neurosurg** 79:183-191, 1993
12. Higashida RT, Halbach VV, Tsai FY, Norman D, Pribram HF, Mehringer CM, et al: Interventional neurovascular treatment of traumatic carotid and vertebral artery lesions: Results in 234 cases. **AJR Am J Roentgenol** 153:577-582, 1989
13. Hoffmann JJ, Tielbeek AV, Krause W: Haemostatic effects of low osmolar non-ionic and ionic contrast media: A double-blind comparative study. **Br J Radiol** 73:248-255, 2000
14. Howington JU, Hanel RA, Harrigan MR, Levy EI, Guterman LR, Hopkins LN: The Neuroform stent, the first microcatheter-delivered stent for use in the intracranial circulation. **Neurosurgery** 54:2-5, 2004
15. Isfort A: Spontaneous healing of a traumatic carotid artery-cavernous sinus fistula in a child during angiography. **Klin Monatsbl Augenheilkd** 150:821-827, 1967
16. Kinugasa K, Mandai S, Tsuchida S, Kamata I, Ohmoto T: Direct thrombosis of a pseudoaneurysm after obliteration of a carotid-cavernous fistula with cellulose acetate polymer: Technical case report. **Neurosurgery** 35:755-760, 1994
17. Komiyama M, Nakajima H, Nishikawa M, Kan M: Traumatic carotid cavernous sinus fistula: Serial angiographic studies from the day of trauma. **AJNR Am J Neuroradiol** 19:1641-1644, 1998
18. Komiyama M, Yasui T, Yagura H, Fu Y, Nagata Y: Traumatic carotid-cavernous sinus fistula associated with an intradural pseudoaneurysm: A case report. **Surg Neurol** 36:126-132,

1991

19. Lee CY, Yim MB, Kim IM, Son EI, Kim DW: Traumatic aneurysm of the supraclinoid internal carotid artery and an associated carotid-cavernous fistula: Vascular reconstruction performed using intravascular implantation of stents and coils. Case report. **J Neurosurg** 100:115-119, 2004
20. Luo CB, Teng MM, Chang FC, Chang CY: Spontaneous thrombosis and complete disappearance of traumatic carotid-cavernous fistulas after angiography. **J Chin Med Assoc** 68: 487-490, 2005
21. Men S, Ozturk H, Hekimoglu B, Sekerci Z: Traumatic carotid-cavernous fistula treated by combined transarterial and transvenous coil embolization and associated cavernous internal carotid artery dissection treated with stent placement. Case report. **J Neurosurg** 99:584-586, 2003
22. Mori S, Feliciani M, Guglielmi G, Guidetti G, Dazzi M, Silipo P: Regression of an internal carotid artery pseudoaneurysm after therapeutic embolization of a post-traumatic carotid-cavernous fistula secondary to gunshot injury. **Neuroradiology** 32:226-228, 1990
23. Nishijima M, Iwai R, Horie Y, Oka N, Takaku A: Spontaneous occlusion of traumatic carotid cavernous fistula after orbital venography. **Surg Neurol** 23:489-492, 1985
24. POTTER JM: Carotid-cavernous fistula; five cases with spontaneous recovery. **Br Med J** 4891:786-788, 1954
25. Reiber ME, Burkey BB: Intracavernous carotid pseudoaneurysm after blunt trauma: Case report and discussion. **Head Neck** 16:253-258, 1994
26. Schiefer VW, WOLLENSAK J: Healing of an arteriovenous fistula in the sinus cavernosus after cerebral angiography. **Zentralbl Neurochir** 21:84-92, 1961
27. Shields CB, Tutt HP: Spontaneous obliteration of carotid-cavernous fistulas. **South Med J** 74:617-620, 1981
28. Stampfel VG: Spontaneous closure of traumatic carotidcavernous sinus fistulae - an effect of angiography? **Rofo** 141:176-179, 1984
29. Takahashi M, Nakano Y: Magnification angiography of dural carotid-cavernous sinus fistulae with emphasis on clinical and angiographic evolution. **Neuroradiology** 19:249-56, 1980
30. Van der Drift JH, Sparling CM, van den Berg D, Magnus O: Spontaneous occlusion of a carotid-cavernous shunt. **Neurology** 17:187-193, 1967
31. Voigt K, Sauer M, Dichgans J: Spontaneous occlusion of a bilateral carotidocavernous fistula studied by serial angiography. **Neuroradiology** 2:207-211, 1971