

말초동맥질환

Peripheral Arterial Disease

가

505

Yong - Bok Koh, M.D.

Department of General Surgery

The Catholic University of Korea, College of Medicine, Kangnam St. Mary's Hospital

E-mail : ybkoh@catholic.ac.kr

가 가

가

가 가

Abstract

Peripheral arterial disease include disease all disorders involving carotid artery, vertebral artery, subclavian artery branched out from aortic arch, upper extremities arteries, thoracoabdominal aorta, its visceral arteries and lower extremities arteries. Rapid advances in vascular surgery (especially arterial surgery) began after World War II, beginning with the treatment of arterial lesions with vascular repair and with bypass procedures, and vascular diseases previously noted beyond the surgical treatment can be corrected by recent vascular surgery. This evolution of vascular surgery has attributed to the development of arteriography, anesthesia, blood transfusion, antibiotics, anticoagulation and synthetic graft materials. These advanced vascular surgical techniques have yielded a cornerstone for the development of the modern organ transplantations. Recently, the incidence of vascular diseases in Korea increased remarkably than before and clinicians should pay attention to make early diagnosis and to perform appropriate treatment for these diseases. Because the detailed descriptions regarding all these vascular diseases in is limited space are difficult, the author would like to describe clinical aspect of the commonly encountered peripheral arterial diseases such as atherosclerotic occlusive disease, abdominal aortic aneurysm, diabetic foot, cerebrovascular disease, Buerger's disease of lower extremities with introducing clinical manifestation of acute and chronic peripheral arterial occlusive disease.

Keywords : Peripheral vascular disease; Atherosclerotic occlusive disease; Abdominal; Aortic aneurysm; Diabetic foot; Cerebrovascular disease; Buerger's disease

(1, 2).

1950

sion)가 , 가

(3).

가 (6).

5P's sign ,

가 , , .
75%

(atherosclerosis) , (one joint level below occluded artery) .
(cerebrovascular disease), (Buerger's disease) (calf)

(nerve ending)

,
가 가 . 가
(striated muscle)

1.

가
golden time 가 가

6~8

(arterial fibrillation),
(myocardial infarction),

(common femoral artery) (4). (spasm) ,
(intraarterial thrombosis)

(digital artery)
"blue toe syndrome" (5) (propagation)

(collateral circulation)

(hypoperfu-

가

가 .

가

가

(10).

6~8

Fogarty catheter

(claudication distance)

가

,

.

(coldness)

(7).

가

par-

.

averine

reserpine

,

,

(ischemic rubor),

heparin, urokinase

(thickened brittle nail)

(8, 9)

가

,

(trophic changes)

.

bypass

.

(metabolic requirement)

(rest pain)

(

)

.

,

가

(unhealing ulcer)가

.

.

.

(foot or digit)

2.

(me-

가

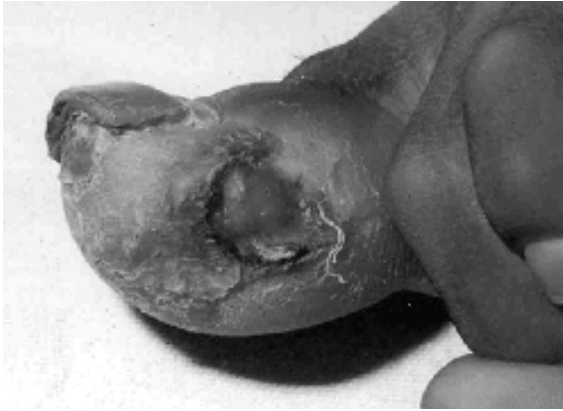dial malleolus)

(claudication)

.

(1, 2). 가

Atherosclerotic Arterial Disease



1. 가
trophic 가 .

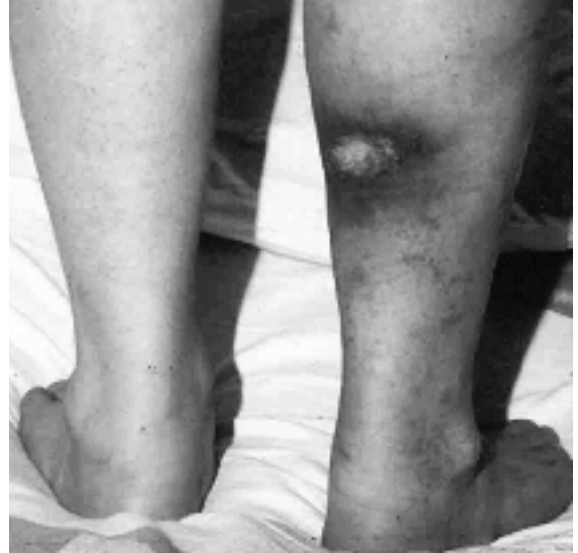가
(atheroma)

(11).

(hyper - cholesterolemia), ,

, , (hyper - triglyceridemia),
(hyper - homocysteinemia),
(sedentary lifestyle) 가 .

lipoprotein
LDL(low density lipoprotein) 100 mg/dl ,
HDL 35 mg/dl ,
200 mg/dl
120% .
140/90 30 가 .



2.

1.

(Aortoiliac Occlusive Disease)

Leriche

(
proximal claudication), ,

Type I(10%),

Type II(25%),

Type III(65%)

가 .

가 (dorsalis pedis) “blue toe syndrome” 가 (common femoral artery), (superficial femoral artery), (deep femoral artery), (popliteal artery), (anterior or posterior tibial artery) (peroneal artery) . CT(spiral) MRA가 (arteriography) . 가 (brachial artery) 가 가 (adductor canal) 가 (spinal stenosis) . , 가 가 . blue toe syndrome . 가 가 가 (endarterectomy), (extra - anatomic bypass) 가 balloon catheter dilatation stent . , 가 . wave form ABI(ankle brachial pressure index)가 0.40 . Duplex U/S 가 (12).

running off
가
"Reversed bypass"
(angioscope) (valvulotome)
"in situ
bypass"
valvulotome
"translocated nonreversed bypass"
가
3.0 mm PTFE
vein patch(Taylor's patch) vein cuff
atheroma 가
(roof patch angioplasty)
(bypass) balloon ca-
Fem - pop bypass(above knee Fem - pop below theter
knee Fem - pop)가 endovascular
(inflow) 가
가
(saphenous vein) PTFE(polytetrafluoroethylene)
(outflow) (knee joint)
PTFE 가 PTFE 50
5%가
(14). outflow (10).
가 PTFE (microangiopathy)

(macroangiopathy)

(diabetic neuropathy)

muscle) 가 (intrinsic
(metatarsal bone)

(head)가 (15).

(atheroma)

가

가
(synergistic action) 가

(transient ischemic attack : TIA),
(amaurosis fugax,
) TIA

가

TIA

가 2 15 , 24

(debridement)

24

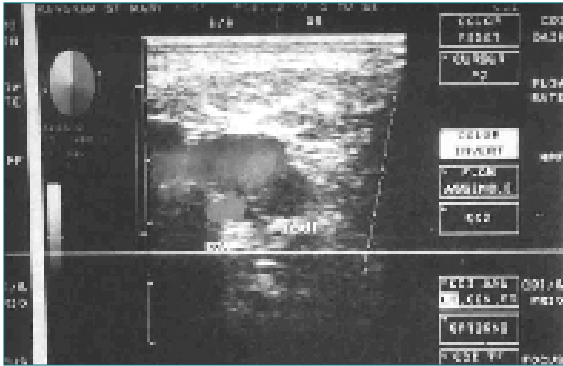
weakness, paralysis, clumsiness

(dysarthria, imperfect articulation in speech)

가 , (motor dysfunction), amaurosis fugax, numbness,

4. (Cerebrovascular Disease)

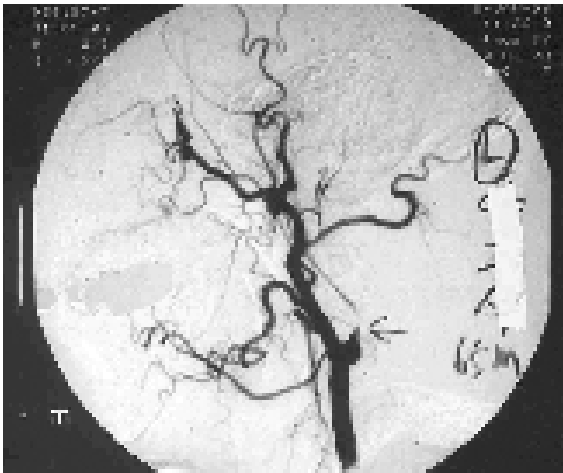
가



3. duplex
가



5. 3



4. 3

TIA, amaurosis fugax

가 major stroke 가

Duplex U/S

CT MRI brain imaging

Duplex U/S

(carotid endarterectomy,

CEA)

가

patch

shunt

가

가 가

가

가 dominant aphasia가 (15).

60%

(weakness), , clumsiness ,

TIA ,

, , (diplopia)

dysarthria

TIA 24

48 ~ 72

CEA가

(small stroke)

TIA가

CEA

가

1/3 TIA MRI CT

가

(16).

balloon

stent

가 (horseshoe kidney)

5. (Abdominal Aortic Aneurysm : AAA)

triple A

가 가 (fusiform) (CAO) 가 (30)

60 ~ 70 5 ~ 10%가

(10). 가

. 4.0 cm

skin, cellophane wrapping

“intrascapular

nonresective repair” 1966 Creech DeBakey 90% (elec-

(17, 18). rupture tive surgery) 2%

(21 ~ 23).

1 0.4 cm가 , szi- (endovascular procedure)

lagyi(19) 6 cm

5 20%

Darling 가 4 ~ 7 cm 5 stents

25%, 4 cm 9.5%

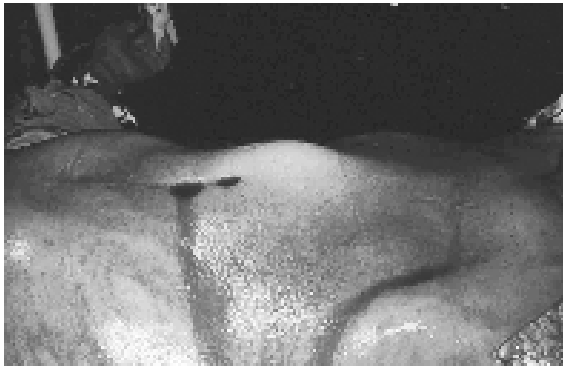(20).

가 (asympto-

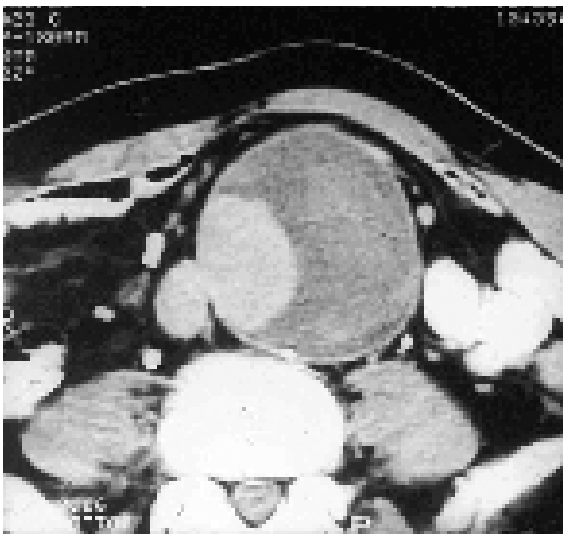matic pulsatile mass)가

20

가



6. 가

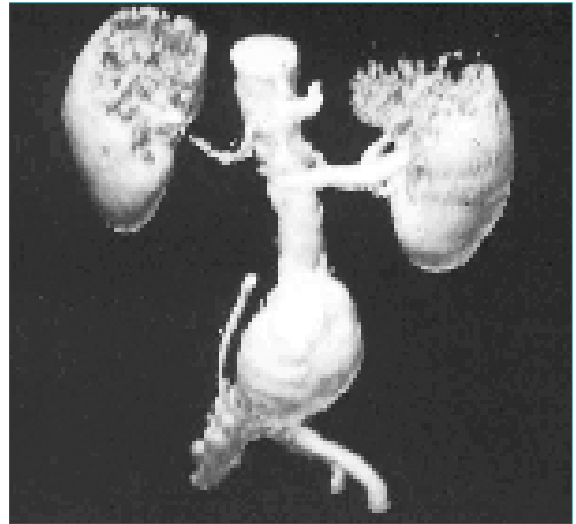


7. 6 CT
(7.5 cm)가

(Thromboangitis Obliterans)

(Buerger's disease)

1960 Wessler (24)



8. 6 3 - D spiral CT
가

(presenile arterosclerosis)
(embolism) (thrombo-
sis)

50

10%가

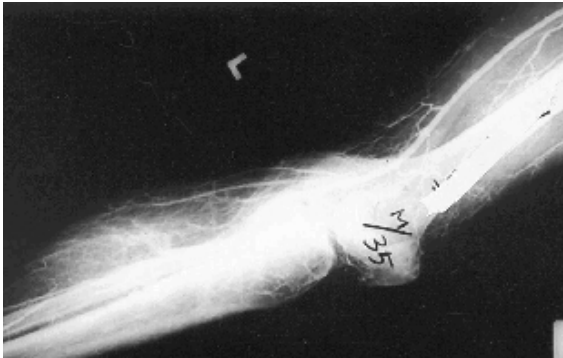(25~28).

가

가 가

가 (autoimmune disease)

가



9.

가

가

(migratory phlebitis)

20~30%

가 (26).

가

(13, 28, 29).

(Tree root)

(spider leg)

25%

(collaterals)가

가

corkscrew

(26, 30).

(26).

가

가

가

가

가

가

가

30

1,000

1/3

, 1/3

가

1/3

(criteria)

1)

2) 20~40 (50)

3) ()

4)

5)

6) Raynaud (,

)

(26).

가

가 (3%)

가



1. 가
: , 1984 : 1 - 3
2. Rich NM. Injuries of the abdominal aorta in vascular trauma, in Rich NB, Spencer FC, eds. Vascular trauma, Philadelphia : WB saunders, 1978 : 441 - 7
3. Kenneth O, Richard MG. Arterial disease, in Schwartz etc. in principle of surgery. 7th ed. New York : McGraw - Hill, 1999 : 931 - 2
4. Billig DM, Hellman GL. Arterial embolism. Arch Surg 1967 ; 95 : 1 - 7
5. Fisher DR Jr, Clagett GP. Dilemmas in Dealing with the blue the syndrome. Aortic versus peripheral source. Am J Surg 1984 ; 148 : 836 - 41
6. Haimovici H. Peripheral arterial embolism. Angiology 1950 ; 1 : 20 - 4
7. Fogarty J, Cranly JJ. A method for extraction of arterial emboli and thrombi. Surg Gyn Obst 1963 ; 116 : 241 - 8
8. The STILE investigators. Results of a prospective randomized

Trial evaluating surgery versus extremity. The STILE trial. Ann Surg 1994 ; 220 : 251 - 68

9. Sicard GA, Schier JJ. Thrombolytic therapy for acute arterial occlusion. J Vasc Surg 1985 ; 2 : 65 - 72
10. Charles GR. Clinical evaluation of patients with peripheral vascular disease of the Lower extremity, in Fredric J and Stanley H, eds. Vascular surgery of the lower extremity. St. Louis, Missouri : C.V Mosby 1985 ; 3 - 11
11. Ross R. Atherosclerosis - An Inflammatory disease, N Engl J Med 1999 ; 340 : 115 - 26
12. Criqui MH, Langer RD. Mortality over a period of 10 years in patients with peripheral arterial disease. N Engl J Med 1992 ; 326 : 381 - 7
13. Ischemic ulcer gangrene
prostaglandin E1
1986 ; 31 : 87 - 96
14. Veith FJ, Gupta SK. Six - year prospective multicenter randomized comparison of autologous saphenous vein and expanded polytetrafluoroethylene grafts in infrainguinal arterial reconstructions. J Vasc Surg 1986 ; 3 : 104 - 10
15. 1998 ; 41 : 615 - 23
16. NASCET Collaborators. Beneficial effect of carotid endarterectomy in symptomatic patients with high grade carotid stenosis. N Engl J Med 1991 ; 325 : 445 - 53
17. Creech O Jr. Endo - aneurysmorrhaphy and treatment of aortic aneurysm. Ann Surg 1996 ; 164 : 935 - 46
18. DeBakey MZ, Crawford ES. Aneurysm of abdominal aorta : analysis of results of graft replacement therapy one to eleven years after operation. Ann Surg 1964 ; 160 : 622 - 35
19. Szilagyi DZ, Smith RF. Contribution of abdominal aortic aneurysmectomy to prolongation of life. Ann Surg 1966 ; 164 : 678 - 89
20. Darling RC, Messina CR. Autopsy study of unoperated abdominal aortic aneurysms ; Circulation the case for early resec-

- tion. 1977 ; 56 : (Suppl 2) : 161
21. , , , . 63 . 1994 ; 1 : 70 - 9
22. , , , . 1992 ; 1 : 80 - 5
23. , , , . 가 2003 ; 19 : Behset . 44 - 8
24. Wessler S, Ming SC, Gurewich V. A critical evaluation of thromboangiitis obliterans. N Engl J Med 1960 ; 262 : 1149 - 53
25. . 1987 ; 30 : 486 - 90
26. . Buerger . 가
- 가 1994 ; 47 : 1053 - 63
27. Shinoya S. Buerger's disease. Nagoya : Univ. of Nagoya Press, 1990
28. . (). 1998 ; 41 : 600 - 6
29. , , , . Buerger Pros-taglandin E1 Opalmon , 1993 ; 44 : 938 - 48
30. , , , , . autogenous saphenous vein bypass graft . 1977 ; 19 : 1 - 10

6 ()

1.) 6. 가)
2.) 7. 가)
3.) 8. 가)
4. 가) 9.)
5.) 10. 가)