

항문질환의 진단 및 치료

Diagnosis and Treatment of Anal Diseases

48

Sang Jeon Lee, M.D.

Department of General Surgery

Chungbuk National University College of Medicine & Hospital

E-mail : colon@chungbuk.ac.kr

Abstract

Anal diseases are very common and it is important for a medical practitioner to understand how to deal with these diseases. To establish diagnoses of specific conditions, detailed history taking, inspection, palpation including digital rectal examination, and anoscopic examination are performed. Sigmoidoscopy is also required if upper lesions are suspected. History taking should include information about bleeding, prolapse, swelling, pain, discharge, irritation, bowel habit, continence, abdominal symptoms, weight loss. Sims' position and lithotomy position are commonly used for physical examination of the anal area. In addition to careful inspection and palpation, digital rectal examination should be performed to evaluate the anal canal width and sphincter strength. Above all, digital examination is a very useful and cheap tool to find rectal cancer which commonly occurs after middle - ages. Common anal diseases such as hemorrhoids, anal fissure, perianal abscess and fistula - in - ano, pruritus anal, and rectal prolapse are reviewed.

Keywords : Anal diseases; Hemorrhoids; Anal fissure; Perianal abscess; Fistula - in - ano

: ; ; ; ;

가

가

가

가

가

S

1.

1)

- : 가,
- : ?

- : 가 가? 가

- : (가)
- : (가)

2)

- 가?
- 가? 가?
- 가 가?

- 가?

- 가?

3)

- 가? 가?

4)

- : 가? 가? 가
- : 가? 가?
- : 가? 가?

5)

- : ? ?
- : ? ?
- : 가?

6)

- : ? ? . ?

- :

가?

- : 가?

7)

- ? 가 가? 가
- 가? 가?
- 가? 가?

8)

- ? 가 가?

9)

- (, ,)

10)

- (kg?)

11)

- (,)

12)

- , ,
- , 가 , ,

2.

(1)

tomy position)

(Sims) (litho-

.

가

.

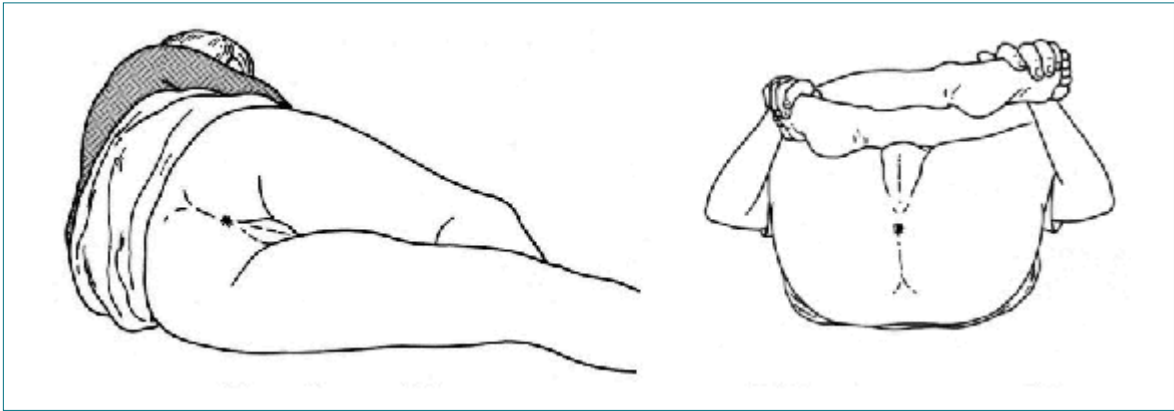
가

가

.

3.

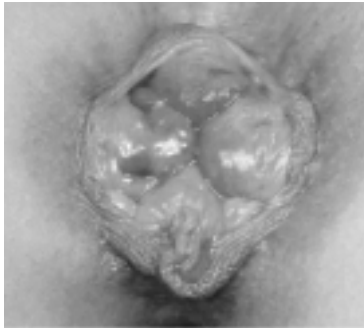• , ,



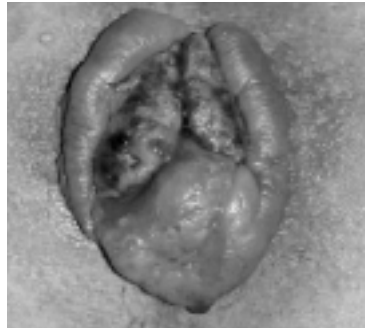
) Sims)

1.

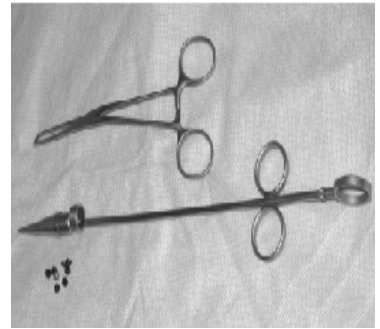
가
4.
가
1/3 가
5.
가
가
가



2.



3.



4.

1.

4

가

(1).

1

2

3

3

4

(40~42 ℃)

10~15

1)

1 4~6

가

가

가

(2).

1 2

(

4),

,

,

, Ultroid, Bi-

polar diathermy,

3

(3).

4

1

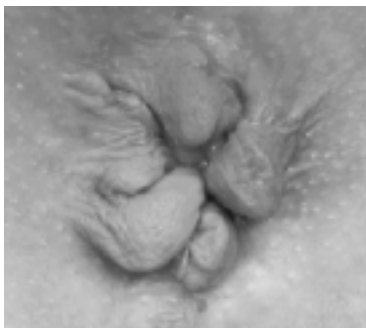, 2

가

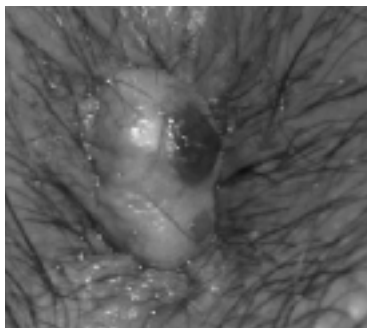, 3

(2).

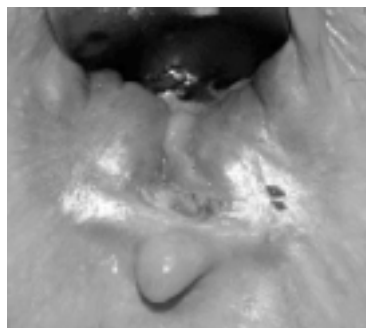
가 가



5.



6.



7.

가

가

1~2

가

2) (5)

90% (6)
10% (12)

가

가

2~3

가

가

가

(6).

가

(9).

가

(skin tag)

가

(7).

glyceryl trinitrate

2.

가

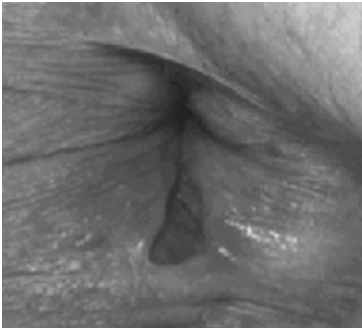가

(8)

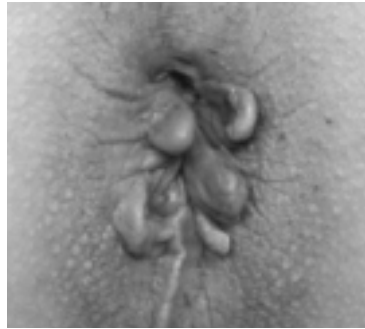가

NO

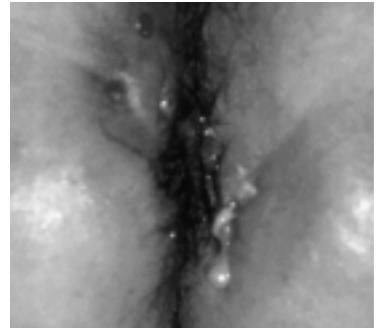
glyceryl



8.



9.



10.

trinitrate, isosorbide dinitrate,
botulinum ,
diltiazem, nife-
dipine
(3).

3.

diltiazem, nife-

가

가

(seton)

(4),

(5)

(10).

가

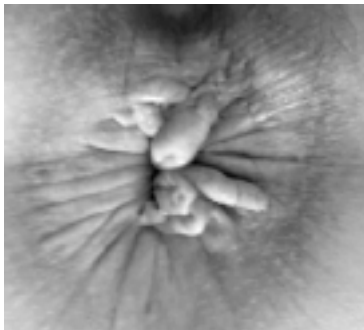가

Hanley

(6)

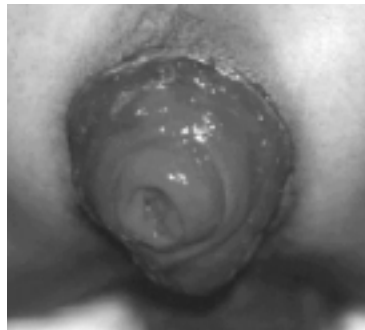(7)

가



11.

가



12.

가

가

4.

가

(11).

가

5



1. Thomson WHF. The nature of hemorrhoids. Br J Surg 1975 ; 62 : 542 - 52
2. , 30 , 2002 : 11 - 6
3. SR Brown, A Taylor, IJ Adam, AJ Shorthouse. The management of persistent and recurrent chronic anal fissures. Colorectal Dis 2002 ; 4 : 226 - 32
4. Lewis P, Bartolo DCC. Treatment of transsphincteric fistulae by full thickness anorectal advancement flaps. Br J Surg 1990 ; 77 : 1187 - 9
5. Amin SN, Tierney GM, Lund JN, Armitage NC. V - Y advancement flap for treatment of fistula in - ano. Dis Colon Rectum 2003 ; 46 : 540 - 3
6. Hanley PH. Conservative surgical correction of horseshoe abscess and fistula. Dis Colon Rectum 1965 ; 8 : 364 - 8
7. Junichi Iwadare. Sphincter - Preserving Techniques for Anal Fistulas in Japan. Dis Colon Rectum 2000 ; 43(Suppl) : S69 - S77

5.

(12).

()