

* 2001

17 (12-46)
40 (19-68) , 27 , 6
가 25 (75%) 가
5 (15%), 3 (9%)
17 (6-76)
Winguist-Hansen 19)
1 2 (6%), 2 8 (24%), 3 6
(18%), 4 15 (45%) , 1
2
Weber Brunner 16)
10 (30%), 21 (64%),
2 (6%), 5
(23%)
7 , 1 . 1
가
11 , 19
33 , 5 , 1 , 4 2 , 2
3

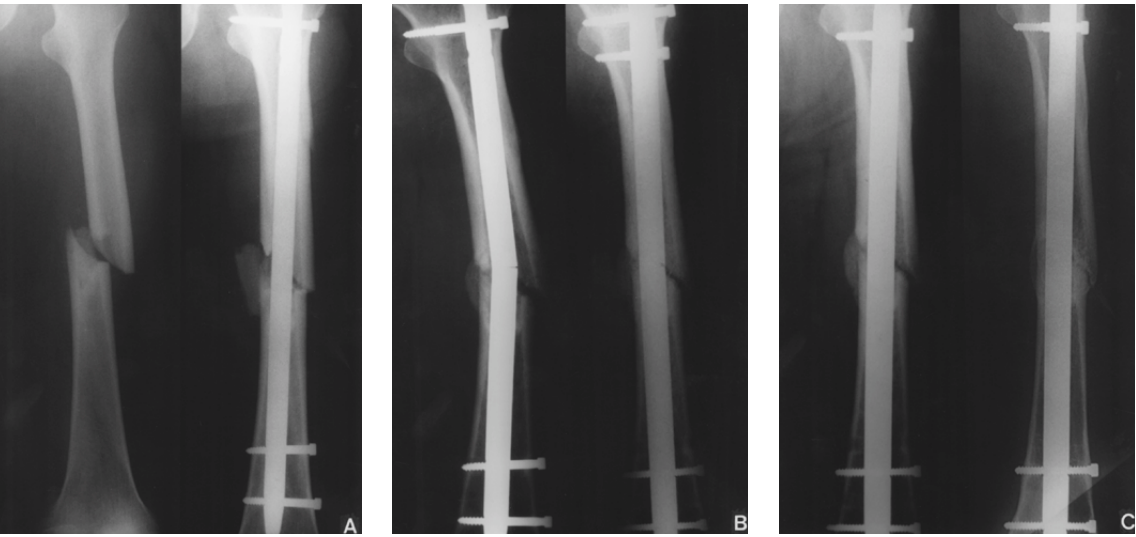


Fig. 1-A : The preoperative roentgenogram of 58-year-old man shows Winguist-Hansen type II femoral shaft fracture (Lt), and the postoperative roentgenogram shows medial fracture gap with displaced fracture fragment(Rt).
1-B : The 12 months follow-up radiograph shows breakage of nail with varus angulation of fracture(Lt), and the nonunion was managed with larger nail exchange without bone graft(Rt).
1-C : The 6 months(Lt) and 12 months(Rt) follow up radiograph after larger nail exchange shows complete union.

가 , , 19 (14-31),
20 (17-26),
16 (14-24),
15 (11-20)

11 (33%),
가 7 (21%), 5 (15%), , 3
3 (9%),
가 7 (21%) .

(Fig. 1),

1,2,5,6,11,14,16,19)
(Fig. 2). 18) 0.9% 1984 Winquist
1988 Brumback 2) 2%

(Fig. 3).

가 , Kempf 6)
17 (12-28), 10%

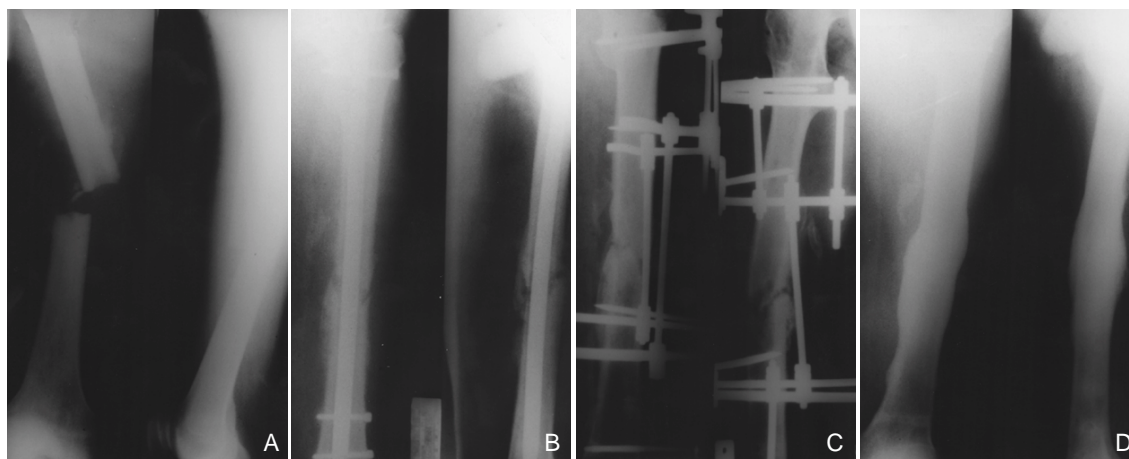


Fig. 2-A : The preoperative radiograph of 41-year-old man shows transverse femoral shaft fracture.
2-B : The 11 months follow up radiograph after interlocking IM nailing shows diffuse periosteal reaction through the entire shaft and bony resorption at fracture end.
2-C : The postoperative radiograph shows removal of nail and change to external fixation with Ilizarov.
2-D : The 18 months follow-up radiograph after external fixation shows complete union without any evidence of infection.

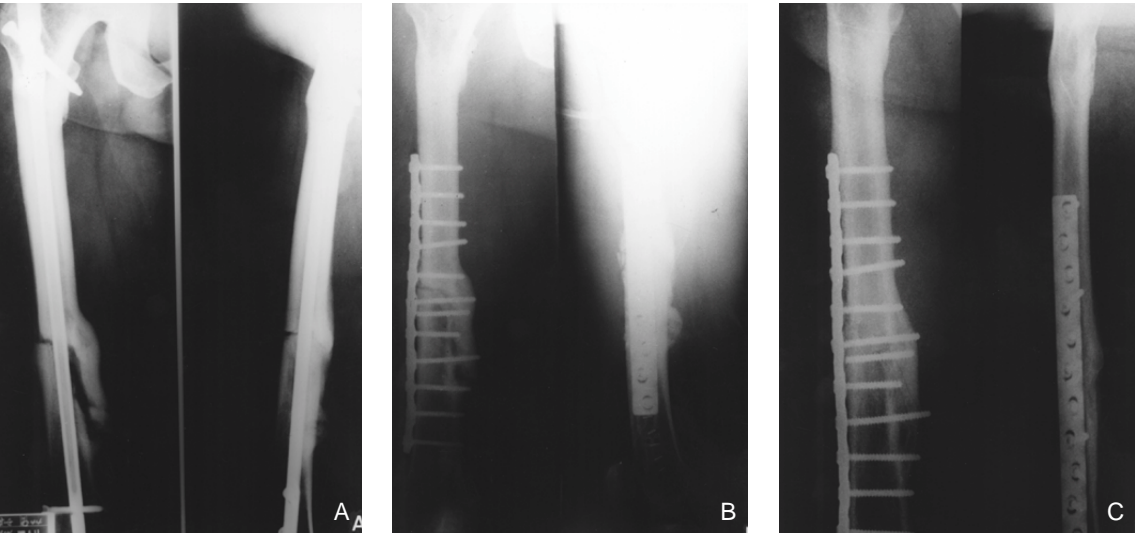


Fig. 3-A : The preoperative radiograph of 48 year-old man with nonunion of femoral shaft fracture shows incompletely united fracture fragment and large fracture gap.
3-B : The postoperative radiograph after osteosynthesis with compression plate and bone grafting shows obliteration of fracture gap.
3-C : The 18 months follow up radiograph shows complete union.

20,21)

Polter

12), 가

8,15)

3,4,7,8,9,12,16),

가

가

가

가

가

13) 100%

18) 53%

가

가7 ,

가 11

19 17

가

REFERENCES

1. **Brumback RJ, Reilly JP, Poka A, Lakatos RP, Bathon H and Burgess AR** : Intramedullary nailing of femoral shaft fractures. Part I. Decision-making errors with interlocking fixation. J Bone Joint Surg, 70A:1441-1452, 1988.
2. **Brumback RJ, Uwagie-Ero S, Lakatos RP, Poka A, Bathon GH and Burgess AR** : Intramedullary nailing of femoral shaft fractures. Part II. Fracture healing with static interlocking fixation. J Bone Joint Surg, 70A:1453-1462, 1988.
3. **Cove JA, Lhowe DW, Jupiter LB and Siliski JM** : The management of femoral diaphyseal nonunion. J Orthop Trauma, 11:513-520, 1997.
4. **Hak DJ, Lee SS and Goulet JA** : Success of exchange reamed intramedullary nailing for femoral shaft nonunion or delayed union. J Orthop Trauma, 14:178-182, 2000.
5. **Hanks GA, Foster WC and Cardea JA** : Treatment of femoral shaft fractures with the Brooker-Wills interlocking intramedullary nail. Clin Orthop, 226:226-218, 1988.
6. **Kempf I, Grosse A and Beck GF** : Closed locked intramedullary nailing. Its application to comminuted fractures of the femur. J Bone Joint Surg, 67A:709-720, 1985.
7. **Kempf I, Grosse A and Rigaut P** : The treatment of noninfected pseudoarthrosis of the femur and tibia with locked intramedullary nailing. Clin Orthop, 212:142-154, 1986.
8. **Kim KS, Kim JO, Jung HG and Jung BO** : Plate augmentation for the nonunion of femur shaft fractures after interlocking intramedullary nail fixation. J Korean Society of Fractures, 12:21-27, 1999.
9. **Klemm KW** : Treatment of infected pseudoarthrosis of the femur and tibia with an interlocking nail. Clin Orthop, 212:174-181, 1986.
10. **Kuntscher G** : Intramedullary surgical technique and its place in orthopaedic surgery. J Bone Joint Surg, 47A: 809-818, 1965.
11. **Lee KB, Jung ST, Moon ES, Song EK and Jeong KC** : Usefulness of interlocking compression nail in treatment of femoral shaft stable fracture. J Korean Society of Fractures, 14:601-608, 2001.
12. **Lee SC and Song MH** : Nonunion of the fracture of distal one-third of femoral shaft treated by interlocking intramedullary nailing. J Korean Society of Fractures, 12:259-266, 1999.
13. **Oh I, Nahigian SH, Rascher JJ and Farkall JP** : Closed intramedullary nailing for ununited femoral shaft fractures. Clin Orthop, 106:206-215, 1975.

-
14. **Rothwell AG and Fitzpatrick CB** : Closed Küntscher nailing of femoral shaft fractures: a series of 100 consecutive patients. *J Bone Joint Surg*, 60B:504-509, 1978.
 15. **Ueng SWN, Chao EK, Lee SS and Shih CH** : Augmentative plate fixation for the management of femoral nonunion after intramedullary nailing. *J Trauma*, 43:640-644, 1995.
 16. **Weber BG and Brunner C** : The treatment of nonunion without electrical stimulation. *Clin Orthop*, 161:24-32, 1981.
 17. **Webb LX, Winkquist RA and Hansen ST** : Intramedullary nailing and reaming for delayed union or nonunion of the femoral shaft. *Clin Orthop*, 212:133-141, 1986.
 18. **Weresh MJ, Hakanson R, Stover M, Sims SH, Kellam JF and Bosse MJ** : Failure of exchange reamed intramedullary nails for ununited femoral shaft fractures. *J Orthop Trauma*, 14:335-338, 2000.
 19. **Winkquist RA, Hansen ST and Clawson DK** : Closed intramedullary nailing of femoral fractures. *J Bone Joint Surg*, 66A:529-539, 1984.
 20. **Wu CC** : The effect of dynamization on slowing the healing of femur shaft fractures after interlocking nailing. *J Trauma*, 43:263-267, 1997.
 21. **Wu CC and Chen WJ** : The treatment of femoral shaft aseptic nonunion: comparison between closed and open bone-grafting techniques. *J Trauma*, 43:112-116, 1997.

Abstract

Treatment of the Nonunion of Femur Shaft Fractures after Interlocking Intramedullary Nailing

Keun-Bae Lee, M.D., Eun-Sun Moon, M.D., Eun-Kyoo Song, M.D.,
Jin Choi, M.D., Sung-Taek Jung, M.D.

Department of Orthopedics, Chonnam National University Hospital, Gwangju, Korea

Purpose : We analyzed the results of treatment for the nonunion of femur shaft fractures after interlocking intramedullary(IM) nail fixation.

Materials & Methods : Thirty-three patients who underwent interlocking IM nailing due to femur shaft fractures from May, 1990 to July, 2000 and followed up for more than one year were evaluated retrospectively. Mean age at the time of operation was 40 years(Range, 19-68). 27 cases were men and 6 cases were women. By Weber and Brunner classification of the nonunion, hypervascular type were 10 cases(30%), avascular type 21cases(64%), mixed type 2 cases(6%). Infected type among the avascular type of nonunion were 5 cases(23%). Results were evaluated with bone union by treatment methods and complications.

Results : According to the causes and types of nonunion, we performed IM nail exchange in seven cases, IM nail exchange and bone grafting in eleven cases, external fixation in five cases, compression plating and bone grafting in three cases, and only cancellous bone grafting in seven cases. Radiographical union was achieved in 19 weeks, 17 weeks, 20 weeks, 16 weeks and 15 weeks respectively. There's no statistically significant difference between treatment methods. There are no cases of nonunion, malunion and infection.

Conclusion : The selection of appropriate treatment method by the cause and type of each nonunion is very important to achieve the bony union in the treatment for the nonunion of femur shaft fractures after interlocking intramedullary nailing.

Key Words : Femur shaft fracture, Nonunion, Interlocking intramedullary nailing