



iMRI

Investigative
Magnetic
Resonance
Imaging

Case Report

Received: May 26, 2015
Revised: June 18, 2015
Accepted: July 2, 2015

Correspondence to:

Dan B. Karki, M.D.
Department of Radio-diagnosis,
Patan Academy of Health
Sciences, Patan, Nepal.
Tel. +977-01-4720803
Fax. +977-9851102948
Email: kedibi@yahoo.com

This is an Open Access article distributed under the terms of the Creative Commons Attribution Non-Commercial License (<http://creativecommons.org/licenses/by-nc/3.0/>) which permits unrestricted non-commercial use, distribution, and reproduction in any medium, provided the original work is properly cited.

Copyright © 2015 Korean Society of Magnetic Resonance in Medicine (KSMRM)

Tumor-like Presentation of Tubercular Brain Abscess: Case Report

Dan B. Karki¹, Ghanashyam Gurung², Mohan R. Sharma³, Ram K. Shrestha³, Gita Sayami⁴, Gopal Sedain³, Amina Shrestha⁵, Ram K. Ghimire²

¹Department of Radio-diagnosis, Patan Academy of Health Sciences, Patan, Nepal

²Department of Radio-diagnosis, Tribhuvan University Teaching Hospital, Kathmandu, Nepal

³Department of Neurosurgery, Tribhuvan University Teaching Hospital, Kathmandu, Nepal

⁴Department of Pathology, Tribhuvan University Teaching Hospital, Kathmandu, Nepal

⁵Department of Neurology, National Academy of Medical Sciences, Bir Hospital, Kathmandu, Nepal

A 17-year-old girl presented with complaints of headache and decreasing vision of one month's duration, without any history of fever, weight loss, or any evidence of an immuno-compromised state. Her neurological examination was normal, except for papilledema. Laboratory investigations were within normal limits, except for a slightly increased Erythrocyte Sedimentation Rate (ESR). Non-contrast computerized tomography of her head revealed complex mass in left frontal lobe with a concentric, slightly hyperdense, thickened wall, and moderate perilesional edema with mass effect. Differential diagnoses considered in this case were pilocytic astrocytoma, metastasis and abscess. Magnetic resonance imaging (MRI) obtained in 3.0 Tesla (3.0T) scanner revealed a lobulated outline cystic mass in the left frontal lobe with two concentric layers of T2 hypointense wall, with T2 hyperintensity between the concentric ring. Moderate perilesional edema and mass effect were seen. Post gadolinium study showed a markedly enhancing irregular wall with some enhancing nodular solid component. No restricted diffusion was seen in this mass in diffusion weighted imaging (DWI). Magnetic resonance spectroscopy (MRS) showed increased lactate and lipid peaks in the central part of this mass, although some areas at the wall and perilesional T2 hyperintensity showed an increased choline peak without significant decrease in N-acetylaspartate (NAA) level. Arterial spin labelling (ASL) and dynamic susceptibility contrast (DSC) enhanced perfusion study showed decrease in relative cerebral blood volume at this region. These features in MRI were suggestive of brain abscess. The patient underwent craniotomy with excision of a grayish nodular lesion. Abundant acid fast bacilli (AFB) in acid fast staining, and epithelioid cell granulomas, caseation necrosis and Langhans giant cells in histopathology, were conclusive of tubercular abscess. Tubercular brain abscess is a rare manifestation that simulates malignancy and cause diagnostic dilemma. MRI along with MRS and magnetic resonance perfusion studies, are powerful tools to differentiate lesions in such equivocal cases.

Keywords: Brain abscess; Magnetic resonance imaging; Diffusion weighted imaging; Magnetic resonance spectroscopy; Perfusion imaging

INTRODUCTION

Tuberculosis is a common disease in Nepal. Approximately 40,000 people get

tuberculosis and 20,000 get new sputum positive cases every year. 5000–7000 people die each year from tuberculosis (1). Central nervous system (CNS), one of the most devastating clinical manifestations of tuberculosis is noted in 5 to 10% of extrapulmonary tuberculosis cases, and accounts for approximately 1% of all TB cases (2).

CNS tuberculosis manifests as meningitis, tuberculoma or tubercular abscess. Tubercular abscess rarely occurs in the brain, and presents with various clinical features. Diagnosis is usually made by computerized tomography (CT) or magnetic resonance imaging (MRI) scans. MRI is the choice of investigation because of its multiple parameters of evaluation, e.g. conventional imaging (T1, T2 weighted imaging, fluid attenuated recovery [FLAIR]), diffusion weighted imaging (DWI), proton magnetic resonance spectroscopy (MRS), arterial spin labeling (ASL) or dynamic susceptibility contrast (DSC) perfusion study (3–5). Newer imaging parameters in MRI have greatly increased its sensitivity and specificity. Here we report a case of tubercular abscess presented with decreased vision. MRI has played a key role in its diagnosis, although the final diagnosis was established by acid fast bacilli (AFB) staining of abscess material and histopathology of the excised specimen.

CASE REPORT

A 17-year-old female patient presented with complaints of headache and gradually decreasing vision since one month. She gave no history of fever or recent weight loss. There was no evidence of an immuno-compromised state. Also, there was no history of loss of consciousness or weakness of limbs. On examination, she was alert, oriented with a Glasgow Coma Scale of 15/15. Except for papilledema she had a normal neurological examination.

She underwent laboratory and imaging studies. Hematological studies were within normal limits except for slightly increased ESR (24 mm in the first hour). Non-contrast CT scan (Fig. 1a) of her head revealed an irregular cystic mass with concentric, slightly thickened wall, in the left frontal lobe. Moderate perilesional edema was noted. Mass effect was evident by effacement of adjacent sulci, left lateral ventricle and slight midline shift towards left side. Differential diagnosis considered in this non-contrast CT scans were pilocytic astrocytoma, metastasis and abscess.

An MRI of her head was done in Philips Ingenia 3.0T

scanner. Routine imaging studies included fast spin echo T1 (Fig. 1b) and T2 (Fig. 1c) weighted images, and FLAIR (Fig. 1d). Thereafter, DWI, MRS and DSC perfusion studies were performed. *In vivo*, MRS was accomplished using the water suppressed multi voxel spin echo sequences with long TE (144 ms) technique. It showed an outline of a lobulated mass in the anterior aspect of the left frontal lobe, which displayed a concentric hypo intense wall in T2 weighted images and iso-signal intensity in T1 weighted images. Alternating hypointense areas were noted between the wall in T1, and high signal intensity in T2 weighted images. Marked T2 hyperintensity was evident around this mass, representing moderate perilesional edema. In addition, a significant mass effect was also seen. FLAIR axial image displayed an irregular concentric hypointense wall having perilesional hyperintensity. Post Gadolinium study (Fig. 1e, f) showed two slightly irregular wall, markedly enhancing walls with some nodular solid enhancing component in the anterior aspect.

No restricted diffusion was seen within this mass in DWI (Fig. 1g, h). Apart from the changes noted above, rest of the brain showed normal morphology with normal parenchymal signal intensity. Posterior cranial fossa structures were normal. The most likely diagnosis considered was glioma/metastasis. However, the hypointense rings in the T2 sequence made inflammatory lesion an equally likely diagnosis.

Thereafter, newer sequences were done for further evaluation of this lesion. MRS showed increased lactate and lipid peaks in the central part of this mass (Fig. 2). Few areas at the periphery of the mass showed increased choline peak without significant decrease in NAA level.

ASL (Fig. 1i) before DSC perfusion study showed decreased relative cerebral blood volume (rCBV) in this region. DSC perfusion study also showed decreased rCBV in the center, and no increased rCBV was seen in the region of wall (Fig. 1j). These features in MRS, ASL and Perfusion imaging, combined with conventional MRI features, suggested a brain abscess, most probably of tubercular origin.

The patient underwent a craniotomy and complete excision of the lesion. Intra-operatively, an organized capsulated mass having a central necrotic and purulent area, was seen (Fig. 3a). She tolerated the surgery well and was discharged from the hospital on 7th postoperative day, in stable condition.

AFB staining of material from the mass showed abundant staining of AFB (+++). Histopathological examination of the specimen showed discrete to confluent epithelioid cell

granulomas with extensive caseation necrosis and Langhans giant cells (Fig. 3b). No glial tissue was evident. Thus, the final diagnosis of tubercular abscess of left frontal lobe was confirmed, and the patient was started on anti-tubercular treatment.

DISCUSSION AND CONCLUSION

CNS tuberculosis is not an uncommon extra-pulmonary manifestation of tuberculosis. In brain, it usually manifests as meningitis and tubercular granuloma (tuberculoma). Tuberculoma often shows a ring enhancing lesion with perilesional edema in CT and MRI (6, 7). This lesion could be treated by anti-tubercular therapy. Tubercular abscess

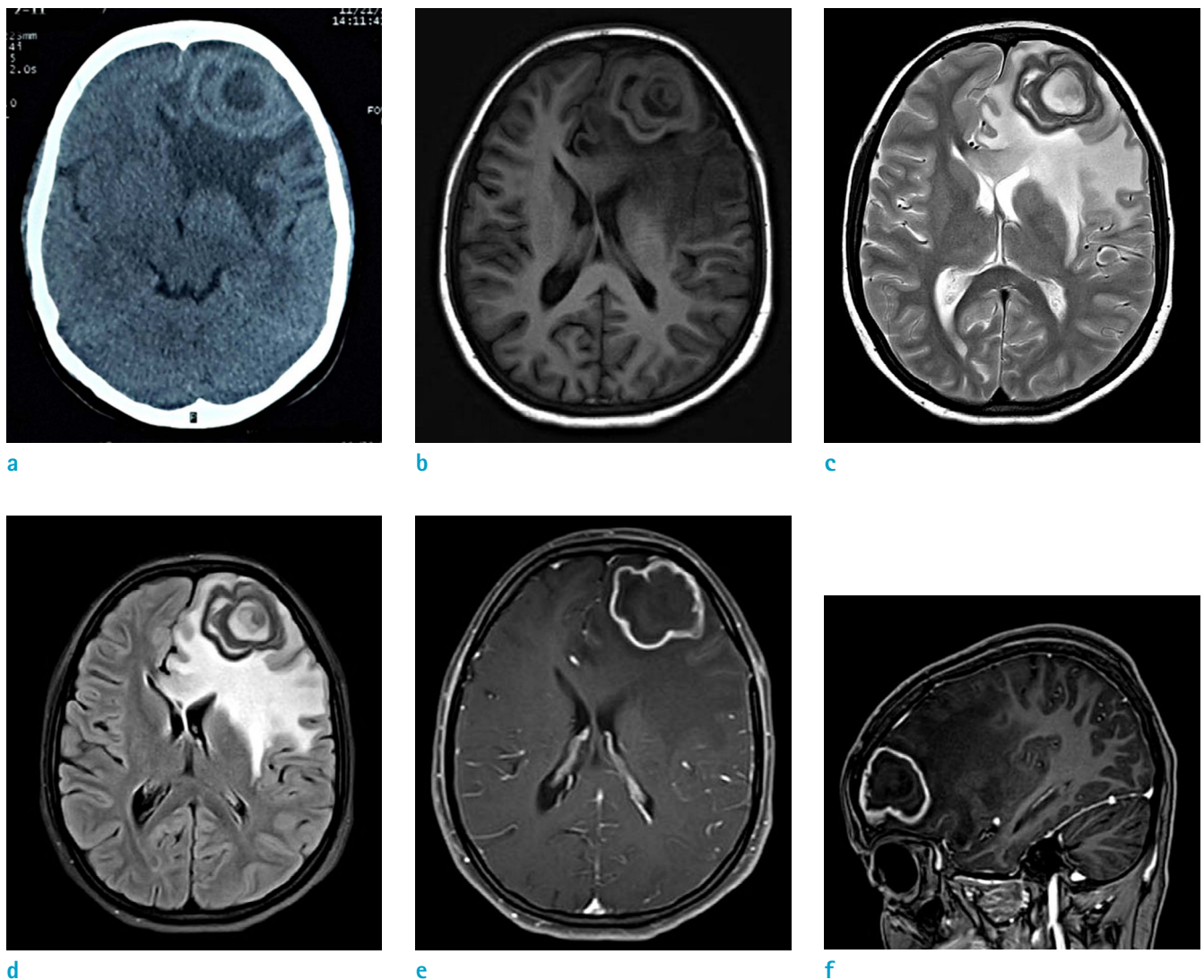


Fig. 1. (a) Non-contrast CT scan of head revealed an irregular cystic mass with concentric slightly thick wall in the left frontal lobe with moderate perilesional edema and mass effect. (b, c) T1 weighted axial (b) and T2 weighted axial (c) delineate lobulated outline mass in left frontal lobe in anterior aspect which displayed two concentric hypointense wall in T2 and iso-signal intensity in T1. Alternating hypointense areas were noted between the wall in T1 and high signal intensity in T2 weighted images. Moderate perilesional edema with mass effect also noted. (d) FLAIR axial showed two irregular concentric hypointense wall with in between and perilesional hyperintensity. (e, f) Post contrast T1 axial (e) and post contrast T1 sagittal (f) studies showed markedly enhancing two slightly irregular wall with some nodular solid enhancing component in the anterior aspect.

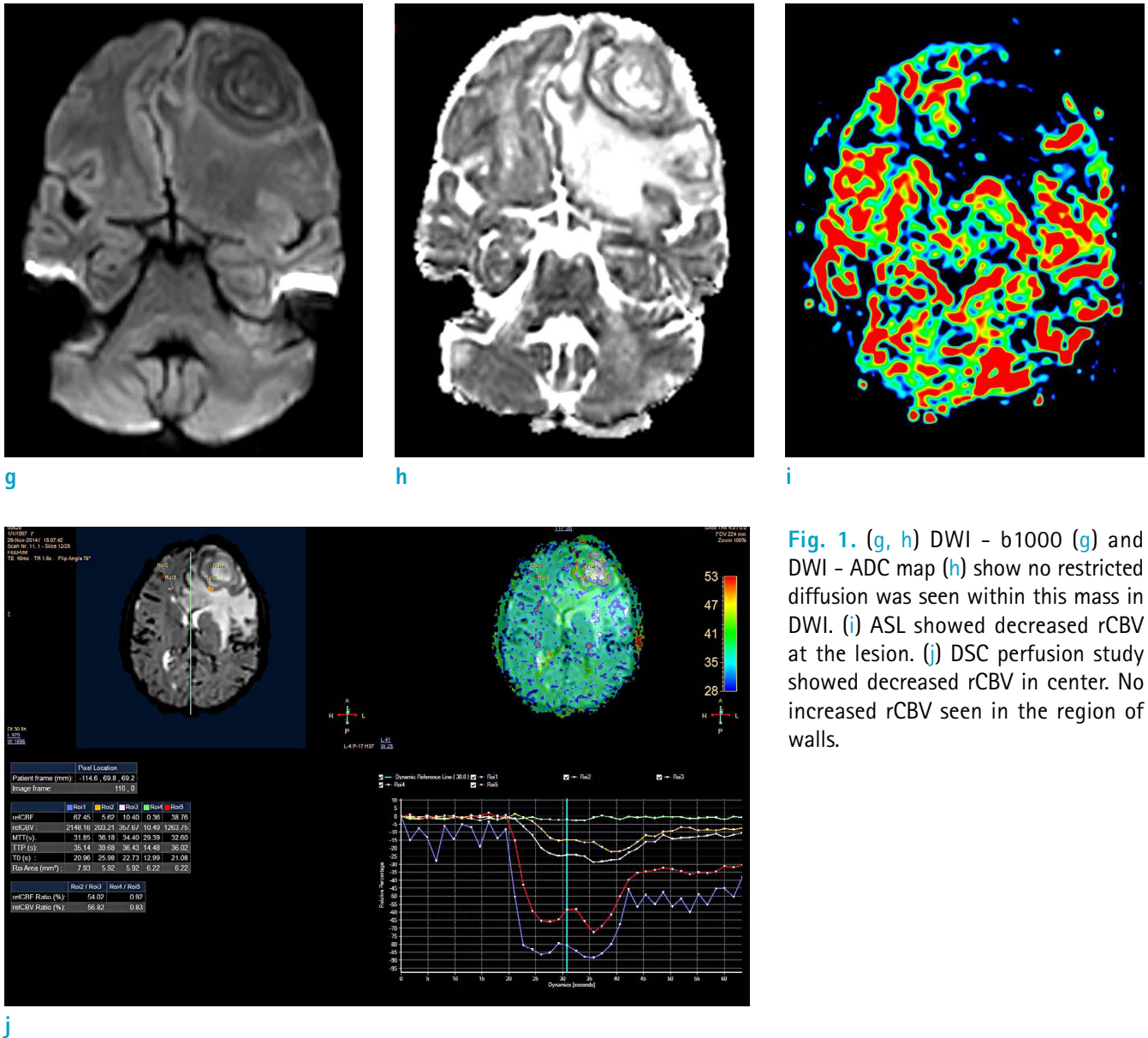


Fig. 1. (g, h) DWI - b1000 (g) and DWI - ADC map (h) show no restricted diffusion was seen within this mass in DWI. (i) ASL showed decreased rCBV at the lesion. (j) DSC perfusion study showed decreased rCBV in center. No increased rCBV seen in the region of walls.

formation can occur in brain, where it simulates a mass and cause mass effect (8, 9). It can mimic other intra-axial masses like glioma, metastasis etc. CT scan is unable to differentiate it from other masses. MRI is the choice of investigation in this case. DWI is a good imaging sequence for differentiating abscess from other masses. Restricted diffusion, with high signal intensity in DWI and low ADC values, is seen in both tubercular and pyogenic brain abscess. However, no restricted diffusion was seen in this case, thus making the diagnosis a bit confusing (10-12). The patient was on a corticosteroid regime. This medication, and an organized abscess cavity, may be the possible cause

for no restricted diffusion in DWI. The MRS is another important tool in MRI which can differentiate abscess from malignant lesions. It showed lipid/ lactate peaks, and loss of choline and NAA peaks in the wall and in the perilesional edema (10, 11). However, in our case, there was increased choline without a significant loss of NAA in some peripheral areas. This gave a doubtful impression of the possibility of malignancy.

MR perfusion scan demonstrates the degree of angiogenesis of the lesions and is thus useful in the differentiation between neoplastic and infectious lesions. It is also used to differentiate between tumoral recurrence and radionecrosis

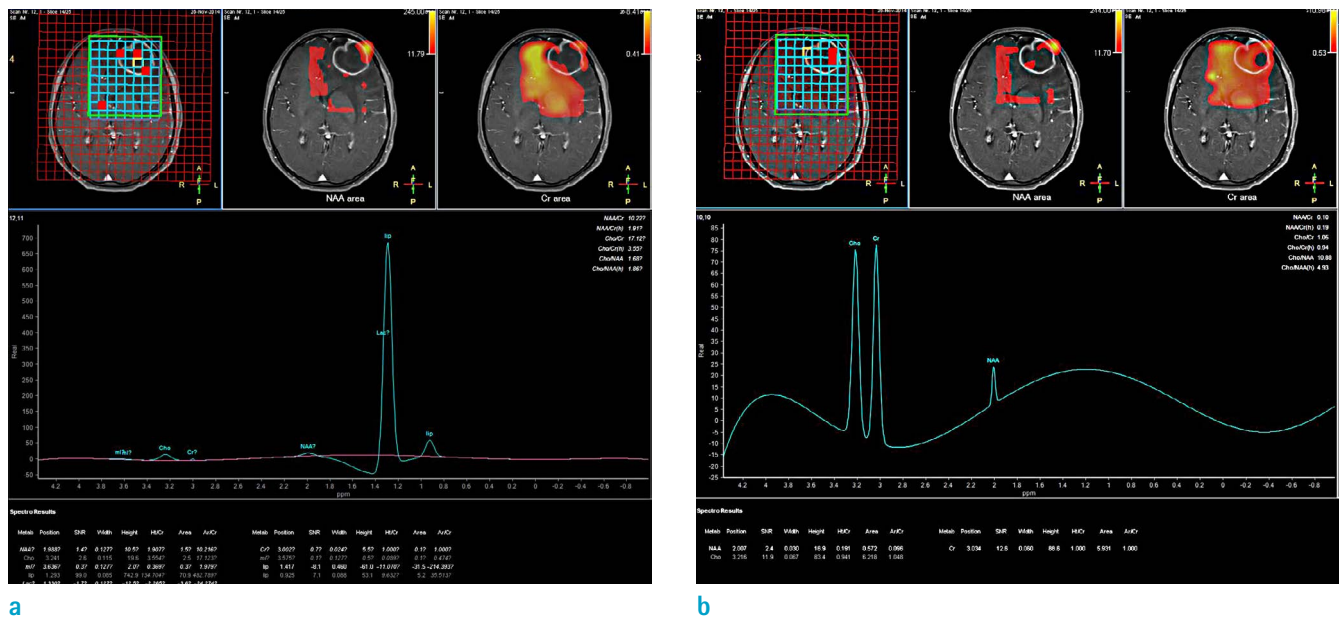


Fig. 2. (a, b) MRS displayed increase in lactate and lipid peaks at the central part of the mass. Few areas at the periphery of the mass shows increased choline peak without significant decrease in NAA level.

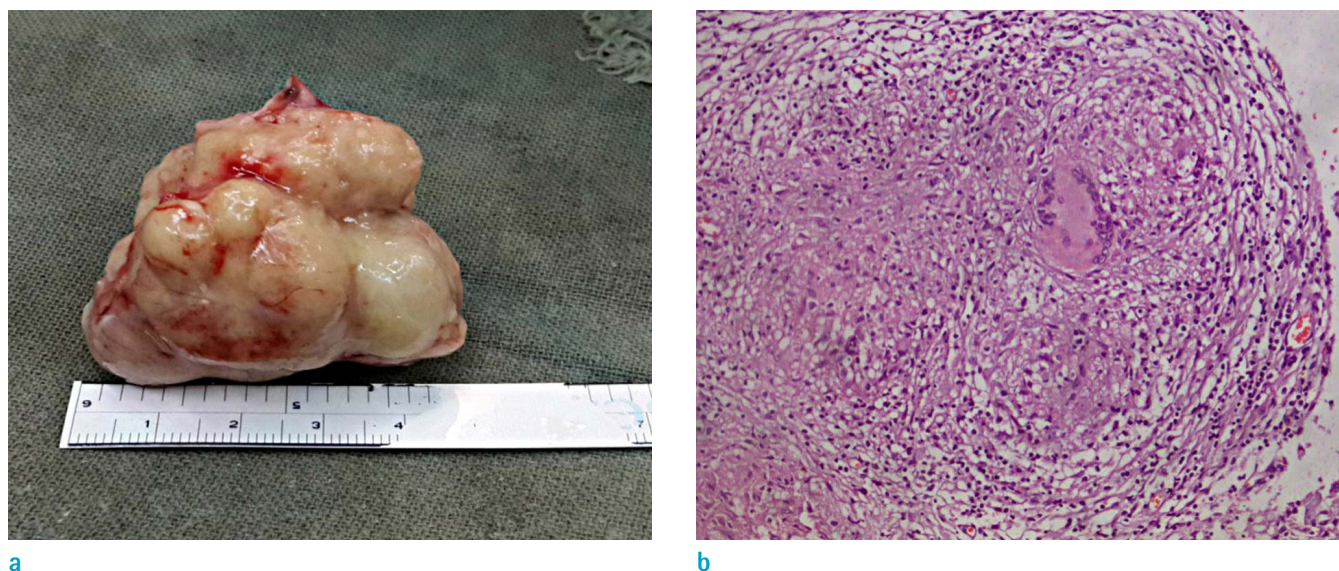


Fig. 3. (a) Excised organized capsulated mass of the lesion. (b) Histopathology showing discrete to confluent epithelioid cell granulomas with extensive caseation necrosis and Langhans giant cells.

in the post treatment follow up. It can be performed in high field MRI by ASL or DSC perfusion study. ASL has emerged as a new tool in MRI, which can show the relative cerebral blood volume in the lesion without MR contrast. It had clearly shown the decreased rCBV in our case. We had to resort to MR contrast in DSC perfusion study. Only then could it delineate relative cerebral blood volume in the

lesion (13-15). In our patient, DSC perfusion study resulted in beautifully displaying the significantly decreased rCBV.

Imaging features in non-contrast CT suggest the differential diagnosis of cystic malignant lesion or abscess. However, considering all the features in MRS, ASL and DSC perfusion studies combined, we could conclude a diagnosis of an abscess. Furthermore, the morphological features

of concentric wall and MR features of T2 hypointensity suggested the diagnosis of a tubercular abscess.

REFERENCES

1. National Tuberculosis Center. TB Burden in Nepal. Ministry of Health & Population, 2013. <http://www.nepalntp.gov.np/>. Accessed March 8, 2015
2. Cherian A, Thomas SV. Central nervous system tuberculosis. *Afr Health Sci* 2011;11:116-127
3. Jinkins JR, Gupta R, Chang KH, Rodriguez-Carbajal J. MR imaging of central nervous system tuberculosis. *Radiol Clin North Am* 1995;33:771-786
4. Trivedi R, Saksena S, Gupta RK. Magnetic resonance imaging in central nervous system tuberculosis. *Indian J Radiol Imaging* 2009;19:256-265
5. Bathla G, Khandelwal G, Maller VG, Gupta A. Manifestations of cerebral tuberculosis. *Singapore Med J* 2011;52:124-130; quiz 131
6. Kastrup O, Wanke I, Maschke M. Neuroimaging of infections. *NeuroRx* 2005;2:324-332
7. Hansman Whiteman ML, Bowen BC, Donovan Post MJ, Bell MD. Intracranial infection. In: Atlas SW, ed. *Magnetic resonance imaging of the brain and spine*. 3rd ed. Philadelphia: Lippincott Williams & Wilkins, 2002:1099-1175
8. Desprechins B, Stadnik T, Koerts G, Shabana W, Breucq C, Osteaux M. Use of diffusion-weighted MR imaging in differential diagnosis between intracerebral necrotic tumors and cerebral abscesses. *AJNR Am J Neuroradiol* 1999;20:1252-1257
9. Holmes TM, Petrella JR, Provenzale JM. Distinction between cerebral abscesses and high-grade neoplasms by dynamic susceptibility contrast perfusion MRI. *AJR Am J Roentgenol* 2004;183:1247-1252
10. Luthra G, Parihar A, Nath K, et al. Comparative evaluation of fungal, tubercular, and pyogenic brain abscesses with conventional and diffusion MR imaging and proton MR spectroscopy. *AJNR Am J Neuroradiol* 2007;28:1332-1338
11. Mishra AM, Gupta RK, Jaggi RS, et al. Role of diffusion-weighted imaging and *in vivo* proton magnetic resonance spectroscopy in the differential diagnosis of ring-enhancing intracranial cystic mass lesions. *J Comput Assist Tomogr* 2004;28:540-547
12. Mishra AM, Gupta RK, Saksena S, et al. Biological correlates of diffusivity in brain abscess. *Magn Reson Med* 2005;54:878-885
13. Floriano VH, Ferraz-Filho JRL, Ronaldo Spotti A, Tognola WA. Perfusion-weighted magnetic resonance imaging in the evaluation of focal neoplastic and infectious brain lesions. *Rev Bras Neurol* 2010;46:29-36
14. Essig M, Nguyen TB, Shiroishi MS, et al. Perfusion MRI: the five most frequently asked clinical questions. *AJR Am J Roentgenol* 2013;201:W495-510
15. Detre JA, Rao H, Wang DJ, Chen YF, Wang Z. Applications of arterial spin labeled MRI in the brain. *J Magn Reson Imaging* 2012;35:1026-1037