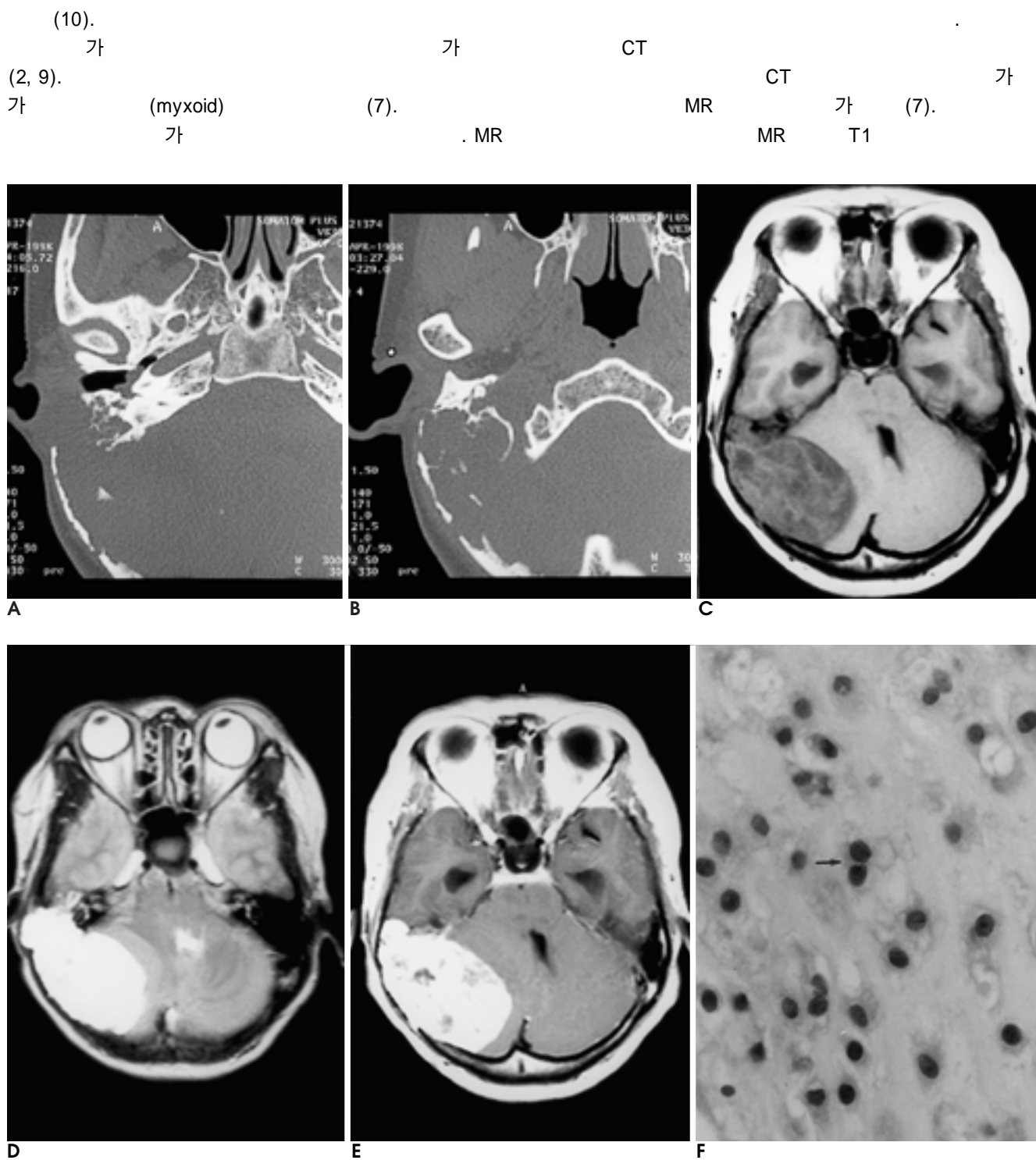


jugulare tumor), (glomus  
50 1

(1). 0.16% (2). 가 (3). 50%  
(3). 5 - 12%  
(1, 4, 5). 40  
(2). (1, 6),

(1, 2, 7). 가  
15% 가 (2).  
50 가 7 , 4 (conventional),  
CT MR CT (mesenchymal), (dedifferentiated) 가  
(Fig. 1A, B). T1 MR 가  
(Fig. 1C) T2 (Fig. 1D). Gd-DTPA  
(Fig. 1E). 가 가  
(Fig. 1F). 가 (mesenchy-  
mal) marker (vimentin, S-100)  
, cytokeratin  
5'-nucleotidase (3).  
CT MR 가  
(7). 50%  
가 (8,  
(3, 8, 9). 45 - 60% 가  
9),



**Fig. 1.** 50-year-old female with myxoid chondrosarcoma.

**A, B**(below level than a). Axial temporal bone CT scans show destruction and expansion of right temporal bone without calcification.

**C.** On axial T1-weighted image, the lesion shows inhomogenous low and high signal intensities in the right temporal bone and adjacent right cerebellum is compressed.

**D.** On axial T2-weighted image, the lesion shows homogenous high signal intensity in the right temporal bone.

**E.** On contrast-enhanced T1-weighted image, the lesion shows strong enhancement.

**F.** Photomicrograph of myxoid chondrosarcoma ( $\times 400$ , Hematoxylin and Eosin): The tumor consists of cords or rows of small atypical cells separated by a abundant amount of myxochondroid stroma. Tumor cells are cuboidal or polyhedral with small round to oval nuclei and have poorly-defined lacunae, in which two cells are occasionally present (arrow). Immunohistochemically, these cells were positive for S-100 protein.

T2  
, T2  
(3). Gadolinium  
(3). T1  
가  
T2  
MR T1  
T2  
.  
1. Arlen M, Tollefsen HR, Huvos A, Marcove RC. Chondrosarcoma of the head and neck. *Am J Surg* 1970;120:456-460  
2. Coltrera MD, Googe PB, Harrist TJ, Hyams VJ, Schiller AL,

Goodman ML. Chondrosarcoma of the temporal bone: Diagnosis and treatment of 13 cases and review of literature. *Cancer* 1986;58:2689-2696  
3. Brown E, Hug EB, Weber AL. Chondrosarcoma of the skull base. *Neuroimag Clin North Am* 1994;4:3:529-541  
4. Brukey BB, Hoffman HT, Baker SR, et al. Chondrosarcoma of the head and neck. *Laryngoscope* 1990;100:1301-1305  
5. Ruark DS, Schlenhaider UK, Shah JP. Chondrosarcoma of the head and neck. *World J Surg* 1992;16:1010-1016  
6. Meyers SP, Hirsh WL, Curtin HD, et al. Chondrosarcoma of the skull base; MR imaging features. *Radiology* 1992;184:103-108  
7. Watters GW, Brookes GB. Chondrosarcoma of temporal bone. *Clin Otolaryngol* 1995;20, 53-58  
8. Bahr AL, Gayler BW. Cranial chondrosarcoma; Report of four cases and review of the literature. *Radiology* 1977;124:151-156  
9. Grossman RI, Davis KR. Cranial computed tomographic appearance of chondrosarcoma of the base of the skull. *Radiology* 1981; 141:403-408  
10. Lee YY, Van Tassel P. Craniofacial chondrosarcoma: Imaging findings in 15 untreated cases. *AJNR Am J Neuroradiol* 1989;10:165-170

J Korean Radiol Soc 2001;45:9 - 11

## Chondrosarcoma of the Temporal Bone: A Case Report<sup>1</sup>

Man Soo Park, M.D., Sang Youl Lee, M.D.<sup>2</sup>, Jaegul Chung, M.D.<sup>3</sup>, Deok Hee Lee, M.D.,  
Seung Mun Jung, M.D., Dae Sik Ryu, M.D.

<sup>1</sup>Department of Radiology, Kang Nung Hospital, Ulsan University

<sup>2</sup>Department of Neurosurgery, Kang Nung Hospital, Ulsan University

<sup>3</sup>Department of Pathology, Kang Nung Hospital, Ulsan University

Chondrosarcoma of the temporal bone is a rare lesion. Clinically it has been confused with chordoma, glomus jugulare tumor and meningioma, among other conditions, and due to its anatomic location, cranial nerve palsy is frequently observed.

We report a case involving a 50-year-old woman with chondrosarcoma of the temporal bone.

**Index words :** Temporal bone, CT  
Temporal bone, MR  
Temporal bone, neoplasms

Address reprint requests to : Man-Soo Park, M.D., Department of Radiology, Kang Nung Hospital,  
415, Bangdong-ri, Sacheon-myon, Kangnung-si, Kangwon-do, 210-850, Korea.  
Tel. 82-33-610-3481 Fax. 82-33-610-3010 E-mail: mspark@knh.co.kr