

# A Method to Prevent Life-threatening Intraperitoneal Bleeding During Transjugular Intrahepatic Portosystemic Shunt Creation<sup>1</sup>

Hun Kyu Ryeom, M.D., Yong Joo Kim, M.D.

**Purpose :** To prevent intraperitoneal bleeding, it is critical that the extrahepatic portal vein should not be punctured during transjugular intrahepatic portosystemic shunt(TIPS). There has, however, been no procedure for defining the anatomic relationship between the hepatic capsule and the portal vein segment before shunt formation. To avoid a possibly catastrophic outcome of extrahepatic portal puncture before shunt creation, we therefore devised a new method; the purpose of this study is to report its efficacy and feasibility.

**Materials and Methods :** Whenever a portal vein was punctured, we advanced a 9F sheath over a guidewire into the portal vein before balloon dilatation of the tract. Contrast material was then injected through the sheath as this was slowly withdrawn from the portal vein towards the hepatic vein. When contrast material extravasated or spilled into the peritoneal space, thus suggesting extrahepatic portal vein puncture, a more peripheral segment of the portal vein was punctured, and a shunt was created using this new tract. We applied this method to 130 consecutive patients who underwent TIPS to control variceal bleeding due to liver cirrhosis. In all cases, portography and ultrasonography were used for immediate confirmation of the procedure.

**Results :** Puncture of the extrahepatic portal vein segment occurred in three out of 130 (2.3 %) patients. In these three, TIPS was successfully created using the method described above. Clinical and ultrasonographic follow-up showed that no patients suffered intraperitoneal bleeding.

**Conclusion :** For preventing intraperitoneal hemorrhage during TIPS creation, our method is effective and feasible.

**Index words :** Shunts, portosystemic  
Hypertension, portal  
Interventional procedures, complications  
Stents and prostheses

It is critical for transjugular intrahepatic portosystemic shunt (TIPS) procedure that the punctured portal vein should be within the hepatic parenchyma ; if it is in the extraparenchymal portion, fatal intraperitoneal bleeding might occur. There has, however, been no procedure for defining the anatomic relationship between the hepatic capsule and the punctured

portal vein before the placement of a metallic stent or dilatation of the parenchymal tract. To avoid a possibly catastrophic outcome of extrahepatic portal puncture before shunt creation, we therefore devised a new method ; the purpose of this study is to determine the efficacy and feasibility of this method.

## Materials and methods

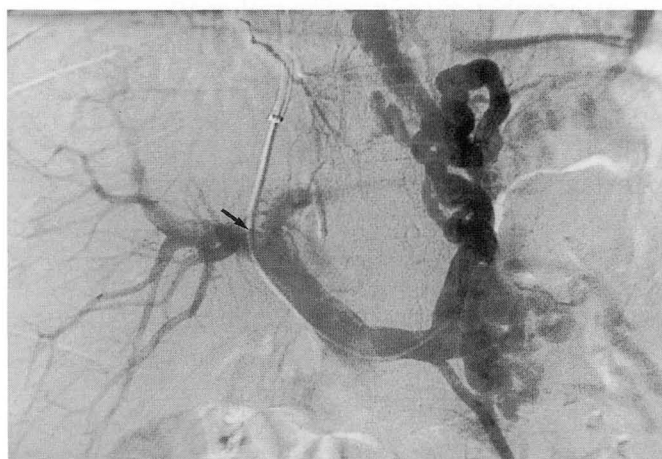One hundred and thirty consecutive patients who underwent TIPS for the control of variceal bleeding be-

<sup>1</sup>Department of Diagnostic Radiology, Kyungpook National University Hospital  
Received December 15, 1997 ; Accepted February 16, 1998  
Address reprint requests to : Hun Kyu Ryeon, M.D., Department of Diagnostic Radiology, Kyungpook National University Hospital, # 52 Sam Duk-Dong 2Ga Taegu, 700-412, Korea. Tel. 82-53-420-5396 Fax. 82-53-422-2677

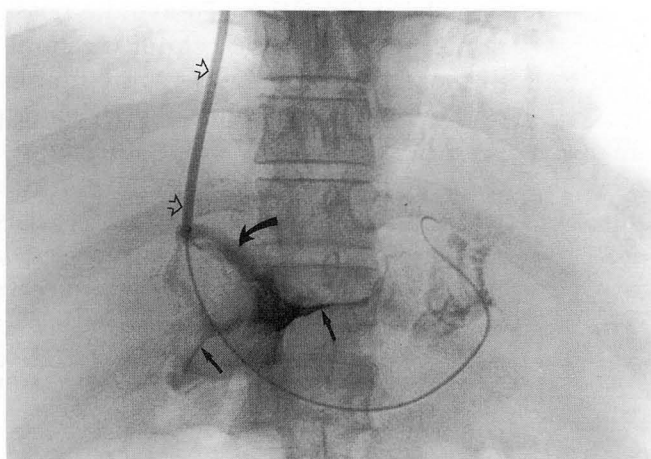
tween February 1992 and September 1997 were involved in this study. One hundred and two were men, and 28 were women; their mean age was 53 (range, 3–75) years.

Whenever a portal venous branch was punctured, a guidewire was inserted into the splenic vein and a multipurpose catheter (Cook, Bloomington, Ind.) was then passed over the wire without dilatation of the resulting parenchymal tract. To evaluate the portal venous system, a preliminary splenic portal venogram was obtained (Fig. 1A). Regardless of the distance from the portal bifurcation to the punctured portal vein, a 9F side-arm sheath (Cook, Bloomington, Ind.) containing a 9F dilator was advanced into the portal vein from

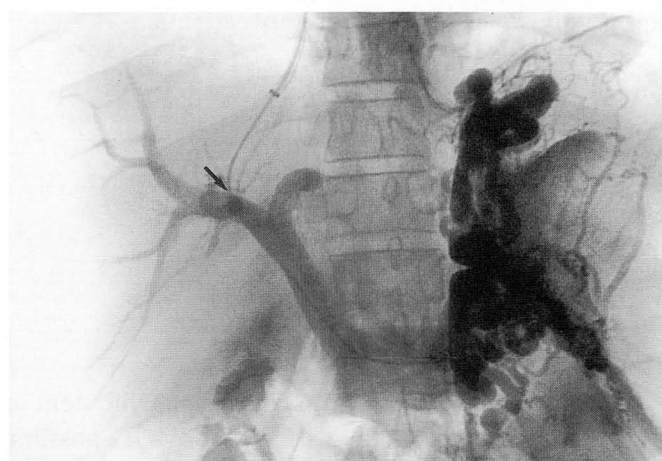
the hepatic vein. With the guidewire and the sheath still in position within the portal vein, we then removed the dilator. As the sheath was slowly withdrawn from the portal vein to the hepatic vein, contrast material was injected with a syringe attached to its side-arm. If no contrast spillage occurred, we placed a metallic stent in this tract after it was dilated with a balloon. If the peritoneal space contained contrast material, thus confirming the extrahepatic location of the punctured portal vein segment (Fig. 1B), we punctured a more peripheral portion of the portal vein from the same hepatic vein, and tested again using the same method described above (Fig. 1C). If no contrast extravasation occurred, balloon dilatation of the result-



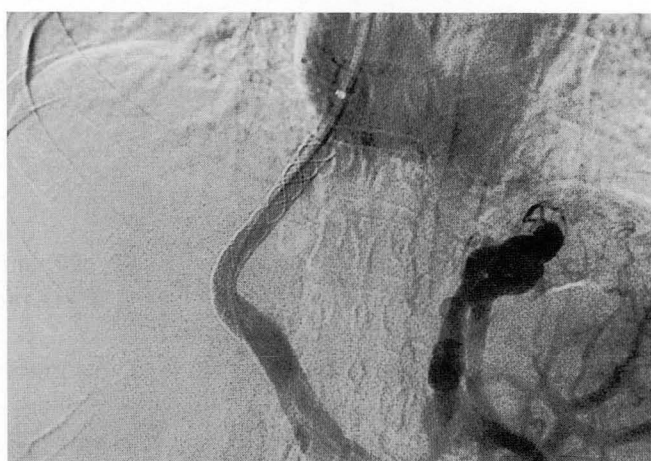A



B



C



D

**Fig. 1.** TIPS creation in a 41 year-old man with recurrent variceal bleeding.

**A.** A portal venogram obtained before dilatation of the parenchymal tract shows prominent gastroesophageal varices and no evidence of contrast extravasation despite of proximal location of the puncture site (arrow).

**B.** Contrast injection while withdrawing the 9F sheath (open arrows) reveals brisk contrast extravasation (curved arrow) and filling of contrast materials in the peritoneal spaces (arrows) confirming extrahepatic location of the portal entry site.

**C.** Portal venogram through a newly made tract reveals prominent gastroesophageal varices. Note the location of the portal entry site is more distal (arrow).

**D.** TIPS was created through the newly made safe tract which was confirmed by the same method as in (B). Post-procedure portogram shows good function of the shunt with decreased variceal flow and no evidence of extravasation.

ing parenchymal tract was followed by placement of a metallic stent. Wallstent (Schneider, Minneapolis, Minn.), 10 mm in diameter and 86-102 mm long, was used in all cases. To evaluate shunt function and to rule out possible extravasation from the tested site of the portal vein, a post-procedural portogram was obtained (Fig. 1D). Ultrasonography was performed immediately and one week after the procedure. Clinical follow-up, while the patients were still in hospital, included the monitoring of blood pressure and pulse rate.

## Results

Contrast extravasation occurred in three of 130 (2.3 %) patients who underwent this procedure; the extrahepatic location of the punctured portal vein segment was confirmed. In all three, however, a preliminary splenic portal venogram obtained without dilatation of the resulting parenchymal tract revealed no contrast extravasation (Fig. 1A). The portal vein was therefore repunctured, in a more peripheral segment, and after testing the new tract using the method described above, a shunt was created.

In all three patients with extrahepatic portal vein puncture, the punctured portal vein segments were within 3 cm of the bifurcation of this vein. Puncture of a portal vein segment at this site occurred in 34 of 130 (26 %) patients; the location of three of 34 punctured segments (8.8 %) was therefore extrahepatic.

Postprocedural portography revealed no bleeding through the tested extrahepatic portal vein segments. In all 130 patients, including three with initial extrahepatic portal vein puncture, neither clinically significant nor ultrasonographically detectable intraperitoneal bleeding occurred.

## Discussion

It is generally accepted that the morbidity and mortality rate of TIPS is lower than in other surgical shunting procedures (1-4). Despite the relatively low invasiveness of TIPS, serious complications may, however, still occur (1). The direct TIPS-related procedural mortality rate is less than 2 %, a common cause of death being intraperitoneal hemorrhage as a result of rupture of the extrahepatic portal vein (1). The use of a porous mesh stent to create a TIPS that extends into a portal vein segment not enveloped by liver parenchyma can result in potentially lethal free intra-abdominal bleeding. The right and left main portal vein segments, traditionally considered to be intrahepatic structures, are

often located outside the liver (5, 6). In a study of 31 cadaver livers, Schultz et al reported that portal vein bifurcations were extrahepatically located in 48 % of cases and at the liver capsule in 25 %. The maximum lengths of exposed extrahepatic right and left portal veins were 3.0 cm and 2.5 cm, respectively (5). Uflacker et al found that portal bifurcations occurred in an extrahepatic location in 40 % of 25 noncirrhotic cadaver livers (6), though in shrunken cirrhotic livers, these percentages may increase. These findings suggest that for TIPS placement, a portal vein puncture site more than 3 cm distal from the portal bifurcation will in most cases be safe. In difficult cases, however, a more central pass of the transjugular needle may provide successful portal access. If the punctured proximal portal veins are located intracapsularly, their larger diameter and favorable angle to the hepatic vein are beneficial for effective portal decompression. When the punctured portal vein segment is less than 3 cm from the portal bifurcation, it is difficult to decide whether or not to use the shunt tract for TIPS. There has been no way of defining the relationship between the portal vein and the liver capsule before balloon dilatation of the parenchymal tract. As in our two cases, portograms obtained without dilatation of the parenchymal tracts (Fig. 1A) do not show contrast extravasation, despite the extrahepatic location of punctured portal vein segments. When extravasation is found after balloon dilatation of the parenchymal tract or stent placement, reliable treatment has not been possible. David et al (7) reported two cases of this condition in which management involved the placement of two metallic stents in overlapping fashion to seal the extravasating sites and to lower portal vein pressure. The optimal solution would be placement of an impermeable stent across the site of extravasation, but at present, there are no commercially available TIPS stent-grafts.

To exclude the possibility of extravasation when the tract is dilated with a balloon, we advanced a 9F side-arm sheath into the portal vein from the hepatic vein. Contrast material was then injected with a syringe attached to the side-arm of the sheath as this was slowly withdrawn from the portal to the hepatic vein. Using this procedure, a 9F sheath only temporarily dilates the puncture site while the sheath is withdrawn; as confirmed by the portogram obtained after creating TIPS through a different tract, this small amount of dilatation does not cause permanent dilatation of the parenchymal tracts. This simple method of evaluating the parenchymal tract may be extremely useful for confirmation of whether the punctured portal vein segments are intra- or extrahepatic in location. This

may save time in difficult cases and prevent fatal intraperitoneal bleeding. In conclusion, it may be stated that for preventing intraperitoneal hemorrhage during transjugular intrahepatic portosystemic shunt creation, our method is effective and feasible.

### References

1. Freedman AM, Sanyal AJ, Tisnado J, et al. Complications of transjugular intrahepatic portosystemic shunt: a comprehensive review. *RadioGraphics* 1993; 13: 1185-1210
2. LaBerge JM, Ring EJ, Gordon RL, et al. Creation of the transjugular intrahepatic portosystemic shunts with the Wallstent endoprosthesis: results in 100 patients. *Radiology* 1993; 187: 413-420
3. Noeldge G, Richter GM, Roessle M, et al. Morphologic and clinical results of the transjugular intrahepatic portosystemic stent-shunt(TIPS). *Cardiovasc Intervent Radiol* 1992; 15: 342-348
4. Richter GM, Noeldge G, Palmaz JC, et al. Transjugular intrahepatic portocaval stent shunt: preliminary clinical results. *Radiology* 1990; 174: 1027-1030
5. Schultz SR, LaBerge JM, Gordon RL, Warren RS. Anatomy of the portal vein bifurcation: intra- versus extrahepatic location-implications for transjugular intrahepatic portosystemic shunts. *J Vasc Interv Radiol* 1994; 5: 457-459
6. Uflacker R, Richter P, D'Albuquerque LC, de Oliveira e Silva A. Liver anatomy applied to the placement of transjugular intrahepatic portosystemic shunts. *Radiology* 1994; 191: 705-712
7. Davis AG, Haskal ZJ. Extrahepatic portal vein puncture and intra-abdominal hemorrhage during transjugular intrahepatic portosystemic shunt creation. *J Vasc Interv Radiol* 1996; 7: 863-866

대한방사선의학회지 1998; 38: 635-638

## 경정맥간내문맥정맥단락술시 치명적인 복강내 출혈의 예방 방법<sup>1</sup>

<sup>1</sup> 경북대학교 의과대학 진단방사선과학교실

염 현 규 · 김 용 주

**목 적** : 경정맥간내문맥정맥단락술 (transjugular intrahepatic portosystemic shunt : TIPS) 시술시 천자된 문맥이 반드시 간 실질로 둘러싸여 있어야하나 지금까지 단락을 풍선확장 시키거나 스텐트를 설치하기 전에는 문맥과 피막과의 관계를 정확히 알 수가 없었다. 저자 등은 천자된 문맥과 간 피막과의 위치관계를 단락형성 전에 알아낼 수 있는 방법을 시도하고 그 유용성을 보고하고자 한다.

**대상 및 방법** : 본원에서 TIPS를 시술 받은 130명의 환자를 대상으로 하였으며 TIPS 교정 시술의 경우는 제외하였다. 전 예에서 일단 문맥이 천자 되면 먼저 안내철사를 문맥으로 넣은 다음 9F sheath를 간정맥으로부터 천자된 문맥으로 dilater와 함께 진입시킨 후 dilater를 빼고 sheath를 간정맥 쪽으로 서서히 후퇴시키는 동안 sheath를 통해 조영제를 주입하였다. 이 과정에서 조영제의 복강내 유출이 있는 경우에는 천자된 문맥이 간 피막밖에 위치하는 것으로 확인하고 새로운 문맥 부위를 천자 하여 TIPS를 시술하였다.

**결 과** : 130명의 환자 중 3명에서 (2.3%) 간 외 문맥의 천자가 확인되었으며, 이들의 경우 전 예에서 좀더 원위부의 문맥을 천자 하여 TIPS를 시술할 수 있었다. 전 예에서 시술 후 문맥조영술과 임상 추적조사에서 복강내 출혈의 합병증이 없었다.

**결 론** : TIPS 시술시 2.3%에서 간 외 문맥 천자가 있었으며, 저자들이 경험한 천자 위치 확인 방법은 단락의 풍선확장 또는 스텐트 삽입 전에 천자 부위와 간 피막과의 위치 관계를 정확히 알 수 있어 치명적인 복강내 출혈의 합병증을 예방할 수 있는 유용한 방법이라고 생각된다.